



The long term renal and bladder function outcomes of patients with posterior urethral valve

Nilüfer Bıçakçı^a, Berat Dilek Demirel^{b*}, Ünal Bıçakçı^b, Oktay Yapıcı^c

^a Department of Nuclear Medicine, SBU Education and Research Hospital, Samsun, Turkey

^b Department of Pediatric Surgery, Faculty of Medicine, Ondokuz Mayıs University, Samsun, Turkey

^c Department of Nuclear Medicine, Faculty of Medicine, Ondokuz Mayıs University, Samsun, Turkey

ARTICLE INFO

ABSTRACT

Article History

Received 07 / 01 / 2020
Accepted 09 / 02 / 2020
Online Published 23 / 03 / 2020

* Correspondence to:

Berat Dilek Demirel
Department of Pediatric Surgery,
Faculty of Medicine,
Ondokuz Mayıs University,
Samsun, Turkey
e-mail: bdayhan@hotmail.com

Keywords:

Bladder disfunction
Posterior urethral valve
Renal function
Valve bladder

We aimed to evaluate the preoperative and postoperative renal and bladder functions of patients operated for posterior urethral valve (PUV). Thirty five patients operated for PUV between 2006 and 2016 (mean 94 days, range 4 days-12 years). Seven patients had prenatal diagnosis. Preoperative and postoperative serum creatinine, Dimercaptosuccinic acid (DMSA), Voiding cystourethrography (VCUG), recurrent urinary tract infection, additional surgical procedures and urodynamic study results were evaluated. No vesicoureteral reflux (VUR) was demonstrated in four patients. No VCUG is obtained in two patients. Most of the bilateral VUR cases were grade IV or more. Thirteen patients had significant neuropathic bladder findings on VCUG and 21 had dilatation of posterior urethra. There were no preoperative DMSA scintigraphy in nine patients. Twenty two patients had a history of recurrent urinary tract infection. Nine of them had high grade reflux and seven of them had worsening of DMSA function with scars at postoperative follow-up. Preoperative/postoperative creatinine levels were 0.94mg/dL (0.14-4.63) / 0.39 mg/dL (0.11-2.3) respectively. Five patients are on CIC (3 had Mitrofanoff conduit). Two patients underwent augmentation+Mitrofanoff and one patient had Mitrofanoff procedures. One underwent bilateral ureterostomy and one unilateral ureterostomy (undiversion at five years). Three received percutaneous vesicostomy procedure and one diverged to permanent vesicostomy. Seven has ESRD and two patients are on continuous peritoneal dialysis. Postoperative UTI encountered in 22. Forty-two sessions of subureteric injection (17 right, 14 left, 11 bilateral) were performed. Urodynamic study conducted in 27 patients; 14 diagnosed as neuropathic bladder and 9 had DSD. Low bladder capacity and compliance was encountered in 17. Posterior urethral valve is the most important infravesical urinary obstruction that causes deterioration of renal function and permanent damage in boys in terms of long-term outcomes. Life long follow-up is obligate to protect from renal failure.

© 2020 OMU

1. Introduction

Posterior urethral valve (PUV) is the most common cause of lower urinary tract obstruction (LUTO) in male children. PUV has a broad clinical spectrum from mild to severe obstruction resulting in variable dysfunction of urinary tract such as renal dysplasia,

urinary incontinence, neuropathic bladder etc. (Hennus et al., 2012; Long et al., 2018). End stage renal disease (ESRD) is inevitable in 25-50% of cases despite early intervention (Holmdahl et al., 2005; Heikkila et al., 2011; Jonksisz et al., 2017). This finding suggests that the deterioration of renal function has already

occured during intrauterine life (Smith-Harrison et al., 2015). Obstruction in urinary system leads to increased intravesical pressure and detrusor hypertrophy and may result in reflux nephropathy and renal dysfunction (Nasir et al., 2011; Bhadoo et al., 2014). The initial approach is decompression of bladder via urethral catheterization and endoscopic valve ablation is the gold standart surgical treatment modality. In some cases, temporary vesicostomy may be preferred depending on the condition of the patient (Krahn et al., 1993).

In this study, we retrospectively evaluated preoperative and postoperative creatinin levels, renal functions (dimercaptosuccinic acid (DMSA) results), vesicoureteral reflux, recurrent urinary tract infections, additional surgical interventions and urodynamic study results.

2. Materials and methods

We performed retrospective analysis of patients presenting with PUV diagnosis from 2008 to 2016. All patient underwent endoscopic PUV incision. Patients excluded from study whose cystoscopic evaluation were normal. Thirty five patients operated (mean 94 days, range 4 days-12 years). All of them was type I PUV. Seven patients had a prenatal diagnosis. Preoperative and postoperative DMSA, voiding cystourethrography (VCUG), creatinine and history of urinary tract infection (UTI) and additional surgical procedures were evaluated.

3. Results

Seven patients had been diagnosed by standard prenatal ultrasound examination with dilated bladder and posterior urethra (key hole sign) (Fig. 1). Prenatal USG also revealed various degree of upper urinary dilatation and oligohydraminos. Vesicoureteral reflux (VUR) was not demonstrated with VCUG in four patients. Other patients have various degrees and laterality of VUR (Fig. 2). Bilateral cases tended to have high grade reflux (grade IV or more). Thirteen patients had neuropathic bladder findings on VCUG; irregular bladder wall

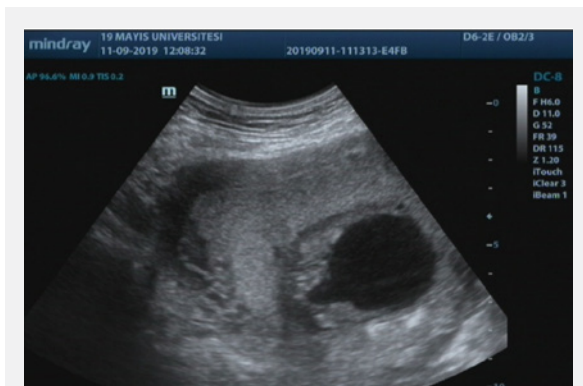

Fig. 1. Prenatal USG with dilated posterior urethra (Key hole sign).

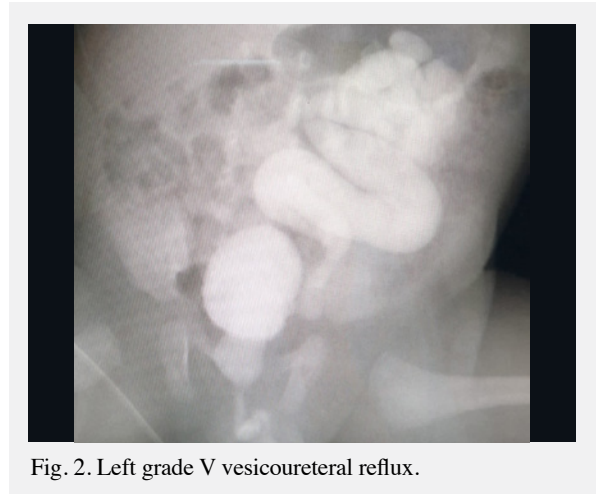

Fig. 2. Left grade V vesicoureteral reflux.

(trabeculation), loss of normal shape of bladder etc. Twenty one had posterior urethral dilatation namely key hole sign on US (Fig. 3).

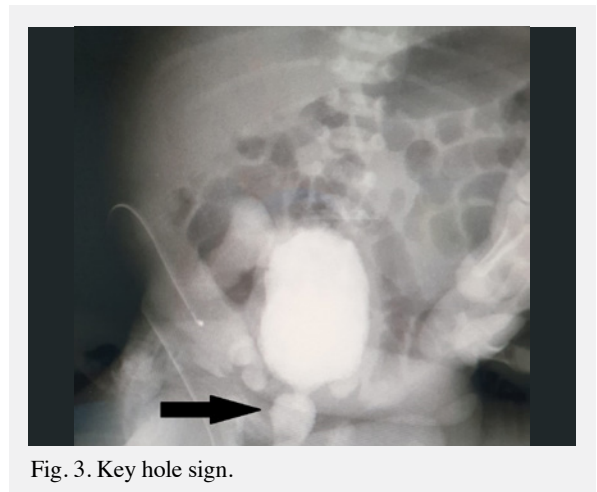


Fig. 3. Key hole sign.

Preoperative mean creatinine levels were 0.94 mg/dL (0.14-6.63) and postoperative mean creatinine levels were 0.39 mg/dL (0.11-2.3). Creatinine levels decreased under 1 mg/dL in 23 patients and decreased to 1-1.3 mg/dL in 10 patients in two days after valve ablation. Eight of them tend to drop below 1 mg/dl over months.

Preoperative and postoperative vesicoureteral reflux numbers were showed at tables 1 and 2. VUR grades were variable but most of them tend to be high

Table 1. Preoperative VUR grade and side.

Preop. VUR	Right	Left
Grade V	11	14
Grade IV	2	4
Grade III	2	4
Grade I-II	7	2
No VUR	7	5
Bilateral VUR	13	13

grades (grade IV and V). In longterm follow-up, high degrees of VUR persisted and lower degrees tend to increase on follow up.

Table 2. Preoperative VUR grade and side.

Postop. VUR According to last VCUG	Right	Left
Grade V	13	12
Grade IV	5	4
Grade III	12	7
Grade I-II	8	7
No VUR	7	5
Bilateral VUR	8	8

Twenty two patients had a history of recurrent urinary tract infection. Nine of them had high grade reflux and seven of them had worsening of DMSA function with scars on postoperative follow-up. Nearly half of the patients had less than 40% DRF on preoperative DMSA scanning and renal hypo-dysplasia (Table 3). Number of patients with <10% renal function increased two fold on follow up (Table 4).

Table 3. Preoperative DMSA results.

Preop. DMSA	Right	Left
%40 >	13	9
%20-40	6	10
%10-20	4	5
%10<	3	2

Table 4. Postoperative DMSA results.

Postop. DMSA	Right	Left
%40 >	11	8
%20-40	9	12
%10-20	9	8
%10<	6	7

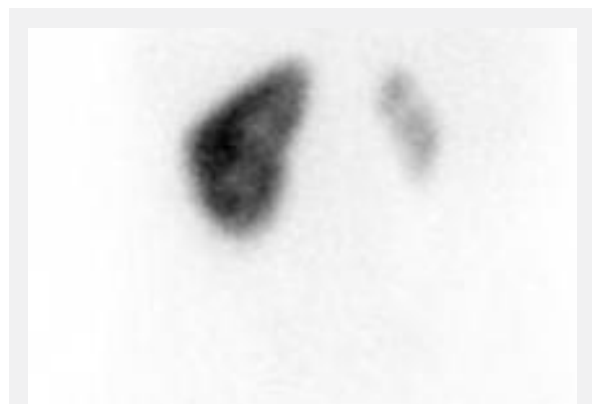

Fig. 4. Posterior view. Right renal hypoplasia.

Fig. 4. shows right renal function is 9% in a three month-old baby in his/her first DMSA scan. This hypoplasia may have occurred in the prenatal period because of high intravesical pressure with severe VUR. Left kidney may be preserved by 'pop-off' mechanism. Figs. 5 and 6 show that renal scarring has increased within the three years following valve ablation with recurrent UTI's.

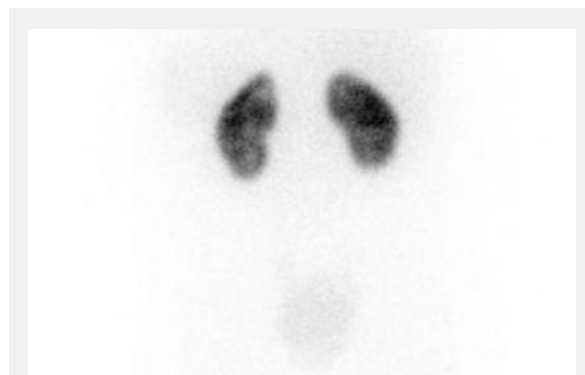

Fig. 5. Posterior view. Left renal scars alone.

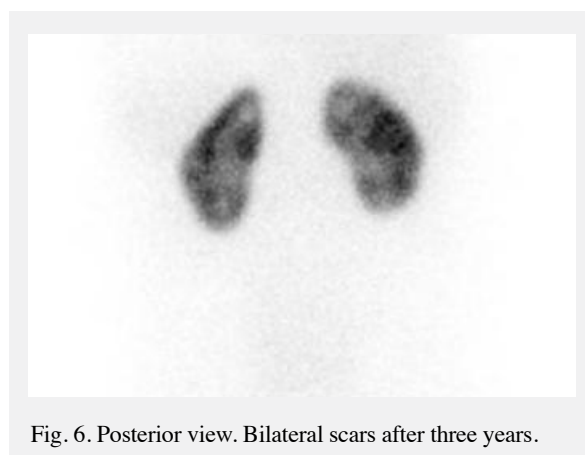


Fig. 6. Posterior view. Bilateral scars after three years.

Secondary surgical interventions

Six patients are on clear intermittent catheterization (CIC) (3 through Mitrofanoff conduit). Two received augmentation / Mitrofanoff and one Mitrofanoff procedures. One underwent bilateral ureterostomy. Unilateral ureterostomy was performed in one patient (undiversion at 5 year-old). Three percutaneous vesicostomy procedures were performed and one diverged to permanent vesicostomy. Seven has ESRD and two are on continous peritoneal dialysis.

Urodynamic study was conducted on 27 patients; 14 diagnosed as neuropathic bladder and nine had detrusor sphincter dyssynergy. Seventeen patients had low bladder capacity and compliance.

Thirty one sessions of subureteric injection (17 right, 14 left, 11 bilateral) were performed for various degrees of VUR. The success rates were higher for grade III or less degrees of VUR than neuropathic bladders. In five patients, VUR resolved totally (3 right,

1 left and 1 bilateral VUR). Six patients' VUR grade were decreased but not resolved (all grade III to V). Secondary injections were performed in seven patients and third injections were performed in two patients.

4. Discussion

Pathophysiological changes in the bladder and decreasing renal function in children with PUV seem to occur despite early diagnosis and valve ablation. Even after successful valve ablation, some degree of renal and bladder dysfunction will develop in most of the patients (Jonkisz et al., 2017). This morbidity is caused by occurrence of urinary obstruction at a critical time in organogenesis and may have enormous and lifelong effect on the function of kidney, ureter and bladder. The exact etiology is unknown (Borzi et al., 1992; Berte et al., 2018). Antenatal diagnosis depends on maternal ultrasound which shows that dilatation of bladder and posterior urethra (key hole sign), thickening bladder wall, upper urinary tract dilatation and oligohydramnios (Sweeney et al., 1981). After birth, urinary ultrasound, VCUG are performed for initial evaluation of PUV and renal scintigraphy is indicated for the evaluation of renal function and degree of renal impairment. On VCUG, the diagnosis of PUV depends on; thickened bladder wall, dilation of posterior urethra (key hole sign). Scintigraphic radionuclide studies are useful in estimation of the renal differential function (DRF), drainage and focal parenchymal defects (Gordon et al., 2003). Mercaptoacetyl triglycine (MAG3) or diethylethylaminepentaacetic acid (DTPA) are used as dynamic study. DMSA is used as static study. DMSA is more sensitive for DRF and parenchymal defects than other radionuclides and accepted as gold standard method for evaluating renal parenchymal scarring (Bingham et al., 1978; Farnsworth et al., 1991). Pereira et al. considered that presence of one or more renal scars on DMSA had poor prognosis when compared with normal DMSA (Pereira et al., 2003). Narasimhan et al. also said that patients with dilated ureters on ultrasound and poor drainage on DTPA are at highest risk of renal scarring (Narasimhan et al., 2006). These results are similar to our patient's group outcomes about renal scarring and end stage renal failure.

The surgical procedure of choice is endoscopic valve ablation. Valve is incised at 5,7 and 12 o'clock position (Bhatnagar et al., 2000; Joseph et al., 2000; Puri et al., 2002). In case of unavailable instrumentation, persisting or increased urinary tract dilation or high creatinine levels after incision some urinary diversion should be suggested. Diversion options are vesicostomy, ureterocutaneostomy, pyelostomy and nephrostomy (Krahn et al., 1993, Liard et al., 2000, Hosseini et al., 2015). The main problem is high bladder storage pressures in PUV patients. After ablation of valve, secondary bladder management should continue as medically (Abraham et al., 2009).

When necessary, secondary surgical procedures including bladder augmentation / Mitrofanoff (for urinary incontinence), subureteric material enjection (for VUR) or botox enjection (for reducing intravesical pressure) should be reserved in PUV patients during follow up. Severe recurrent urinary tract infection and pyelonephritis are common in patients with PUV. High bladder storage pressure, elevated post voiding residual urine volumes, stasis of urine and severe VUR are the main cause of UTI (Smith et al., 1996; Kim et al., 1997; Fine et al., 2011). Bladder drainage is essential to decrease storage pressures and residual urine to protect from severe pyelonephritis and renal scarring (Taskinen et al., 2012). Double voiding (for mild residual urine less than 50 ml), clean intermittent catheterization (CIC) or over night catheter drainage are options for urinary drainage (Koff et al., 2002; Holmdahl et al., 2003; Fumo et al., 2006). Existence of VUR is not associated with end stage renal disease but need for multiple surgeries for management of VUR. Unilateral VUR may act as 'pop-off' mechanism to decrease bladder storage pressure and having protective effect on renal function (Bilgutay et al., 2016).

Predicting long-term results of PUV patients is challenging. In severe cases, multiple surgical interventions may be necessary. In long-term follow-up and almost half of them may lose their renal functions and develop renal failure and are candidates of renal transplantation. On the other side, in mild cases, valve ablation may suffice and may have subtle symptoms and signs later in their lives (Kari et al., 2013).

Factors associated with renal scarring is not clear and many prognostic factors have been reported such as creatinine levels, nadir creatinine, beta-2 microglobulin level, fetal N-acetyl-beta-D-glucosaminidase (NAG) level, presence of bladder dysfunction, VUR (degree and laterality) with recurrent UTI and pyelonephritis (Thomas et al., 2007; Abdenadher et al., 2015; Lipitz et al., 2016; Spaggiari et al., 2017).

In our series, seven patients have ESRD (creatinine levels over 2 mg/dl) and four patients are suffering from renal failure. Fourteen patients have neuropathic bladder diagnosed by urodynamic studies. More than twenty patients have recurrent UTI or severe pyelonephritis with decreased renal function. Our results are similar to literature considering the long-term renal functional outcomes of PUV (Hennus et al., 2012; Tourchi et al., 2014; Jesus et al., 2015; Hebenstreit et al., 2018; Long et al., 2018; Canning, 2019). Six patients have performed clean intermittent catheterization with half of them have mitrofanoff conduit.

In conclusion, PUV is the most common infravesical urinary obstruction that causes deterioration of renal functions and permanent damage in boys. PUV ablation is not enough for preservation of renal and bladder functions. In most of the patients, life long follow-up is needed to protect from renal failure.

Conflict of interest

The author declares that there is no conflict of interest.

Acknowledgements

This work did not receive any specific grant from funding agencies in the public, commercial, or not-for-profit sectors.

REFERENCES

- Abdenanadher, W., Chalouhi, G., Dreux S., 2015. Fetal urine biochemistry at 13-23 weeks of gestation in lower urinary tract obstruction: Criteria for in-utero treatment. *Ultrasound Obstet. Gynecol.* 46, 306-311.
- Abraham, M.K., Nasir, A.R., Sudarsanan, B., Puzhankara, R., Kedari, P.M., Unnithan, G.R., 2009. Role of alpha adrenergic blocker in the management of posterior urethral valves. *Pediatr. Surg. Int.* 25, 1113-1115.
- Berte, N., Vrillon, I., Larmure, O., Gomola, V., Ayav, C., Mazeaud, C., Lemelle, J.L., 2018. Long-term renal outcome in infants with congenital lower urinary tract obstruction. *Prog. Urol.* 28, 596-602.
- Bhadoo, D., Bajpai, M., Panda, S.S., 2014. Posterior urethral valve: Prognostic factors and renal outcome. *J. Indian Assoc. Pediatr. Surg.* 19, 133-137.
- Bhatnagar, V., Agarwala, S., Lal, R., Mitra, D.K., 2000. Fulguration of posterior urethral valves using the Nd: YAG laser. *Pediatr. Surg. Int.* 16, 69-71.
- Bilgutay, A.N., Roth, D.R., Gonzales, E.T., Janse, N., Zhang, W., Koh, C.J., Gargollo, P., Seth, A., 2016. Posterior urethral valves: Risk factors for progression to renal failure. *J. Pediatr. Urol.* 12, 1791-1797.
- Bingham, J.B., Maisey, M.N., 1978. An evolution of the use of 99-Tc dimercaptosuccinic acid (DMSA) as a static renal imaging agent. *Br. J. Urol.* 51, 599-602.
- Borzi, P.A., Beasley, S.W., Fowler, R., 1992. Posterior urethral valves in non twin siblings. *Br. J. Urol.* 70, 201.
- Canning, D.A., 2019. Bladder contractility index in posterior urethral valves: A new marker early prediction of progression to renal failure. *J. Urol.* 201, 846.
- Farnsworth, R.H., Rossleigh, M.A., Leighton, D.M., Bass, S.J., Rosenberg, A.R., 1991. The detection of reflux nephropathy in infants by 99-Tc dimercaptosuccinic acid (DMSA) studies. *J. Urol.* 145, 542-546.
- Fine, M.S., Smith, K.M., Shrivastava, D., Cook, M.E., Shukla, A.R., 2011. Posterior urethral valve treatments and outcomes in children receiving kidney transplants. *J. Urol.* 185, 2507-2511.
- Fumo, M.J., Mclorie, G.A., 2006. Management of the valve-bladder syndrome and congenital bladder obstruction: The role of nocturnal bladder drainage. *Nat. Clin. Pract. Urol.* 3, 323-326.
- Gordon, I., Riccabona, M., 2003. Investigation the newborn kidney: Update on imaging techniques. *Semin. Neonatal.* 8, 269-278.
- Hebenstreit, D., Csaicich, D., Hebenstreit, K., Müller-Sacherer, T., Berlakovich, G., Springer, A., 2018. Long-term outcome of pediatric renal transplantation in boys with posterior urethral valves. *J. Urol.* 53, 2256-2260.
- Heikkila, J., Holmberg, C., Kyllonen, L., Rintala, R., Taskinen, S., 2011. Long-term risk of end stage renal disease in patients with posterior urethral valves. *J. Urol.* 186, 2392-2396.
- Hennus, P.M., Heijden, G.J.M., Bosch, J.L., Jong, T.P.V., Kort, L.M.O., 2012. A systematic review on renal and bladder dysfunction after endoscopic treatment of infravesical obstruction in boys. *Plos One.* 7, 1-8.
- Holmdahl, G., Sillen, U., Hellstrom, A.L., Sixt, R., 2003. Does treatment with clean intermittent catheterization in boys with posterior urethral valves affect bladder and renal function?. *J. Urol.* 170, 1681-1685.
- Holmdahl, G., Sillen, U., 2005. Boys with urethral valves: Outcome concerning renal function, bladder function and paternity at ages 31 to 44 years. *J. Urol.* 174, 1031-1034.
- Hosseini, S.M., Zarenezhad, M., Kamali, M., Gholamzadeh, S., Sabet, B., Alipour, F., 2015. Comparison of early neonatal valve ablation with vesicostomy in patient with posterior urethral valve. *Afr. J. Pediatr. Surg.* 12, 270-272.
- Jesus, L.E., Pippi, S., 2015. Pre-transplant management of valve bladder: A critical literature review. *J. Pediatr. Urol.* 11, 5-11.
- Jonkisz, D.P., Rehan, L.R., Fornalcyzk, K., Hackemer, P., Zwolinska, D., 2017. Valve bladder syndrome in children: On the trail of the best strategies to prevent chronic kidney disease. *Adv. Clin. Exp. Med.* 26, 1293-1300.
- Joseph, D.B., 2000. Editorial: Posterior urethral valve and the 11th commandment. *J. Urol.* 164, 149-150.
- Kari, J.A., Desoky, S., Farag, Y., Mosli, H., Altyieb, A., Sayad, A., Radawi, O., Ghabra, H., Basnawi, F., Bahrawi, O., 2013. Renal impairment in children with posterior urethral valves. *Pediatr. Nephrol.* 28, 927-31.
- Kim, Y.H., Horowitz, M., Combs, A.J., Nitti, V.W., Borer, J., Glassberg, K.I., 1997. Management of posterior urethral valves on the basis of urodynamic findings. *J. Urol.* 158, 1011-1016.
- Krahn, C.G., Johnson, H.W., 1993. Cutaneous vesicostomy in the young child: Indications and results. *Urology.* 41, 558-563.
- Koff, S.A., Mutabagani, K.H., Jayanti, V.R., 2002. The valve bladder syndrome: Pathophysiology and treatment with nocturnal bladder emptying. *J. Urol.* 167, 291-297.
- Liard, A., Segulier-Lipszyc, E., Mitrofanoff, P., 2000. Temporary high diversion for posterior urethral valves. *J. Urol.* 164, 145-148.
- Lipitz, S., Samuelli, C., 2016. Fetal urine analysis for the assesment of renal function in obstructive uropathy. *Am. J. Obstet. Gynecol.* 168, 174-179.
- Long, C.J., Bowen, D.K., 2018. Predicting and modifying risk for development of renal failure in boys with posterior urethral valves. *Current Urolog. Rep.* 19, 1-6.
- Narasimhan, K.L., Chowdhary, S.K., Kaur, B., Mittal, B.R., Bhattacharya, A., 2006. Factors affecting renal scarring in posterior urethral valves. *J. Pediatr. Urol.* 2, 569-574.

- Nasir, A.A., Ameh, E.A., Abdur-Rahman, L.O., Adeniran, J.O., Abraham, M.K., 2011. Posterior urethral valve. *World J. Pediatr.* 7, 205-216.
- Pereira, L., Espinosa, L., Martinez, U.M.J., Lobato, R., Navarro, M., Jaureguizar, E., 2003. Posterior urethral valves: Prognostic factors. *BJU Int.* 91, 687-690.
- Puri, A., Grover, V.P., Agarwala, S., Mitra, D.K., Bhatnagar, V., 2002. Initial surgical treatment as determinant of bladder dysfunction in posterior urethral valves. *Pediatr. Surg. Int.* 18, 438-443.
- Smith, G.H., Canning, D.A., Schulman, S.L., 1996. The long-term outcome of posterior urethral valves treated with primary valve ablation and observation. *J. Urol.* 155, 1730-1734.
- Smith-Harrison, L.I., Hougren, H.Y., Timberlake, M.D., Corbett, S.T., 2015. Current applications of in utero intervention for lower urinary tract obstruction. *J. Pediatr. Urol.* 11, 341-347.
- Spaggiari, E., Faure, G., Dreux, S., Czerkiewicz, I., Strinemann, J.J., Guimmiot, F., Heidet, L., Favre, R., 2017. Sequential fetal serum Beta 2 microglobulin to predict postnatal renal function bilateral or lower urinary tract obstruction. *Ultrasound Obstet. Gynecol.* 49, 617-622.
- Sweeney, I., Kang, B.H., Lin, P., Giovannello, J., 1981. Posterior urethral obstruction caused by congenital posterior urethral valve: Prenatal and postnatal ultrasound diagnosis. *N. Y. State J. Med.* 81, 87-89.
- Taskinen, S., Heikkila, J., Rintala, R., 2012. Effects of posterior urethral valves on long-term bladder and sexual function. *Urology.* 9, 699-706.
- Thomas, D.F.M., 2007. Prenatally diagnosed urinary tract abnormalities: Long-term outcome. *Semin. Fetal Neonatal Med.* 13, 189-195.
- Tourchi, A., Kaibazadeh, A.M., Aryan, Z., Ebadi, M., 2014. The management of vesicoreteral reflux in the setting of posterior urethral valve with emphasis on bladder function and renal outcome. Single center cohort study. *Urology.* 83, 199-205.