



Case Report

J. Exp. Clin. Med., 2020; 37(1): 21-23
doi: 10.5835/jecm.omu.37.01.005



Peroneal palsy as a complication of developmental hip dysplasia surgery

Murat Topal^a, Ali Aydın^{b*}

^a Department of Orthopedics and Traumatology, Faculty of Medicine, Atatürk University, Erzurum, Turkey

^b Department of Orthopedics and Traumatology, Faculty of Medicine, Kastamonu University, Kastamonu, Turkey

ARTICLE INFO

ABSTRACT

Article History

Received 11 / 11 / 2019
Accepted 28 / 01 / 2020
Online Published 23 / 03 / 2020

*Correspondence to:

Ali Aydın
Department of Orthopedics and
Traumatology,
Faculty of Medicine,
Kastamonu University,
Kastamonu, Turkey
e-mail: aliaaydin@atauni.edu.tr

Keywords:

Complication
Hip dysplasia
Peroneal palsy
Surgery

Nerve injuries are rare complications of surgical management of developmental dysplasia of the hip (DDH). Over-stretching can cause injuries of femoral, sciatic and peroneal nerves. In this report, we present a 6-year-old girl with Tönnis type IV bilateral DDH whose postoperative period was complicated with foot drop due to the breakage of the spica cast. Open reduction and Pemberton pericapsular osteotomies, high femoral osteotomies for derotation and shortening had been performed on both hips of the patient. Patient had been kept in a spica cast for six weeks. At the 6th week follow up visit it was observed that spica cast was broken at the knee. When the cast was removed foot drop was noted on left foot. Electromyoneurography (EMNG) revealed total axonal degeneration of the peroneal nerve at the level of the fibular head. The conservative therapy for 18 months failed to result in any improvement in common peroneal nerve function. Therefore, peroneal nerve decompression, neurolysis and posterior tibial tendon transfer had been performed. At the 4th year follow up visit the patient had active dorsiflexion of the ankle, no need for AFO and the foot was plantigrade and painless. We presented this case report in order to inform the orthopedic surgeons performing DDH surgeries about a possible complication of the spica cast and to emphasize the necessity of good care of the spica cast.

© 2020 OMU

1. Introduction

Nerve injuries are rare complications of surgical management of developmental dysplasia of the hip (DDH). Femoral, sciatic and peroneal nerve injuries have been reported in the previous articles (Pemberton, 1965; Hellinger and Schmidt, 1982; Salter et al., 1984; Kessler et al., 2001; Lalonde et al., 2002; Serin et al., 2004; Pekmezci and Yazici, 2007). These injuries were most commonly caused by over-stretching of the nerves during reduction of the hip. A case of irreversible peroneal nerve injury which had been caused by intrapelvic hematoma have been reported

(Hellinger and Schmidt, 1982). Peroneal nerve lesions results in foot drop.

Peroneal nerve lesions are frequently caused by compression of the peroneal nerve or direct trauma to the peroneal nerve at the level of fibular head where it is superficial (Lippin et al., 1993; Waternberg et al., 2000). Dorsiflexion deficit of the foot results in foot drop which can also be caused by lumbar plexus lesions and lower lumbar radiculopathy.

In this case report we presented a case of peroneal nerve lesion and foot drop which was a complication of DDH surgery.

2. Case

Our case was a 6-year-old girl with Tönnis type 4 bilateral DDH. Patient did not have any concomitant pathology, history of trauma or familial disease. Open reduction and Pemberton pericapsular osteotomies for both of the hips, high femoral osteotomies for derotation and shortening had been performed on both femurs of the patient. No immediate intra-operative or postoperative complications had been noticed. At 6th week follow up visit, it was noted that the spica cast was broken at the left knee. Foot drop of the left foot had been noticed after the removal of the spica cast. There was extension deficit in all toes and extension and eversion deficits of the ankle. Sensory deficit was present at the anterolateral leg and at dorsal part of the foot and toes. Tinnel's test was positive at the level of the fibular head. Electromyoneurography (EMNG) revealed a total axonal degeneration of the peroneal nerve at the level of the fibular head. An ankle-foot orthotic (AFO) had been prescribed and patient had been treated with high dose cobalamine. During the three month follow up period no recovery had been noted and peroneal nerve decompression surgery was advised but the parents refused surgery. At 18th month follow up visit EMNG revealed no change in peroneal nerve function (Fig. 1A, B). Parents accepted the surgery at the 18th month. Peroneal nerve decompression at the level of the fibular head, neurolysis and posterior tibial tendon transfer had been performed (Fig. 2A, B, C). It was observed during the operation that the peroneal nerve was stuck and tenuous at the fibular neck. Long leg cast was applied and had been kept for 6 weeks; then a patellar tendon bearing cast was applied and patient was mobilized for the next 6 weeks. After the removal of the cast active dorsiflexion of the ankle was achieved but EMNG revealed no recovery of the peroneal nerve function. An AFO was prescribed for the following three months. At the postoperative 4th year follow up the patient had active dorsiflexion of the ankle and the foot was plantigrade and painless (Fig. 3A, B). Patient is still being followed up.

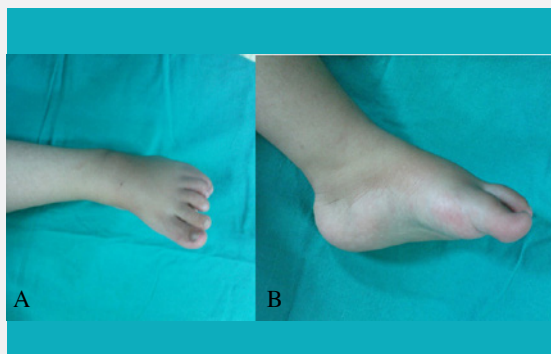


Fig. 1. A, B Preoperative photograph of foot, lack of dorsiflexion.

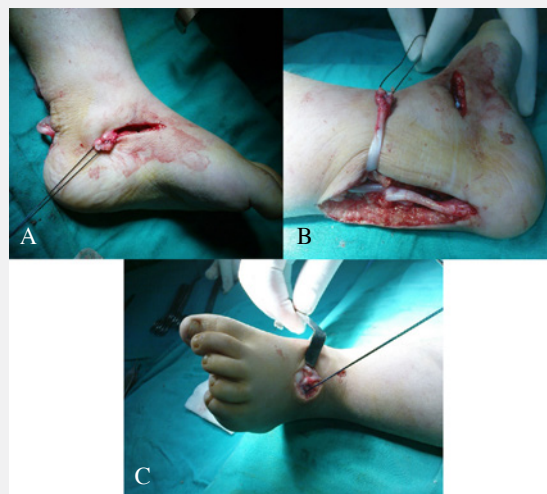

Fig. 2. A,B,C Transfer of the tibialis posterior tendon to the lateral cuneiform.

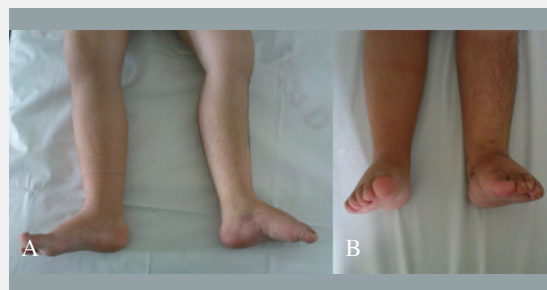


Fig. 3. A,B Post-operative 4th month photograph of plantigrade foot.

3. Discussion

Peroneal nerve arises from the trunk of the sciatic nerve in the popliteal fossa and passes over the lateral head of the gastrocnemius muscle. Peroneal nerve is just beneath the skin at the level of the fibular head and neck where it is susceptible to trauma (Lippin et al., 1993; Watemberg et al., 2000). Hypermobility of the fibular head results in continuous mechanical injury to the peroneal nerve (Mc Crory et al., 2002). Peroneal nerve has a small number of nerve fibers and a small amount of endoneurium and perineurium. These attributes along with its vulnerable location around the fibular head makes it susceptible to direct trauma and stretching (Lippin et al., 1993; Evans et al., 1994). Most common causes of peroneal nerve injury at the level of fibular head are iatrogenic trauma during surgical procedures, knee dislocations, casting, orthoses and penetrating injuries. Other causes are exostoses, hematomas, ganglion cysts, compression of the fracture calluses, tumors of the fibular head, lipomas and hemangiomas (Evans et al., 1994; Wilkinson and Birch, 1995; Toğrol et al., 2000; Tomaino et al., 2000; Garozzo et al., 2002; Pichler et al., 2009; Halm and Schepers, 2012).

Peroneal femoral and sciatic nerve injuries after surgical management of DDH had been reported previously (Pemberton, 1965; Hellinger and Schmidt, 1982; Salter et al., 1984; Pekmezci and Yazici, 2007). Forceful reduction may result in nerve injuries. Hellinger and Schmidt reported a case of peroneal nerve injury caused by intrapelvic hematoma after pericapsular osteotomy (Hellinger and Schmidt, 1982). We presented the case of a 6-year old girl with a peroneal nerve injury which was caused by compression of the peroneal nerve by the break of the spica cast at the left knee.

A three month of high dose cobalamin treatment and AFO use is suggested in treatment of the peroneal nerve palsy (Mc Crory et al., 2002). A posterior tibial tendon transfer is suggested in late diagnosed cases (Mont et al., 1996). Posterior tibial tendon transfer in cases with surgical nerve repair is reported to improve outcomes (Bekler et al., 2007). We treated our patient with high dose cobalamin and an AFO for the first three months and suggested peroneal nerve decompression surgery at the end of the third month. Parents refused the surgery so we had to keep treating the patient medically until the parents gave the permission for the surgery for a

total of 18 months which resulted in no improvement in peroneal nerve function. At the end we performed peroneal nerve decompression neurolysis and posterior tibial tendon transfer on the patient.

Orthopedic surgeons who perform DHD surgery can see peroneal nerve lesions as a complication of the surgical procedure. Bony prominences like the knee should be well padded during the application of the spica cast and the greatest care must be given to the spica cast. Posterior tibial tendon transfer is an effective procedure in treatment of foot drop due to long term peroneal nerve palsy.

Disclaimer: None to declare.

Funding Sources: This case report has no source of funding.

Conflict of Interest: This case report has no conflict of interest.

Ethical Approval: All procedures performed on the patient were in accordance to the ethical standards of the institution research committee.

Informed Consent: Written informed consent was obtained from the patient for publication of this case in the text.

REFERENCES

- Bekler, H., Beyzadeoğlu, T., Gökçe, A., 2007. Tibialis posterior tendon transfer for drop foot deformity. *Acta. Orthop. Traumatol. Turc.* 41, 387-392.
- Evans, J.D., Neumann, L., Frostick, S.P., 1994. Compression neuropathy of the common peroneal nerve caused by a ganglion. *Microsurgery.* 15, 193-195.
- Garozzo, D., Ferraresi, S., Buffatti, P., 2002. Common peroneal nerve injuries in knee dislocations: Results with one-stage nerve repair and tibialis posterior tendon transfer. *J. Orthop. Traumatol.* 2, 135-137.
- Halm, J. A. and Schepers, T., 2012. Damage to the superficial peroneal nerve in operative treatment of fibula fractures: Straight to the bone? Case report and review of the literature. *J. Foot Ankle Surg.* 51, 684-686.
- Hellinger, J. Schmidt, H., 1982. The pericapsular osteotomy of the os ilium in the treatment of flat acetabula. *Arch. Orthop. Trauma Surg.* 101, 53-57.
- Serin, E., Karakurt, L., Yilmaz, E., Incesu, M., Belhan, O., 2004. Early results of treatment for developmental dysplasia of the hip in children between the ages of one and four years. *AOTT.* 38, 8-15.
- Kessler, J.I., Stevens, P.M., Smith, J.T., Carroll, K.L., 2001. Use of allografts in Pemberton osteotomies. *J. Pediatr. Orthop.* 21, 468-473.
- Lalonde, F.D., Frick, S.L., Wenger, D.R., 2002. Surgical correction of residual hip dysplasia in two pediatric age-groups. *J. Bone Joint Surg. Am.* 84, 1148-1156.
- Lippin, Y., Shvoron, A., Yaffe, B., Zwas, S.T., Tsur, H., 1993. Postburn peroneal nerve palsy—a report of two consecutive cases. *Burns.* 19, 246-248.
- McCroory, P., Bell, S., Bradshaw, C., 2002. Nerve entrapments of the lower leg, ankle and foot in sport. *Sports Med.* 32, 371-391.
- Mont, M.A., Dellon, A.L., Chen, F., Hungerford, M.W., Krackow, K.A., Hungerford, D.S., 1996. The operative treatment of peroneal nerve palsy. *J. Bone Joint Surg. Am.* 78, 863-869.
- Pekmezci, M. and Yazici, M., 2007. Salter osteotomy: An overview. *Acta. Orthop. Traumatol. Turc.* 41, 37-46.
- Pemberton, P. A., 1965. Pericapsular osteotomy of the ilium for treatment of congenital subluxation and dislocation of the hip. *J. Bone Joint Surg. Am.* 47, 65-86.
- Pichler, W., Grechenig, W., Tesch, N.P., Weinberg, A.M., Heidari, N., Clement, H., 2009. The risk of iatrogenic injury to the deep peroneal nerve in minimally invasive osteosynthesis of the tibia with the less invasive stabilization system: A cadaver study. *J. Bone Joint Surg. Br.* 91, 385-387.
- Salter, R.B., Hansson, G., Thompson, G.H., 1984. Innominate osteotomy in the management of residual congenital subluxation of the hip in young adults. *Clin. Orthop. Relat. Res.* 182, 53-68.
- Toğrol, E., 2000. Bilateral peroneal nerve palsy induced by prolonged squatting. *Mil. Med.* 165, 240-242.
- Tomaino, M., Day, C., Papageorgiou, C., Harner, C., Fu, F.H., 2000. Peroneal nerve palsy following knee dislocation: Pathoanatomy and implications for treatment. *Knee Surg. Sports Traumatol. Arthrosc.* 8, 163-165.
- Waternberg, N., Amsel, S., Sadeh, M., Lerman-Sagie, T., 2000. Common peroneal neuropathy due to surfing. *J. Child. Neurol.* 15, 420-421.
- Wilkinson, M. C., Birch, R., 1995. Repair of the common peroneal nerve. *Bone Joint J.* 77, 501-503.