

RESEARCH  
ARTICLE

**Bahtiyar Muhammedoglu<sup>1</sup>**  
**Eyup Mehmet Pircanoglu<sup>2</sup>**  
**Serkan Torun<sup>3</sup>**

<sup>1</sup>Department of Gastrointestinal Surgeon, Necip Fazil City Hospital, Kahramanmaraş, Turkey

<sup>2</sup>Department of General Surgery, Necip Fazil City Hospital, Kahramanmaraş, Turkey

<sup>3</sup>Duzce University, Faculty of Medicine, Department of Gastroenterology, Turkey

**Corresponding Author:**

*Bahtiyar Muhammedoglu*  
*Department of Gastrointestinal Surgeon, Necip Fazil City Hospital, Kahramanmaraş, Turkey*  
*mail: baha197647@gmail.com*  
*Phone: +90 3442282800*

Received: 04.04.2020

Acceptance: 23.10.2020

DOI: 10.18521/ktd.714664

**Konuralp Medical Journal**  
e-ISSN1309-3878  
konuralptipdergi@duzce.edu.tr  
konuralptipdergisi@gmail.com  
www.konuralptipdergi.duzce.edu.tr

## Choledocholithiasis without Cholecystolithiasis, After Endoscopic Retrograde Cholangiopancreatography Follow-Up without Cholecystectomy

**ABSTRACT**

**Objective:** The widespread use of imaging methods increases the diagnosis and incidence of cholelithiasis. In recent years, management of patients with cholelithiasis has improved significantly owing to significant advances in surgical and endoscopic intervention.

**Methods:** Between February 2015 and January 2018, the data of patients who underwent ERCP at our institution were collected prospectively and analyzed retrospectively. Forty-four patients included in the study were patients with choledocholithiasis without stones in the GB.

**Results:** The mean age of 52 subjects (group A) included in the study was  $64.83 \pm 17.06$ , of which 23 (44.2%) were <65 years old and 29 (55.8%) were  $\geq 65$  years old. Twenty-four (46.2%) women and twenty-eight (53.8%) men were included in the study. Malignancy was suspected in 6 (11.5%) patients and no suspicion of malignancy was confirmed after Endoscopic Retrograde Cholangio-Pancreatography (ERCP) procedure. In group A, 14 patients (26.9%) required a second ERCP, while in group B, the number of patients requiring a second ERCP was 163 (21.3%). The mean length of hospital stay in group A and group B patients was  $5.29 \pm 3.38$  and  $6.29 \pm 5.39$ , respectively, and the average cost was  $474 \$ \pm 286 \$$  and  $564 \$ \pm 664 \$$ , respectively, with no statistical difference between the groups.

**Conclusions:** In conclusion, we think that in patients with secondary or primary choledochal stones without gallstones and with functional GB might be following up without cholecystectomy after the stone is removed from the bile duct by ERCP.

**Keywords:** Gallbladder, Laparoscopic Cholecystectomy, Endoscopic Retrograde Cholangiopancreatography

## Kolelitiazis Olmadan Gelişen Koledokolitiazis Hastalarının Endoskopik Retrograd Kolanjiopankreatografi Sonrası Kolesistektomisiz Takibi

**ÖZET**

**Amaç:** Görüntüleme yöntemlerinin yaygın kullanımı kolelitiazis tanı ve insidansını artırmaktadır. Son yıllarda, kolelitiazisli hastaların tedavisi, cerrahi ve endoskopik müdahaledeki gelişmeler nedeniyle önemli ölçüde iyileşmiştir.

**Gereç ve Yöntem:** Şubat 2015 - Ocak 2018 tarihleri arasında kurumumuzda ERCP uygulanan hastaların verileri prospektif olarak toplandı ve geriye dönük olarak analiz edildi. Çalışmaya dahil edilen kırk dört hasta, Safra kese'de (SK) taşsız koledokolitiazis hastalarıdır.

**Bulgular:** Çalışmaya dahil edilen 52 kişinin (grup A) ortalama yaşı  $64,83 \pm 17,06$  idi, bunların 23'ü (% 44,2) <65 yaşında ve 29'u (% 55,8)  $\geq 65$  yaşında idi. Çalışmaya 24 (% 46,2) kadın ve yirmi sekiz (% 53,8) erkek dahil edildi. 6 (% 11,5) hastada malignite şüphesi vardı ve Endoskopik Retrograd Kolanjiyo-Pankreatografi (ERCP) prosedürü sonrasında malignite şüphesi doğrulanmadı. Grup A'da 14 hasta (% 26,9) ikinci bir ERCP'ye ihtiyaç duyarken, grup B'de ikinci bir ERCP gerektiren hasta sayısı 163 (% 21,3) idi. Grup A ve grup B hastalarında ortalama hastanede kalış süresi sırasıyla  $5,29 \pm 3,38$  ve  $6,29 \pm 5,39$ , ortalama maliyet sırasıyla  $474 \$ \pm 286 \$$  ve  $564 \$ \pm 664 \$$  idi ve gruplar arasında istatistiksel fark yoktu.

**Sonuç:** Sonuç olarak, safra taşı olmayan sekonder veya birincil koledok taşı olan hastalarda fonksiyonel SK olan hastalarda taş ERCP ile safra kanalından çıkarıldıktan sonra kolesistektomi yapılmadan takip edilebileceğini düşünüyoruz.

**Anahtar Kelimeler:** Safra Kesesi, Laparoskopik Kolesistektomi, Endoskopik Retrograd Kolanjiopankreatografi

## INTRODUCTION

The widespread use of imaging methods increases the diagnosis and incidence of cholelithiasis. In recent years, management of patients with cholelithiasis has improved significantly owing to significant advances in surgical and endoscopic intervention. In contrast, there are some questions that require answers in the management of this common disease. Choledocholithiasis occurs in approximately 20% of patients with cholelithiasis (1). Most stones are formed in the gallbladder (GB) and then migrate to the common bile duct, causing biliary obstruction. Primary choledocholithiasis refers to stones directly formed in the bile tree whereas secondary choledocholithiasis refers to stones originating from the GB and migrating to the common bile duct (2). It is estimated that 20% of patients with cholelithiasis have choledocholithiasis and half of the cases are asymptomatic. Biliary colic precedes complications in 90% of cases. The natural course of choledocholithiasis is unpredictable and not well defined. Untreated bile duct stone obstruction usually causes secondary biliary cirrhosis after about 5 years (4). The aim of this study is to investigate whether cholelithiasis or recurrent choledocholithiasis develops during routine follow-up of patients who underwent Endoscopic Retrograde Cholangio-Pancreatography (ERCP) for choledocholithiasis without gallstones. At the same time, the aim is also to contribute to the management of cholelithiasis and choledocholithiasis with short and long term follow-up results of our study by accepting that cases in our study are primary or secondary choledocholithiasis.

### Choledocholithiasis without cholelithiasis

Nowadays, it is obvious that the gold standard in the treatment of cholelithiasis is Laparoscopic Cholecystectomy (LC). On the other hand, in the literature, Gallbladder-sparing surgery (GSS) has been started to apply in GB stones. In their study of 65 patients with the diagnosis of cholelithiasis, Tan Y et al. performed minimally invasive surgery with GB preservation; and for 61 of them, GB was perfectly preserved without complication. In the other four cases, laparoscopic cholecystectomy was performed because of tiny stones obstructing the cystic duct. According to this study, it has been shown that GB can maintain its function and can effectively avoid various complications of cholecystectomy. They also reported that gall bladder function was not affected during the follow-up of patients and the rate of stone recurrence was very low (5). In that study, they didn't mention the patients with acalculous cholecystitis, existed due to trauma, burn, cardiopulmonary resuscitation and staying in intensive care unit. In our study, cases of acalculous cholecystitis were excluded, and we presented the patients who were admitted to our clinic without

gallstone and with jaundice or cholangitis due to choledocholithiasis. Also in our study, we investigated whether short and long-term follow-up results may be a source of light for some new ideas after ERCP procedure applied to patients with choledochal stones without gallstones. It was also quite difficult to prove whether the common bile duct stones were primary or secondary in our study. However, secondary choledocholithiasis may be considered if there is a ultrasonography (USG)-proven stone before the diagnosis of choledocholithiasis. On the other hand, there is another possibility that there was only one stone in the GB and then this stone migrated to the common bile duct. In our study, none of the patients had a diagnosis of cholelithiasis in their USG, applied before ERCP. The colors of biliary stones are also important to assess whether the common bile duct stones are primary or secondary. Epidemiologically, primary and secondary bile duct stones are highly variable. In Western societies, most bile duct stones are secondary and prevalence increases with age. Primary bile duct stones are more common in Asia. Primary stones are associated with bacterial contamination of common bile duct due to biliary enteric anastomoses, sphincterotomy, stents, instrumentation and portal bacteremia. Periapillary diverticula provide a suitable site for bacterial proliferation because of subsequent backflow to the bile duct (6). Cholesterol is the main component in about 80% of GB stones, and 10% of these stones are made up of pure cholesterol. Pigment stones, by definition, contain less than 25% cholesterol and the main component is calcium bilirubinate (7). In the presence of stones in the common bile duct, even if there is no stone in the GB, this is an indication for ERCP. Diagnosis of choledocholithiasis is not always easy and clinical evaluation and biochemical tests are often not sufficient to make a definitive diagnosis. Several methods are available to evaluate patients with choledocholithiasis, including laboratory tests, ultrasound, computed tomography scans (CT), and magnetic resonance cholangiopancreatography (MRCP) (8). Imaging tests, especially abdominal ultrasound, are routinely used to confirm the diagnosis. Ultrasound has the best sensitivity and specificity to evaluate patients with suspected GB stones (9). Liver function tests (LFT) can be used to estimate common bile duct stones. Elevated serum bilirubin level and alkaline phosphatase level typically show biliary obstruction; however, they are not very sensitive or specific for common bile duct stones. Elevated GGT level has been suggested to be the most sensitive and specific indicator for choledocholithiasis. In this study, we summarized the literature and discussed the factors that determine the appropriate treatment method. In the literature, the number of studies about GSS has

increased and interest for this topic has been rising. In our study, patients were followed up without cholecystectomy after common bile duct stone removal. Therefore, our study also addresses GSS, a new trend in the current literature. However, it has been accepted that the treatment of cholecystolithiasis is surgical and LC is the gold standard. Our aim in this article is to evaluate the treatment results of patients with choledocholithiasis without cholecystolithiasis and to review the current literature and make recommendations for such patients' management.

**MATERIAL AND METHODS**

Between February 2015 and January 2018, the data of patients who underwent ERCP at our institution were collected prospectively and analyzed retrospectively. Forty-four patients included in the study were patients with choledocholithiasis without stones in the GB. Transabdominal USG was used to determine the absence of stones in the GB of these patients. All patients planned to undergo ERCP (Figure 1) were diagnosed as choledocholithiasis by MRCP. In patients with acalculous cholecystitis (intensive care unit patients, burn patients) and with cholecystectomy, stones that were formed in the first two years (secondary bile duct stones) and stones formed after 2 years (primary bile duct stones) were not included in this study. Patients with choledocholithiasis without cholelithiasis were identified as "group A" and patients who underwent ERCP for other reasons were identified as "group B". Demographic findings, length of hospital stay, cost, and LFT findings were evaluated among the groups. In the short and long-term follow-up after ERCP in group A, patients were evaluated whether there was a stone formation in GB and there was an acute cholecystitis attack, by using USG.

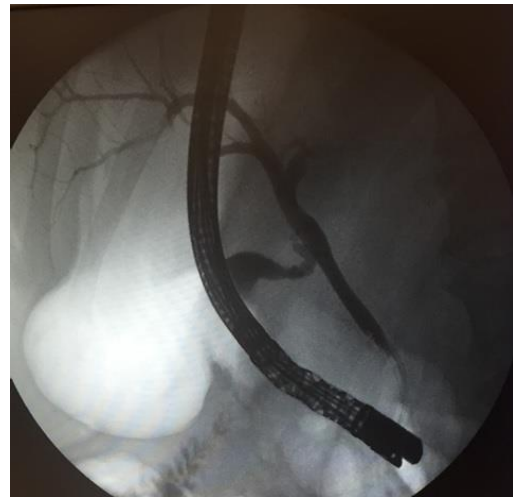
Written informed consent for the procedure and use of data was obtained from each patient in accordance with the Declaration of Helsinki. This study was approved by the institutional review board in the institution.

**Table 1.** Demographic findings and procedures

	Stone-free gall bladder and ERCP			
		Yes (n=52) Choledocholithiasis without cholelithiasis	No (n=760) Choledocholithiasis with cholelithiasis (and other cause for ERCP)	P
Age	<65	23 (44,2)	399 (52,5)	0.248
	>=65	29 (55,8)	361 (47,5)	
Gender	M	28 (53,8)	345 (45,2)	0.224
	F	24 (46,2)	419 (54,8)	
Suspected Malignancy	Yes	6 (11,5)	26 (3,4)	0.003
Bile Leakage	Yes	1 (1,9)	8 (1)	0.558
2. Ercp Needs	Yes	14 (26,9)	163 (21,3)	0.344
Status	PD	52 (100)	760 (99,5)	0.601
Stent Insertion	Yes	9 (17,3)	155 (20,3)	0.604
Sphincterotomy	Yes	49 (94,2)	719 (94,1)	0.971
Sclerotherapy	Yes	1 (1,9)	18 (2,4)	0.841

\*Significant at 0.05 level. Chi-square test.

ERCP, Endoscopic Retrograde Cholangiopancreatography. PD, Patient discharged(PD)



**Figure 1.** Bile ducts and gallbladder were visualized on cholangiography.

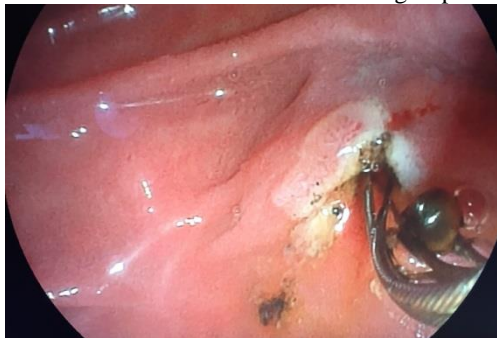**Statistical Analysis:** The normality of distribution of continuous variables was tested by Shapiro Wilk test. Mann Whitney u test was used to compare 2 independent group for non-normal data and Kruskal Wallis and Dunn multiple comparison test were applied for three group comparisons.

Chi-square test was applied to investigate relationship between 2 categorical variables. Statistical analysis was performed with SPSS for Windows version 24.0 and a P value < 0.05 was accepted as statistically significant.

**RESULTS**

The mean age of 52 subjects (group A) included in the study was 64.83 ± 17.06, of which 23 (44.2%) were <65 years old and 29 (55.8%) were ≥65 years old. Twenty-four (46.2%) women and twenty-eight (53.8%) men were included in the study. Malignancy was suspected in 6 (11.5%) patients and no suspicion of malignancy was confirmed after ERCP procedure. In group A, 14 patients (26.9%) required a second ERCP, while in group B, the number of patients requiring a second ERCP was 163 (21.3%) (Table1).

Difficult ERCP was due to the difficulty of selective cannulation of choledochus. Precut sphincterotomy was performed in these patients and the procedure was performed successfully in the second ERCP (Figure 2). The mean length of hospital stay in group A and group B patients was  $5.29 \pm 3.38$  and  $6.29 \pm 5.39$ , respectively, and the average cost was  $474 \$ \pm 286 \$$  and  $564 \$ \pm 664 \$$ , respectively, with no statistical difference between the groups.



**Figure 2.** Choledochal stone was removed after endoscopic sphincterotomy

The presence of suspicion of malignancy was significantly higher in patients with stone-free gallbladder, who had undergone ERCP ( $P = 0.003$ ). The mean age was significantly higher in group A patients than group B ( $P = 0.001$ ). In addition, liver function tests were significantly lower in group A, while WBC was higher (Table 2). Long-term results were followed up but 10 patients could not be reached, and two elderly patients died due to another cause. One patient underwent ERCP 12 months later due to recurrent stone formation in the common bile duct. In two patients, biliary sludge was detected in gallbladder on control abdomen USG, and after medical treatment and diet, there was no sludge in gallbladder. Laparoscopic cholecystectomy was performed in two patients because of gallbladder stone formation, and in two patients because of acute cholecystitis which developed in early period. In the routine outpatient clinic visits of the remaining 34 patients (4-18 months of follow-up), no stones were detected in the gallbladder and routine outpatient control was recommended as the patients had no complaints.

**Table 2.** Hospitalization, cost and liver function tests

Variables	Stone-free gall bladder and ERCP		P
	Yes (n=52) Choledocholithiasis without cholelithiasis	No (n=760) Choledocholithiasis with cholelithiasis (and other cause for ERCP)	
Age	64.83 ± 17.06	61.45 ± 19.03	0.001*
Hospital Stay	5.29 ± 3.38	6.29 ± 5.39	0.936
Cost	2008.78 ± 1213,13	2389.05 ± 2812,26	0.779
ERCP Number	1.17 ± 0.38	1.18 ± 0.53	0.078
MN White blood cells	6.42 ± 2.51	6.42 ± 2.34	0.002*
MX White blood cells	12.5 ± 9.88	12.25 ± 7.09	0.484
MN GGT	192.55 ± 165,46	197.53 ± 201,22	0.005*
MXGGT	310.29 ± 232,79	369.89 ± 338,36	0.020*
MN Total bilirubin	0.74 ± 0,9	0.88 ± 1.57	0.091
MX Total bilirubin	3.25 ± 3.41	3.41 ± 3.69	0.153
MN ALT	56.27 ± 59.77	62.79 ± 69.95	0.001*
MX ALT	199.63 ± 267,78	210.03 ± 240,31	0.010*
MN AST	35.85 ± 19.88	41.21 ± 42.96	0.031*
MX AST	202.69 ± 322,35	189.85 ± 226,59	0.150
MN Amylase	76.23 ± 118,28	62.2 ± 79.79	0.354
MX Amylase	351.08 ± 493,26	488.49 ± 691,77	0.502

\*Significant at 0.05 level. Mann whitney u test.

MN, The minimum value during hospitalization. MX, The maximum value during hospitalization. GGT, Gamma-glutamyl transferase. ALT, Alanine aminotransferase. AST Aspartate aminotransferase. ERCP, Endoscopic Retrograde Cholangiopancreatography.

**DISCUSSION**

The presence of stones in the bile duct without stones in the GB requires the primary or secondary distinction of these stones. The actual numbers of such patients are unknown and there are not enough publications in the literature. It is difficult to

determine the primary or secondary distinction of stone in patients with choledocholithiasis without cholelithiasis, but it is partially possible with some methods. As weak evidence, it is possible to have an idea about distinction via looking for presence of

stones in the GB in USG of the patient in the last 3 months, and via evaluating the visual color and composition of gallstones in private laboratories. In our study, all patients were evaluated by transabdominal ultrasonography before ERCP and it was shown that there were no stones in the GB.

USG is very sensitive in determining the presence of stones in the GB. In the presence of gallstones, visualization of GB wall thickening using ultrasound has a positive predictive value of 95% for the diagnosis of acute cholecystitis (10). Another opinion questions whether the results are related to the experience of radiologists. In a prospective study conducted by Grancharov et al, it was found that correct primary diagnosing of uncomplicated gallstones via using ultrasound by experienced and novice radiologists were found to be similar. Based on this, they reported that their level of expertise was good (11).

Endoscopic ultrasonography (EUS) is considered to be a superior method compared to transabdominal ultrasonography used for imaging of GB lesions because devices with lower ultrasound frequency can provide high resolution images of small lesions (12). Since this facility is not available in our hospital, in our study, all patients were evaluated by US and MRCP before the ERCP procedure and it was shown that there was stones in biliary tract and no stones in GB. In the cases included in our study, the fact that the GB was not evaluated by EUS can be considered as a criticism.

There are two questions that should be answered when patients have stones both in the GB and bile duct at the same time; (1) what is the best method for clearing the bile duct; and (2) what should be done with the GB? In the United States and Europe, 75% of bile duct stones are cholesterol stones. If these stones are of bile origin, it is reported that GB dysfunction persists even if stones are removed. Approximately 15% of patients with cholecystolithiasis have simultaneous choledocholithiasis whereas 95% of patients with choledocholithiasis are associated with cholecystolithiasis (14). In our study, 4 % of the patients who underwent ERCP had no stones in the GB. Patients, who did not have any complaints after ERCP procedure, were discharged with the suggestion of outpatient control 6-8 weeks later. In the treatment of cholecystolithiasis and choledocholithiasis, the traditional method is firstly ERCP and then cholecystectomy 6-8 week later. Currently, early cholecystectomy (<72 hours) may be preferred in the treatment of acute cholecystitis due to its advantages such as less complications (especially biliary tract injury) and shorter hospital stay (15). In the case of cholelithiasis and choledocholithiasis, there are some studies suggesting ERCP and laparoscopic cholecystectomy even in the same session (16, 17). In our study, there was also a dilemma about the GB. After eradication of choledochal stones with ERCP, these patients were taken to the outpatient clinic. In the first month follow-up visits after ERCP procedure, the patients did not have any complaints about GB and control USG revealed no GB stones, so follow-up

decision was taken. On further consideration, it is difficult to say that the treatment is complete without a procedure involving the GB if the stone in the common bile duct is primary. If the stone is secondary, which means that it migrated from GB to the bile duct, it is debatable how safe it is to follow-up only. Some studies have shown that the formation of cholesterol stones in the GB is due to postprandial GB emptying. Therefore, if we accept some of the common bile duct stones as secondary bile duct stones in our study, the decision to follow-up is open for discussion; therefore a criticism can be made in our study on this subject. The distinction between primary and secondary choledocholithiasis is of practical importance as it requires different treatment. In a study to determine this difference in the literature, microbiological and biochemical analyses were performed on the bile of two patient groups (27 patients with GB-derived stones and 5 patients with primary main bile duct stones). Although it did not make sense for patients with primary choledocholithiasis, the incidence of duodenal diverticulosis was “ $p=0.15$ ” and the incidence of E.coli-positive culture in bile was “ $p <0.001$ ” (18). Besides, the color of the stones can give information about the formation mechanism of the stones. It has been reported that black and brown pigment stones have different pathogenic mechanisms and bacterial infection is important only in the formation of brown pigment (19). Secondary stones are composed of cholesterol whereas primary stones are composed of pigmented bile acids. In our study, microbiological and biochemical analyses of stones extracted from choledochus with ERCP were not performed and therefore it may be subject to criticism.

Cholecystectomy is the treatment method of GB stones. However, recent studies have focused on the use of GSS in patients with cholelithiasis, which has become a topic of interest in the literature. In study Tan YY et al. (20) involving 61 patients, only GB stone was removed by preserving the GB with minimally invasive surgery and the success rate was 93.8%. After the operation, the patients were taken to clinical and US monitoring every 6 months. Total stone recurrence rate was 4.92% over a mean follow-up of 26 months (range 6-40). In addition, it was reported that GB function was not affected and stone recurrence rate was very low (20).

GSS is an important field of application of minimally invasive endoscopic surgery in the treatment of biliary diseases, thus this practice provides a complementary approach to the treatment of cholelithiasis (21). Based on an increasing number of GSS applications, some authors have reported that this option is a viable technique for cholelithiasis patients in selected cases with normal GB function, and randomized controlled trials are required to be accepted (22).

In a study of Tian MG et al., retrograde biliary drainage was concluded to be an optimal method for the preservation of GB during surgical treatment of primary bile duct stones. After surgical removal of primary bile duct stones, preserved intact GB did not develop new gallstones (23). When we review the

literature, we think that it is possible to follow up without cholecystectomy when GSS is performed in patients who have secondary or primary common bile duct stones and have functional GB.

In conclusion, we think that in patients with secondary or primary choledochal stones without

gallstones and with functional GB might be follow up without cholecystectomy after the stone is removed from the bile duct by ERCP. In cases where cholecystitis attacks do not develop in the follow-up of these patients, they can be followed without cholecystectomy.

## REFERENCES

1. Molvar C, Glaenger B. Evaluation, Treatment, and Outcomes. *Semin Intervent Radiol*. 2016 Dec;33(4):268-276.
2. European Association for the Study of the Liver (EASL). Electronic address: easloffice@easloffice.eu, EASL Clinical Practice Guidelines on the prevention, diagnosis and treatment of gallstones. *J Hepatol*. 2016;65(1):146–181.
3. R Costi, A Gnocchi, F Di Mario, and L Sarli. Diagnosis and management of choledocholithiasis in the golden age of imaging, endoscopy and laparoscopy. *World J Gastroenterol*. 2014 Oct 7; 20(37): 13382–13401.
4. James Y.W. Lau, Yuk Tong Lee, and Joseph Sung. Chapter 43. Choledocholithiasis, Section III—Approach to Clinical Problems. Press: 2015. p. 410-418. Available from: <http://blog.utp.edu.co/cirurgia/files/2011/07/coledocolitiasis-2015.pdf>
5. Tan YY, Zhao G, Wang D, Wang JM, Tang JR, Ji ZL. A new strategy of minimally invasive surgery for cholecystolithiasis: calculi removal and gallbladder preservation. *Dig Surg*. 2013;30(4-6):466-71.
6. G Watanabe, M Hashimoto, M Matsuda, Evaluation of 'New classification of Japanese gallbladder stones (1986)' with chemical componential analysis, Tando, 2017, Volume 31, Issue 2, Pages 205-213, Released June 07, 2017, Online ISSN 1883-6879, Print ISSN 0914-0077.
7. Gregory A. Bortoff, Michael Y. M. Chen et al. Gallbladder Stones: Imaging and Intervention. Vol. 20, No. 3 Published Online: May 1 2000 <https://doi.org/10.1148/radiographics.20.3.g00ma16751>
8. Marilee L Freitas, Robert L Bell, and Andrew J Duffy. Evolving standards for diagnosis and management. *World J Gastroenterol*. 2006 May 28; 12(20): 3162–3167.
9. Shea JA, Berlin JA, Escarce JJ, Clarke JR, Kinoshian BP, Cabana MD, Tsai WW. et al. Revised estimates of diagnostic test sensitivity and specificity in suspected biliary tract disease. *Arch Intern Med*. 1994;5(22):2573–2581.
10. Pinto A, Reginelli A, Cagini L, Coppolino F, Stabile Ianora AA, Bracale R et al. Accuracy of ultrasonography in the diagnosis of acute calculous cholecystitis: review of the literature. *Crit Ultrasound J*. 2013 Jul 15;5 Suppl 1:S11.
11. Grantcharov TP, Rasti Z, Rossen B, Kristiansen VB, Rosenberg J. Interobserver agreement in ultrasound examination of the biliary tract. *Acta Radiol*. 2002;5(1):77–79
12. Malay Sharma, Piyush Somani, and Tagore Sunkara. Imaging of gall bladder by endoscopic ultrasound. *World J Gastrointest Endosc*. 2018 Jan 16; 10(1): 10–15. Published online 2018 Jan 16. doi: 10.4253/wjge.v10.i1.10
13. Freitas ML, Bell RL, Duffy AJ. Evolving standards for diagnosis and management. *World J Gastroenterol*. 2006 May 28;12(20):3162-7
14. Pritesh Mutha Email, Tilak Shah Douglas, Heuman Alvin et al. Choledocholithiasis Without Cholelithiasis: Should the Gallbladder Stay or Should It Go? *Digestive Diseases and Sciences* April 2016, Volume 61, Issue 4, pp 961–962
15. Altieri MS, Brunt LM, Yang J, Zhu C, Talamini MA, Pryor AD. Early cholecystectomy (< 72 h) is associated with lower rate of complications and bile duct injury: a study of 109,862 cholecystectomies in the state of New York. *Surg Endosc*. 2019 Aug 2.
16. Terauchi T, Shinozaki H, Shinozaki S, Sasakura Y et al. Single-Stage Endoscopic Stone Extraction and Cholecystectomy during the Same Hospitalization. *Clin Endosc*. 2019 Jan;52(1):59-64.
17. Bahtiyar M. Single-stage treatment with ERCP and laparoscopic cholecystectomy versus two-stage treatment with ERCP followed by laparoscopic cholecystectomy within 6 to 8 weeks: A retrospective study. *Turk J Surg*. 2019 Sep;35(3): 178–184.
18. García Ontiveros A, Cantero Hinojosa J, Gil Extremera B, Miñarro del Moral J. Differences in gallstone structure in primary common bile duct lithiasis and gallbladder lithiasis. *Klin Wochenschr*. 1990 May 17;68(10):496-502.
19. Kaufman HS, Magnuson TH, Lillemoen KD, Frasca P, Pitt HA. The role of bacteria in gallbladder and common duct stone formation. *Ann Surg*. 1989 May;209(5):584-91; discussion 591-2.
20. Tan YY, Zhao G, Wang D, Wang JM, Tang JR, Ji ZL. A new strategy of minimally invasive surgery for cholecystolithiasis: calculi removal and gallbladder preservation. *Dig Surg*. 2013;30(4-6):466-71.
21. De -Kang Gao, Shao-Hua Wei, Wei Li Jie Ren et al. Totally laparoscopic gallbladder-preserving surgery: A minimally invasive and favorable approach for cholelithiasis. *Exp Ther Med*. 2015 Feb; 9(2): 395–398.
22. Hakan Akinci. Laparoscopic gallbladder-preserving surgery: Case report. *Laparosc Endosc Surg Sci* 2019;26(1):32-35
23. Ming-Guo Tian, Wei-Jin Shi, Xin-Yuan Wen, Hai-Wen Yu et al. Outcome of gallbladder preservation in surgical management of primary bile duct stones. *World J Gastroenterol*. 2003 Aug 15; 9(8): 1871–1873.