

Kocatepe Vet.J (2014) 7(1): 81-84
DOI: 10.5578/kvj.7198
Submission: 10.12.2013
Accepted: 13.02.2014

SHORT COMMUNICATIONS

KISA BİLDİRİ

Key Words

Cat
Conjunctivitis
Famciclovir
FHV-1
L-lysine

Anahtar Kelimeler

Kedi
Konjunktivit
Famciclovir
FHV-1
L-lysine

Ankara University
Faculty of Veterinary Medicine
Department of Surgery
Ankara/Turkey

*Corresponding author

Email: iremgulsancak@gmail.com

Telefon: : 0 (535) 414 84 48

**Treatment of Feline Herpes Virus-1 (FHV-1) associated ocular lesions
with Famciclovir in 3 cats**

İrem GÜL SANCAK*, İrem ERGİN

S U M M A R Y

Feline herpesvirus-1 (FHV-1) associated ocular lesions and it's treatment was presented in two adult cats and one kitten. Adult cats were showing corneal edema, conjunctivitis and corneal sequestrum while ocular discharge, conjunctivitis and keratitis was predominant in the kitten. Conjunctival swabs obtained from the cats were evaluated with PCR and found positive against FHV-1. Effectiveness of systemic anti-herpes drug, Famciclovir combination with L-lysine in the clinical management of FHV-1 were investigated. Famciclovir was found to be an effective drug in combination with the L-lysine in the treatment of FHV-1 infection. The treatment was well tolerated and the clinical signs were resolved in all cats.



**Üç kedide Feline Herpes Virus-1 (FHV-1) ilişkili okuler lezyonların
Famciclovir ile sağaltımı**

ÖZET

Bu çalışmada, üç kedide kedi herpesvirus Tip-1 (FHV-1) ile ilişkili gözlenen göz bulguları ve tedavisi üzerinde durulmuştur. Çalışmaya göz bulguları bulunan iki ergin ve bir yavru kedi dahil edilmiştir. Ergin kedilerde korneal ödem, konjunktivit ve korneal sekester gözlenirken, yavru kedide öne çıkan bulgular göz akıntısı konjunktivit ve keratit olarak izlenmiştir. Kedilerden elde edilen konjunktival svaplar FHV-1 yönünden PCR ile değerlendirilmiş ve pozitif bulunmuştur. Tedavide sistemik anti-herpes ilaç olarak Famciclovir'in (Famvir, Novartis) L-lysine ile kombinasyonu kullanılmıştır. FHV-1 enfeksiyonunun tedavisinde Famciclovir'in L-lysine ile kombinasyonu etkili bulunmuştur. Her üç kedide de tedavinin iyi tolere edildiği ve klinik bulguların düzeldiği izlenmiştir.

INTRODUCTION

Feline herpes virus type-1 (FHV-1) is one of the most common causes of respiratory infections and eye problems in cats. Up to 97% of cats have serological evidence of exposure to FHV-1. Following recovery from the initial episode, most cats (80%) may become latently infected with FHV-1 (Thomasy et al 2011). Even the carrier cats can remain asymptomatic for long periods of time they continue to harbor the virus in the nerve cells and can pass it on to the uninfected cats. The virus may flare up when the cat is stressed. These stress factors include systemic illness, estrus, pregnancy, or lactation, disruption of the cat's household, surgery or corticosteroid therapy. FHV-1 is rarely fatal in adults, but mortality rates can reach more than 30% in young kittens who are often infected by their carrier mothers. Common clinical symptoms in adults are chronic conjunctivitis or recurrent corneal ulcers, while in kittens sneezing, nasal discharge, ocular discharge and conjunctivitis are predominant (Andrew 2001). Unlike the initial infection, usually only one eye is affected. Respiratory symptoms are not present in most chronic cases. For treatment of cats infected with FHV-1, there are no drugs ready to use in cats in the market. Some antiviral agents that are used in humans can be used in cats but either the clinic efficacy is very low or the drug is toxic to the cat. Due to the mechanism of action (very short half-life) of topical antiviral medications, frequent (5-6 applications daily) administration is recommended. Commonly used topical drugs include trifluridine, idoxuridine, vidarabine, bromovinyldeoxyuridine and acyclovir. Systemic use of some drugs are also tested, but their use are not effective in cats due to toxicity and low effective concentration. In recent reports, the use of Famciclovir as systemic drug has promising results (Malik et al 2009, Thomasy et al 2012).

CASE REPORT

Case 1

A 3-year-old castrated Persian cat was presented with a focal corneal sequestrum on the left eye arising from the medial cantus (Figure 1a). Ocular and nasal discharge and conjunctivitis was present on the time of presentation. Before coming to our clinic, the cat was put into topical corticosteroid and antibiotic therapy for 1 week, which worsened the clinical course of the disease. Corneal swabs have shown positivity for FHV-1 infection. Previous therapy stopped and cat was treated with Famciclovir (Famvir, Novartis) and L-lysine, cyclopentolate HCL (Sikloplejin, Abdi

Ibrahim) treatment. First week 125 mg famciclovir and 250 mg L-lysine orally (b.i.d.) introduced and then the dose was reduced s.i.d. The clinical symptoms regressed and in the 15th day on eye examination, the lesion was observed as a small vascularization rather than a corneal sequestrum (Figure 1b). The therapy was continued for 2 months with 125 mg Famciclovir and 250 mg L-lysine once daily. Since then, there is no recurrence observed.

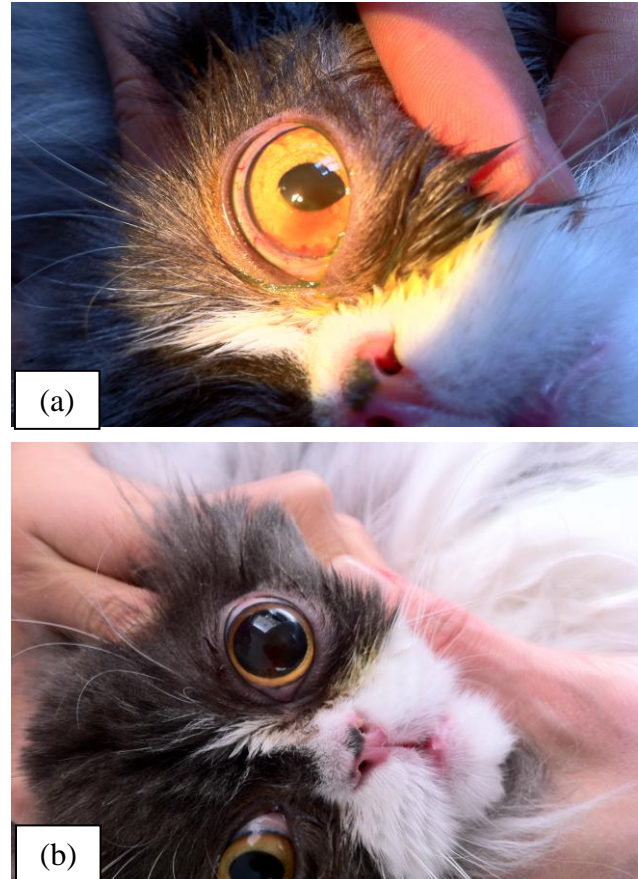


Figure 1: FHV-1 associated corneal sequestrum on the left eye of a cat before (a) and during (b) Famciclovir (Famvir) treatment.

Şekil 1: Bir kedinin sol gözünde FHV-1 ilişkili korneal sekesterin Famciclovir ile tedavi öncesi (a) ve tedavi sırasındaki (b) görünümü.

Case 2

A-3-year old Siamese cat was presented with corneal edema affecting the right eye (Figure 2a). Clinical examination revealed severe conjunctivitis, prolapse of the gland of third eyelid and severe edema on the corneal surface. Epithelial edema with corneal epithelial breaks showing fluorescein positivity was found in the slit-lamp examination. Fundus, optic nerve and retinal vasculature appeared normal. Lomefloxacin

hydrochloride (Okacin, Novartis) ophtalmic solution was applied t.i.d. topically. On the 4th day of initial presentation, fluorescein staining was found to be negative and corticosteroid eye drop (0,2% Prednisolone acetate) was used t.i.d. topically with Lomefloxacin hydrochloride. One week after the initial presentation, the conjunctival infection had improved, but corneal edema was persistent. Conjunctival swabs taken from the affected eye of the cat was positive against FHV-1. Famciclovir was administered 125 mg orally b.i.d. for 7 days in combination with cyclopentolate HCL and 250 mg L-lysine b.i.d. After first week (Figure 2b) the dose reduced once daily and continued (Figure 2c) until 2 months.

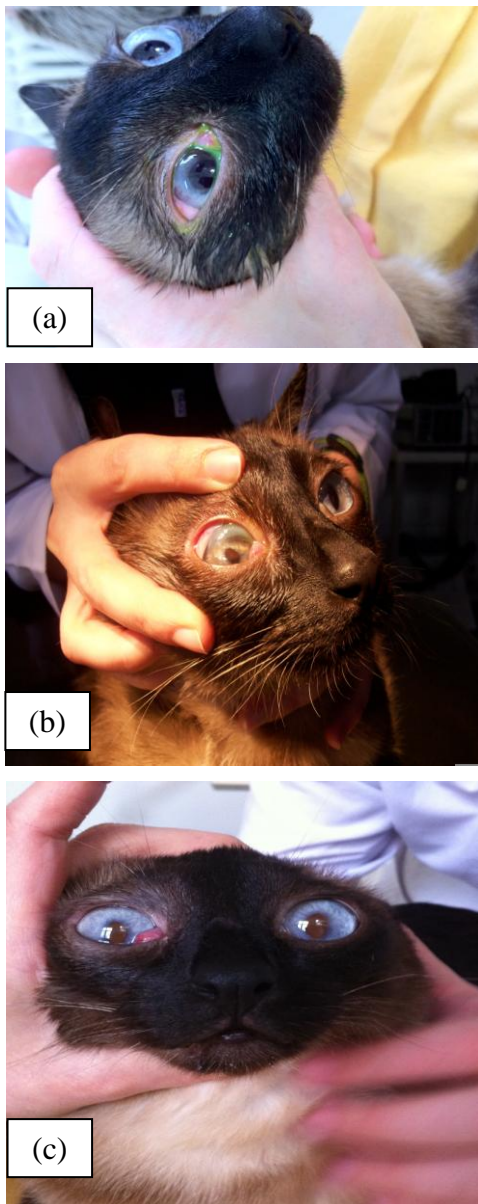


Figure 2: FHV-1 associated corneal edema on the right eye of a cat before (a), in first week (b) and second week (c) Famciclovir treatment.

Şekil 2: Bir kedinin sağ gözünde FHV-1'e bağlı korneal ödemin famciclovir ile tedavi öncesi (a), birinci haftası (b) ve ikinci haftasındaki (c) görünümü.

Case 3

3-month-old mix breed kitten was presented mucopurulent ocular discharge, conjunctival infection and severe keratitis on the left eye. On anamnesis, it was noted that two kittens from the same litter died because of loss of appetite and severe ocular and nasal discharge. Conjunctival swabs taken from the affected eye was positive against FHV-1. Famciclovir was administered 125 mg orally b.i.d. for 7 days in combination with cyclopentolate HCL and 250 mg L-lysine b.i.d. After first week, the dose reduced once daily and continued until 2 months. It was noted that all of the cats gained weight prior to therapy.

DISCUSSION

It is reported that oral administration of 90 mg/kg Famciclovir t.i.d. to cats experimentally inoculated with FHV-1 was associated with significant reductions in total clinical disease presentation (Thomasy et al 2011). For this reason, three cats were treated 125 mg/kg Famciclovir twice daily for one week and the maintenance was made once daily at the same dose in this study. Overall an increase was detected in body weight throughout the study and significant improvement in the clinical findings of cats.

Due to the local immune suppression and retardation of corneal epithelialisation that occur with topical corticosteroid use, corticosteroid administration should not be considered with most forms of FHV-1 infections. Corticosteroid use may also encourage reactivation of latent infection (Nasissse 1990). In this study, in two adult cats use of corticosteroid has reactivated the latent FHV-1 infection and worsened the clinical course of the disease.

The in vitro efficacy of topical anti-virals against FHV-1 is trifluridine>idoxuridine>vidarabine > bromovinyldeoxyuridine > acyclovir (Nasissse et al 1989a). Systemic administration of antiviral drugs has also been investigated in the cat. Acyclovir is commonly used in humans for herpes virus, but cannot reach effective plasma concentration in cats (Nasissse et al 1989b, Williams et al 2005). Valacyclovir is another purine nucleoside, which was found to be extremely toxic to cats (Nasissse et al 1997). In recent studies, systemic use of Famciclovir in cats has promising

results (Malik et al 2009). Oral supplementation with the amino acid L-lysine has been shown to decrease the viral shedding rate in FHV-1 positive cats (Nasisse et al 1997, Maggs et al 2003). L-lysine may be a competitive inhibitor of arginine and by this way inhibition of FHV-1 growth in vitro has been shown with L-lysine supplementation (Maggs et al 2003). In these cases, the trial of L-lysine with systemic antiviral drug Famciclovir has shown positive results in the treatment of the FHV-1 infection and the systemic antiviral agent is well tolerated by the cats. We could recommend to our colleagues that it is better to make a virologic test before using any medication because blind therapies could reactivate the diseases or worsens the clinical outcomes.

REFERENCES

- Andrew SE.** Ocular manifestations of feline herpesvirus. *J Feline Med Surg.* 2001; 3: 9–16.
- Maggs DJ, Nasisse MP, Kass PH.** Efficacy of oral supplementation with L-lysine in cats latently infected with feline herpesvirus. *Am J Vet Res.* 2003; 64(1): 37-42.
- Malik R, Lessels NS, Webb S, Meek M, Graham GP, Vitale C, Norris JM, Power H.** Treatment of Feline Herpesvirus-1 associated disease in cats with Famciclovir and related drugs. *J Feline Med Surg.* 2009; 11: 40-48.
- Nasisse MP.** Feline herpesvirus ocular disease. *Vet Clin North Am Small Anim Pract.* 1990; 20(3): 667-680.
- Nasisse MP, Guy JS, Davidson MG, Sussman W, De Clercq E.** In vitro susceptibility of Feline Herpesvirus-1 to vidarabine, idoxuridine, trifluridine, acyclovir, or bromovinyldeoxyuridine. *Am J Vet Res.* 1989a; 50(1): 158-160.
- Nasisse MP, Guy JS, Davidson MG, Sussman WA, Fairley NM.** Experimental ocular herpesvirus infection in the cat. Sites of virus replication, clinical features and effects of corticosteroid administration. *Invest Ophthalmol Vis Sci.* 1989b; 30: 1758-1768.
- Nasisse MP, Dorman DC, Jamison KC, Weigler BJ, Hawkins EC, Stevens JB.** Effects of valacyclovir in cats infected with feline herpesvirus 1. *Am J Vet Res.* 1997; 58(10): 1141-1444.
- Thomasy SM, Lim CC, Reilly CM, Kass PH, Lappin MR, Maggs DJ.** Evaluation of orally administered famciclovir in cats experimentally infected with feline herpesvirus type-1. *Am J Vet Res.* 2011; 72: 85–95.
- Thomasy SM, Covert JC, Stanley SD, Maggs DJ.** Pharmacokinetics of famciclovir and penciclovir in tears following oral administration of famciclovir to cats: A pilot study. *Vet Ophthalmol.* 2012; 15: 299-306.
- Williams DL, Robinson JC, Lay E, Field H.** Efficacy of topical aciclovir for the treatment of feline herpetic keratitis: Results of a prospective clinical trial and data from in vitro investigations. *Vet Rec.* 2005; 157: 254-257.