

Unilateral approach for bilateral microdecompression in lumbar stenosis: the detailed assessment of clinical, functional and radiological changes

Lomber dar kanalda iki taraflı mikrodekompresyon için tek taraflı yaklaşım: klinik ve radyolojik değişikliklerin detaylı araştırılması

İsmail İştemen, Ali Arslan, Ali İhsan Ökten, Semih Kıvanç Olguner, Kemal Alper Afşer, Vedat Açık, Emre Bilgin

Gönderilme tarihi: 10.03.2020

Kabul tarihi: 20.04.2020

Abstract

Purpose: Previous articles have mostly evaluated only radiological or clinical improvement to assess decompression. But there has been no detailed study in the literature evaluating both quality of life and functional and radiological improvement. In this study, we aimed to investigate the effectiveness of microsurgical unilateral laminotomy to perform bilateral decompression for degenerative lumbar spinal stenosis.

Materials and methods: We assessed 116 segments in 80 patients retrospectively. We evaluated clinical, functional and radiological improvement. For clinical evaluation Visual Analog Scale (VAS), Oswestry Disability Index (ODI), Medical Outcomes Study 36-Item Short- Form Health Survey (SF36) were used. For radiological evaluation, we assessed the changes of anterior and posterior disc height, lateral resses heigt, anteior-posterior diameter of spinal canal, spinal canal cross sectional area, segmental lordotic angle on preoperative and postoperative radiographic images. For functional evaluation, walking performance was also evaluated by 15 Minutes Self Paced Walking Test.

Results: The mean age of the patients was 58.6±11.3 years. Forty-two of them were females (52.5%), and thirty-eight were males (47.5%). Clinical outcomes, measured by VAS, ODI and SF36 were improved significantly. Walking performance, dural sac cross sectional area and other radiographic measurments were also improved significantly. Eight patients were reoperated due to the spinal instability, and 4 patients due to the dura repair. Only two wound infections developed.

Conclusion: Microsurgical unilateral laminotomy for bilateral decompression for degenerative spinal stenosis achieves adequate decompression and satisfactory clinical outcomes with minimal tissue damage and less complications.

Key words: Degenerative spinal stenosis, minimal invasive spine surgery, unilateral laminotomy with bilateral decompression.

İştemen İ, Arslan A, Ökten Aİ, Olguner SK, Afşer AK, Açık V, Bilgin E. Unilateral approach for bilateral microdecompression in lumbar stenosis: the detailed assessment of clinical, functional and radiological changes. Pam Med J 2020;13:393-402.

Özet

Amaç: Önceki makaleler çoğunlukla dekompresyonu göstermek için sadece radyolojik veya klinik iyileşmeyi değerlendirmiştir. Ancak literatürde hem yaşam kalitesini hem de fonksiyonel ve radyolojik iyileşmeyi değerlendiren ayrıntılı bir çalışma yoktur. Bu çalışmada dejeneratif lomber spinal stenozda bilateral dekompresyon için mikrocerrahi ile tek taraflı laminotominin etkinliğini araştırmayı amaçladık.

Gereç ve yöntem: 80 hastada 116 segmenti retrospektif olarak inceledik. Klinik, fonksiyonel ve radyolojik iyileşmeyi değerlendirdik. Klinik değerlendirme için Vizüel Analog Skala (VAS), Oswestry Disability İndeksi (ODI), Tıbbi Sonuçlar Çalışması 36 Madde Kısa Form Sağlık Araştırması (SF36) kullanıldı. Radyolojik değerlendirme için ön ve arka disk yüksekliği, lateral resses yüksekliği, spinal kanalın ön-arka çapı, spinal kanal kesitsel

İsmail İştemen, Specialist in Neurosurgery, Adana City Education and Research Hospital, Neurosurgery Department, Adana, Turkey, e-mail: drismailistemen@gmail.com (orcid.org/0000-0002-2341-4818) (Corresponding Author)

Ali Arslan, Specialist in Neurosurgery, Adana City Education and Research Hospital, Neurosurgery Department, Adana, Turkey, e-mail: aliarslan26062006@hotmail.com (orcid.org/0000-0002-7457-5283)

Ali İhsan Ökten, Associate Professor in Neurosurgery, Adana City Education and Research Hospital, Neurosurgery Department, Adana, Turkey, e-mail: aihano1@gmail.com (orcid.org/0000-0003-0292-201X)

Semih Kıvanç Olguner, Specialist in Neurosurgery, Adana City Education and Research Hospital, Neurosurgery Department, Adana, Turkey, e-mail: kivanc3olguner@hotmail.com (orcid.org/0000-0002-5314-4636)

Kemal Alper Afşer, Trainee in Neurosurgery, Adana City Education and Research Hospital, Neurosurgery Department, Adana, Turkey, e-mail: kemalalperafser@gmail.com (orcid.org/0000-0002-4724-0840)

Vedat Açık, Specialist in Neurosurgery, Adana City Education and Research Hospital, Neurosurgery Department, Adana, Turkey, e-mail: vedatacik74@gmail.com (orcid.org/0000-0002-0371-5883)

Emre Bilgin, Specialist in Neurosurgery, Adana City Education and Research Hospital, Neurosurgery Department, Adana, Turkey, e-mail: dremreblgn@gmail.com (orcid.org/0000-0002-2394-1503)

alanı, preoperatif ve postoperatif radyografik görüntülerde segmental lordotik açıları ölçümledik. Fonksiyonel değerlendirme için yürüme performansı da 15 Dakika Kişisel Hızda Yürüyüş Testi ile değerlendirildi.

Bulgular: Hastaların ortalama yaşı $58,6 \pm 11,3$ idi. Kırk ikisi kadını (%52,5) ve otuz sekizi erkekti (%47,5). VAS, ODI ve SF36 ile ölçülen klinik sonuçlar önemli ölçüde iyileşti. Yürüme performansı, dural kese kesit alanı ve diğer radyografik ölçümler de önemli ölçüde iyileşti. Spinal instabilite nedeniyle 8 hasta, dura onarım nedeniyle 4 hasta tekrar ameliyat edildi. Sadece iki yara enfeksiyonu gelişti.

Sonuç: Dejeneratif spinal stenozda bilateral dekompresyon için mikrocerrahi ile tek taraflı laminotomi, minimum doku hasarı ve daha az komplikasyon ile yeterli dekompresyon ve tatmin edici klinik sonuçlar sağlar.

Anahtar kelimeler: Lomber dar kanal, minimal invaziv cerrahi, tek taraftan bilateral dekompresyon.

İştemen İ, Arslan A, Ökten Aİ, Olguner SK, Afşer AK, Açık V, Bilgin E. Lomber dar kanalda iki taraflı mikrodekompresyon için tek taraflı yaklaşım: klinik ve radyolojik değişikliklerin detaylı araştırılması. Pam Tıp Derg 2020;13:393-402.

Introduction

Degenerative lumbar spinal stenosis (DLSS) is a common lumbar pathology characterized by back/leg pain and neurogenic claudication [1, 2]. Hypertrophy of the ligamentum flavum, intervertebral disc degeneration and bulging, and facet joint arthropathy with hypertrophy result in stenosis of the spinal canal and neural foramina, which causes the symptoms. As the elderly population has increased, so has the incidence of DLSS [3].

Among the numerous treatment options, surgical decompression is more effective than medical treatment and physical therapy [4, 5]. Various decompressive methods have been described. The goal of surgical decompression is maximal neural decompression while preserving structural components as much as possible [5, 6]. Traditional total laminectomy has been widely used in the surgical treatment of DLSS [2, 7]. Surgical outcomes are satisfactory but spinal instability may result and require spinal fixation and fusion [8]. In recent years, minimally invasive DLSS treatment techniques such as unilateral laminotomy for bilateral decompression (ULBD) have been described [5, 9]. ULBD can achieve maximal decompression with less tissue damage. Most previous ULBD studies have evaluated only radiographic outcomes of surgical decompression; quality of life and functional improvement after ULBD have not been well-studied. Therefore, we investigated outcomes of microsurgical ULBD for DLSS using the Visual Analogue Pain Scale (VAS), Medical Outcomes Study 36-Item Short-Form Health Survey (SF-36), Oswestry Disability

Index (ODI), and 15-Minute Self-Paced Walking Test (SPWT). We also investigated radiographic outcomes.

Materials and methods

We retrospectively analyzed 80 consecutive patients who underwent ULBD between January 2013 and January 2016. The total number of operated levels was 116. Mean follow-up period was 34.32 ± 4.57 months. All patients exhibited ≤ 3 mm of intervertebral translation on lateral flexion-extension lumbar radiographs before surgery. Patients with a spondylolysis defect, osteoporosis, or degenerative scoliosis were excluded. Pre- and postoperative lateral radiographs, computed tomography (CT), and magnetic resonance imaging (MRI) were evaluated to assess changes of anterior and posterior disc height, lateral recess height, anterior-posterior diameter and cross-sectional area of the spinal canal, and segmental lordotic angle (Figure 1 A, B, C). Radiological measurements were calculated from the picture archiving and communication system (PACS). Clinical outcomes were evaluated using the VAS, SF-36, and ODI. The ODI is a questionnaire that assesses the effect of back and leg pain on daily life. The SF-36 is a 36-item questionnaire comprised of 8 health concept scales: physical functioning (PF), role limitation-physical (RP), bodily pain (BP), general health (GH), vitality (VT), social function (SF), role limitation- emotional (RE), and mental health (MH). Participants completed the 15-minute SPWT one day before and six months after surgery to assess walking performance.

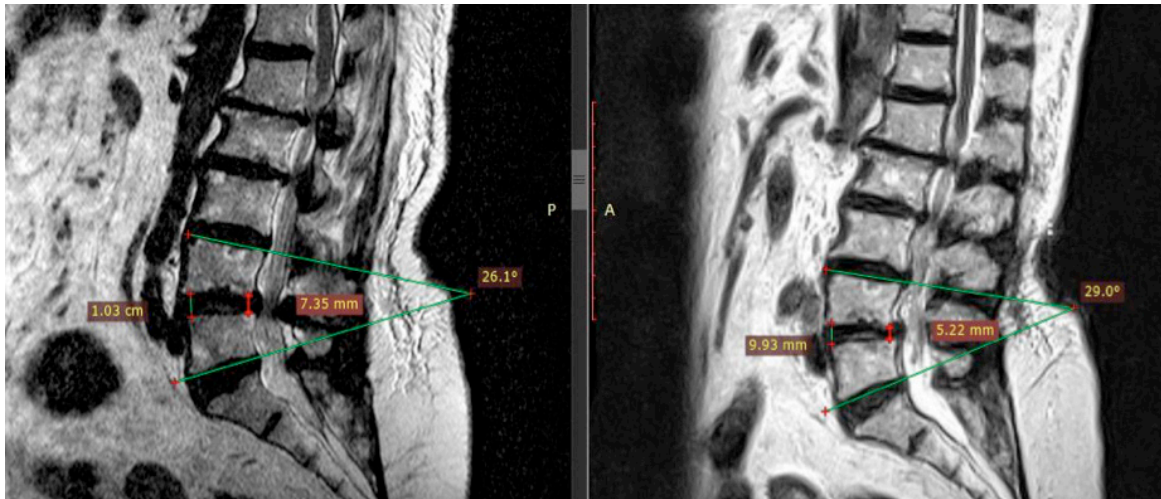


Figure 1A. Cross-sectional area of the spinal canal on preoperative and postoperative MRI.

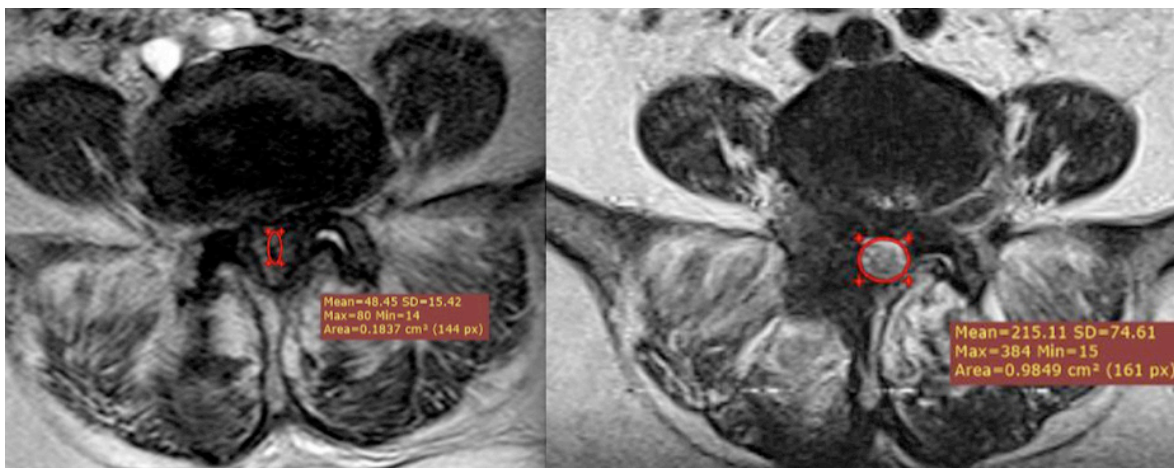


Figure 1B. Spinal canal cross-sectional area on preoperative and postoperative MRI.

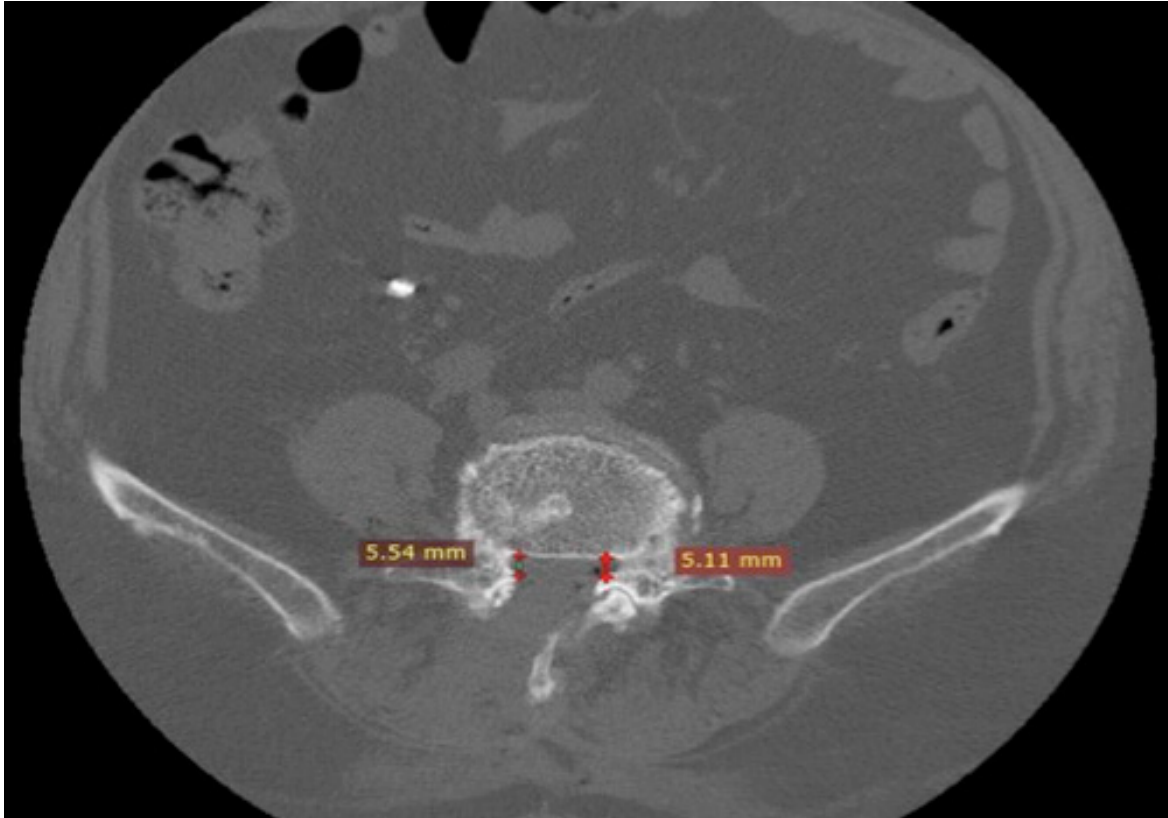


Figure 1C. Lateral recess height on postoperative CT scan.

Surgical procedure

All patients underwent general endotracheal anesthesia for surgery. The operative level was localized using fluoroscopic guidance. A fascial incision was performed on the most symptomatic side. If there was no lateralization of symptoms, the left-sided approach was used because it provides advantages to a right-handed surgeon. The paraspinal muscles were elevated off the spinous process and lamina by subperiosteal dissection. After this step, the operating microscope was brought into the surgical field. Hemi-laminotomy of the ipsilateral cephalad lamina was performed using Kerrison rongeurs or a high-speed drill. Then, a less extensive laminotomy of the caudal lamina was performed. The ipsilateral ligamentum flavum was totally resected with a Kerrison rongeur. The medial facet joint was then partially resected. The compressed nerve root was found and decompressed by foraminal widening. If necessary, an ipsilateral discectomy was performed.

After ipsilateral micro-decompression, the microscope was angulated medially and the patient was tilted contralaterally to optimize

visualization of the contralateral nerve root. The base of the spinous process and the inferior surface of the contralateral lamina and the ligamentum flavum were removed with Kerrison rongeurs and a high-speed burr and the contralateral nerve root and dura were completely decompressed. If necessary, the same surgical approach was performed at each indicated level.

Statistical analyses

Statistical analyses were performed using SPSS software version 18 (IBM Corp., Armonk, NY, USA). Numerical variables are presented as means with standard deviation or medians with interquartile range (IQR). Categorical variables are presented as frequencies with percentage. Independent group comparisons were analysed using the Mann-Whitney U test. Dependent group comparisons of preoperative and postoperative variable measurements were performed using the Wilcoxon signed-rank and Friedman tests as appropriate. $P < 0.05$ was considered significant.

Results

A total of 80 patients were included for analysis. Forty-two were female (52.5%), and thirty-eight were male (47.5%). Gender distribution is shown in Figure 2.

Mean patient age was 58.6±11.3 years. The mean age of male and female patients was similar ($p=0.755$). The age distribution of the study group is shown in Table 1.

The most frequent patient symptoms was leg pain predominant on the right side in 48 patients (60%). The most frequent neurological examination finding was right dorsiflexion weakness (1/5 on manual muscle testing) in 26 patients (32.5%). The most frequent level of disease was right L4-5 in 46 patients (39.7%). Table 2 summarizes the patient symptoms and neurological examination findings and levels of disease.

The pre- and postoperative SF36 and ODI assessments are presented in Table 3. Postoperative SF36 scores significantly increased ($p<0.001$) and ODI scores significantly decreased ($p<0.001$) in all domains compared to before surgery. The pre- and postoperative radiographic measurements are presented in Table 4. All measurements significantly changed between the pre- and postoperative period ($p<0.001$). Median VAS scores in the pre- and postoperative periods are presented in Table 5. VAS score significantly decreased between the preoperative period and postoperative day 1 ($p<0.001$); the postoperative day 1 and 6-month postoperative scores were similar ($p=0.172$).

All patients had varying degrees of neurogenic claudication symptoms. The changes in 15-minute SPWT are shown in Table 6. The 6-month postoperative walking distances were significantly higher than the preoperative walking distances ($p<0.001$).

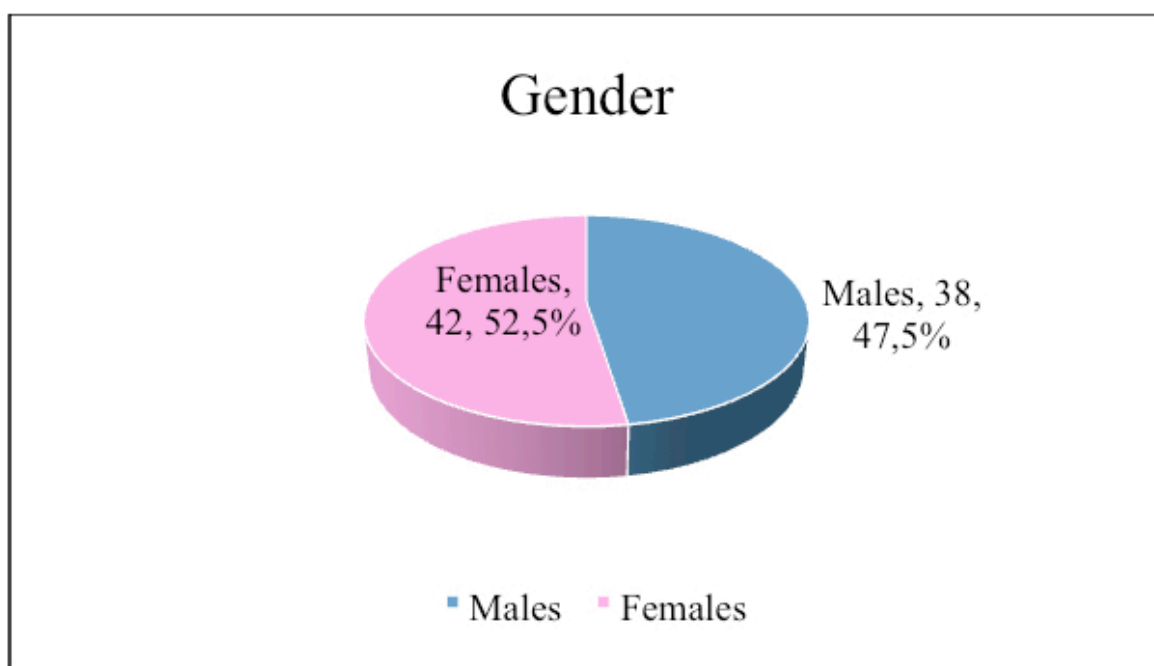


Figure 2. Gender distribution of the patients.

Table 1. Age distribution of the patients.

	All patients	Gender		<i>p</i>
		Male	Female	
	Mean ± SD	Mean ± SD	Mean ± SD	
Age (years)	58.6±11.3	58.4±9.2	58.7±13.1	0.755

Table 2. Clinical characteristics of the patients.

	n	%
Complaint		
Leg Pain Predominant On Right Side	48	60
Leg Pain Predominant On Left Side	22	27.5
Leg Pain Bilaterally	10	12.5
Neurologic examination		
Abbreviations:		
FDF: Foot dorsal flexion		
FPF: Foot plantar flexion		
KE: Knee extension		
Right FDF 1/5 Deficit	26	32.5
No Deficit	10	12.5
Left FDF 2/5 Deficit	8	10
Both FDF 1/5 Deficit	8	10
Right FDF-FPF 1/5 Deficit	6	7.5
Both FDF 2/5 Deficit	4	5
Left FDF 1/5 Deficit	4	5
Left FPF 2/5 Deficit	4	5
Both FDF 2/5 Deficit	2	2.5
Right FDF 2/5 Deficit	2	2.5
Right FDF-KE 1/5 Deficit	2	2.5
Right KE 2/5 Deficit	2	2.5
Left FDF-FPF 1/5 Deficit	2	2.5
Level		
Right L4-5	46	39.7
Left L4-5	26	22.4
Right L3-4	22	19
Left L3-4	10	8.6
Right L5-S1	8	6.8
Left L5-S1	2	1.7
Right L2-3	2	1.7

Table 3. SF36 and Oswestry assessments.

	Preoperative	Postoperative 6 th month	<i>p</i>
	Mean ± SD	Mean ± SD	
SF36 PF	59.3±15.9	73.6±14	<0.001
SF36 RP	66.6±14.7	79.1±12.3	<0.001
SF36 BP	58.2±10	79.1±7.4	<0.001
SF36 GH	53.2±7.5	67.4±6.2	<0.001
SF36 VT	52.4±4.2	64.2±4.4	<0.001
SF36 SF	70.1±11	87.2±5.6	<0.001
SF36 RE	77.4±7.9	86.2±6.5	<0.001
SF36 MH	64.2±5.7	73.4±4.8	<0.001
OSWESTRY %	52.2±8.5	19.7±8.7	<0.001

Table 4. Radiographical measurements.

	Preoperative	Postoperative 6 th month	<i>p</i>
	Mean ± SD	Mean ± SD	
A-P Diameter (mm)	6.8±2.4	13±1.7	<0.001
Cross sectional Area (cm ²)	0.4±0.2	1.4±0.3	<0.001
Lateral Resses Height Ipsilateral (mm)	2.8±0.8	5±0.7	<0.001
Lateral Resses Height Contralateral (mm)	3.3±1.1	4.5±0.9	<0.001
Disc Anterior Height (mm)	9.2±2	9.6±2.2	<0.001
Disc Posterior Height (mm)	6.8±2.3	6.2±2.4	<0.001
Segmental Lordotic Angle (°)	14.9±7.1	20.5±8.6	<0.001

Table 5. VAS scores.

	Preoperative	Postoperative 1 st day	Postoperative 6 th month	<i>p</i> (preop-postop 1 st day)	<i>p</i> (postop 1 st day-postop 6 th month)
	Median (IQR)	Median (IQR)	Median (IQR)		
VAS	8 (8-9)	2.5 (2-3)	2 (1-3)	<0.001	0.172

Table 6. 15-minute Walking Test (SPWT).

	Preoperative	Postoperative 6 th month	<i>p</i>
	Mean ± SD	Mean ± SD	
Walking Distance (m)	361.9±219.3	1022.9±143.1	<0.001

Discussion

Many studies have shown that surgical treatment of DLSS is superior to conservative treatment in elderly patients [4]. Wide laminectomy and bilateral foraminotomy with undercutting of the medial facet joint is the most common procedure. However, this procedure can cause local tissue trauma and spinal instability [10]. Studies have demonstrated paraspinal muscle atrophy, chronic denervation, and electromyographic abnormalities of the paraspinal muscles after bilateral multifidus retraction [11]. The interspinous and supraspinous ligaments contribute to the resistance of lumbar flexion forces but traditional laminectomy techniques include excision of these ligaments as well as portions of the facet joints.

Many authors accept that the ULBD technique limits muscle retraction and preserves the soft tissues and facet joints, thus decreasing the need for fusion surgery [12, 13]. Oertel et al. [14] reported an 11.8% reoperation rate due to spinal instability after ULBD. Similarly, Yang et al. [15] reported that 9.5% of patients who underwent bilateral microdecompression by unilateral or bilateral laminotomy required reoperation for spinal instability. Katz et al. [16] reported a 23% reoperation rate after conventional laminectomy. However, Cavusoglu et al. [9] reported no reoperations due to spinal instability. In our study, 10% required a fusion reoperation due to spinal instability.

Wide laminectomy sufficiently increases the cross-sectional area of the spinal canal. Some studies have shown that clinical outcomes and cross-sectional area significantly improved after ULBD and laminectomy, however, the spinal canal enlargement did not correlate significantly with clinical improvement [17]. In our study, mean spinal canal diameter and cross-sectional area significantly increased by 6.2 mm and 1 cm², respectively. ULBD appears to achieve adequate decompression as well as satisfactory clinical outcomes.

The tubular approach, which minimizes tissue damage, is also increasingly being used in recent years. Like microscopic ULBD, the unilateral tubular approach for bilateral decompression provides satisfactory clinical and radiological improvement [18, 19].

However, complications may be more frequent as with other minimally invasive techniques due to the associated learning curve. Furthermore, the need for specialized surgical equipment may hinder generalized applicability of the tubular approach. Microscopic ULBD provides similar results without the need for specialized equipment.

Radiological examinations are important in the evaluation of surgical decompression for DLSS. Park et al. [20] reported a significant increase in the ipsilateral and contralateral lateral recess width after ULBD. Ryu et al. [21] reported no significant differences in mean segmental lumbar lordosis angle or anterior and posterior disc height after ULBD. We found that the mean lumbar lordosis angle increased by approximately 5° and the height of both lateral recesses increased significantly, especially on the operated side. In addition, the cross-sectional area and anterior-posterior diameter of the spinal canal increased by nearly 300% and 200%, respectively.

VAS, ODI, and SF36 provide information on pain, general health status, disability, quality of life, and physical and mental health. These data have been used to evaluate the clinical status of patients in many previous studies [9, 17, 18, 20, 22]. Although we found a significant decrease in postoperative day 1 VAS scores when compared to the preoperative period, the postoperative day 1 and 6-month postoperative scores were similar. The changes in all domains of the SF36 and ODI scales were statistically significant. Our results were similar to those of Demiral et al. [23], who reported mean SF36 scores of healthy people according to age groups in Turkey.

Perhaps the most important parameter in the clinical evaluation of DLSS patients is walking distance. Neurogenic claudication is usually progressive and causes serious disability and decreased health-related quality of life over time. Papavero et al. [13] used a treadmill test to evaluate walking performance, defined as walking distance × walking speed. However, the ability to walk at variable speeds during the test makes measurement difficult. Tomkins-Lane et al. [22] described two different variations of the SPWT to examine walking capacity in DLSS patients, a 15-minute version and a 30-minute version. Most of our patients could not complete

the 15-minute test before surgery so we used the 15-minute SPWT. Six months after surgery, walking distance was significantly greater.

One disadvantage of wide laminectomy is a relatively large postsurgical dead space, which is associated with risks of infection and increased blood loss [6, 24, 25]. Minimally invasive ULBD decreases these risks. In our study, only two wound infections occurred and 4 patients who underwent multilevel surgery required blood transfusion. Durotomy is another complication of spinal decompressive surgery. Reported durotomy rates are similar between laminectomy (5%, 15%), bilateral laminotomy (2%, 9%), and ULBD (3.5%, 12%) [19, 24, 25]. However, the risk of durotomy is greater in the tubular approach due to the learning curve [18]. In our study, the durotomy rate was 6.8% and 4 patients without neurologic deterioration required reoperation for dural repair.

This study is limited by its retrospective design and lack of a control group. Other limitations are its small sample size and relatively short follow-up. Future prospective studies with larger groups and longer follow-up are needed.

In conclusion, we demonstrated significant expansion of the cross-sectional area of the spinal canal and improvement of clinical and radiological outcomes with minimal soft tissue damage after ULBD in patients with DLSS. Walking performance and health-related quality of life also improved. We think it is important to evaluate walking capacity in the follow-up of DLSS patients. In accordance with the current general trend towards minimally invasive surgery, the ULBD technique may be a good choice for elderly DLSS patients.

Conflict of interest: No conflict of interest was declared by the authors.

References

1. Mobbs RJ, Li J, Sivabalan P, Raley D, Rao PJ. Outcomes after decompressive laminectomy for lumbar spinal stenosis: comparison between minimally invasive unilateral laminectomy for bilateral decompression and open laminectomy: clinical article. *J Neurosurg Spine* 2014;21:179-186. <https://doi.org/10.3171/2014.4.SPINE13420>
2. Ozdogan S, Yaltirik CK, Yilmaz SG, Kocak A, Isbir T. Association of rs2228570 polymorphism of vitamin D receptor gene with lumbar degenerative disc disease. *Turk Neurosurg* 2019;29:159-163. <https://doi.org/10.5137/1019-5149.JTN.22275-17.2>
3. Reyes-Sánchez A, García-Ramos CL, Deras-Barrientos CM, Alpizar-Aguirre A, Rosales-Olivarez LM, Pichardo-Bahena R. Ligamentum flavum in lumbar spinal stenosis, disc herniation and degenerative spondylolisthesis. An histopathological description. *Acta Ortop Mex* 2019;33:308-313.
4. Chang Y, Singer DE, Wu YA, Keller RB, Atlas SJ. The effect of surgical and nonsurgical treatment on longitudinal outcomes of lumbar spinal stenosis over 10 years. *J Am Geriatr Soc* 2005;53:785-792. <https://doi.org/10.1111/j.1532-5415.2005.53254.x>
5. Ozdogan S, Yaltirik CK, Atalay B, Tiryaki M, Duzkalir AH, Suslu H. Unilateral approach for bilateral spinal microdecompression in lumbar spinal stenosis: short term results. *JTSS* 2015;26:205-209.
6. Yaman O, Ozdemir N, Dagli AT, Acar E, Dalbayrak S, Temiz C. A comparison of bilateral decompression via unilateral approach and classic laminectomy in patients with lumbar spinal stenosis: a retrospective clinical study. *Turk Neurosurg* 2015;25:239-245. <https://doi.org/10.5137/1019-5149.JTN.8710-13.1>
7. Usman M, Ali M, Khanzada K, et al. Unilateral approach for bilateral decompression of lumbar spinal stenosis: a minimal invasive surgery. *J Coll Physicians Surg Pak* 2013;23:852-856.
8. Toyoda H, Nakamura H, Konishi S, Dohzono S, Kato M, Matsuda H. Clinical outcome of microsurgical bilateral decompression via unilateral approach for lumbar canal stenosis: minimum five-year follow-up. *Spine* 2011;36:410-415. <https://doi.org/10.1097/BRS.0b013e3181d25829>
9. Cavuşoğlu H, Kaya RA, Turkmenoglu ON, Tuncer C, Colak I, Aydin Y. Midterm outcome after unilateral approach for bilateral decompression of lumbar spinal stenosis: 5-year prospective study. *Eur Spine J* 2007;16:2133-2142. <https://doi.org/10.1007/s00586-007-0471-2>
10. Nori S, Shiraiishi T, Aoyama R, et al. Narrow width of muscle-preserving selective laminectomy demonstrated sufficient surgical outcomes and reduced surgical invasiveness. *J Clin Neurosci* 2018;52:60-65. <https://doi.org/10.1016/j.jocn.2018.03.007>
11. See DH, Kraft GH. Electromyography in paraspinal muscles following surgery for root compression. *Arch Phys Med Rehabil* 1975;56:80-83.
12. Borshchenko I, Gulzatyan A, Kartavykh R, Grin A. How I do it: bilateral lumbar spinal canal microsurgical decompression via unilateral approach. *Acta Neurochir (Wien)* 2019;161:2375-2380. <https://doi.org/10.1007/s00701-019-04059-0>

13. Papaverio L, Thiel M, Fritzsche E, Kunze C, Westphal M, Kothe R. Lumbar spinal stenosis: prognostic factors for bilateral microsurgical decompression using a unilateral approach. *Neurosurgery* 2009;65:182-187. <https://doi.org/10.1227/01.NEU.0000341906.65696.08>
14. Oertel MF, Ryang YM, Korinith MC, Gilsbach JM, Rohde V. Long-term results of microsurgical treatment of lumbar spinal stenosis by unilateral laminotomy for bilateral decompression. *Neurosurgery* 2006;59:1264-1269. <https://doi.org/10.1227/01.NEU.0000245616.32226.58>
15. Yang SM, Park HK, Chang JC, Kim RS, Park SQ, Cho SJ. Minimum 3-year outcomes in patients with lumbar spinal stenosis after bilateral microdecompression by unilateral or bilateral laminotomy. *J Korean Neurosurg Soc* 2013;54:194-200. <https://doi.org/10.3340/jkns.2013.54.3.194>
16. Katz JN, Lipson SJ, Chang LC, Levine SA, Fossel AH, Liang MH. Seven- to 10-year outcome of decompressive surgery for degenerative lumbar spinal stenosis. *Spine* 1996;21:92-98. <https://doi.org/10.1097/00007632-199601010-00022>
17. Chung SW, Kang MS, Shin YH, Baek OK, Lee SH. Postoperative expansion of dural sac cross-sectional area after unilateral laminotomy for bilateral decompression: correlation with clinical symptoms. *Korean J Spine* 2014;11:227-231. <https://doi.org/10.14245/kjs.2014.11.4.227>
18. Alimi M, Hofstetter CP, Torres-Campa JM, et al. Unilateral tubular approach for bilateral laminotomy: effect on ipsilateral and contralateral buttock and leg pain. *Eur Spine J* 2017;26:389-396. <https://doi.org/10.1007/s00586-016-4594-1>
19. Kim HS, Patel R, Paudel B, et al. Early outcomes of endoscopic contralateral foraminal and lateral recess decompression via an interlaminar approach in patients with unilateral radiculopathy from unilateral foraminal stenosis. *World Neurosurg* 2017;108:763-773. <https://doi.org/10.1016/j.wneu.2017.09.018>
20. Park WB, Hong JT, Lee SW, Sung JH, Yang SH, Kim IS. Clinical and radiological comparison between ipsilateral and contralateral side canal decompression using an unilateral laminotomy approach. *Korean J Spine* 2016;13:41-46. <https://doi.org/10.14245/kjs.2016.13.2.41>
21. Ryu SJ, Kim IS. Interspinous implant with unilateral laminotomy for bilateral decompression of degenerative lumbar spinal stenosis in elderly patients. *J Korean Neurosurg Soc* 2010;47:338-344. <https://doi.org/10.3340/jkns.2010.47.5.338>
22. Tomkins-Lane CC, Conway J, Hepler C, Haig AJ. Changes in objectively measured physical activity (performance) after epidural steroid injection for lumbar spinal stenosis. *Arch Phys Med Rehabil* 2012;93:2008-2014. <https://doi.org/10.1016/j.apmr.2012.05.014>
23. Demiral Y, Ergor G, Unal B, et al. Normative data and discriminative properties of short form 36 (SF-36) in Turkish urban population. *BMC Public Health* 2006;6:247. <https://doi.org/10.1186/1471-2458-6-247>
24. Schatlo B, Horanin M, Hernandez-Durán S, Solomiychuk V, Rohde V. Shape of the spinal canal is not associated with success rates of microsurgical unilateral laminotomy and bilateral decompression for lumbar spinal canal stenosis. *World Neurosurg* 2018;116:42-47. <https://doi.org/10.1016/j.wneu.2018.03.137>
25. Thome C, Zevgaridis D, Leheta O, et al. Outcome after less-invasive decompression of lumbar spinal stenosis: a randomized comparison of unilateral laminotomy, bilateral laminotomy, and laminectomy. *J Neurosurg Spine* 2005;3:129-141. <https://doi.org/10.3171/spi.2005.3.2.0129>

Ethics approval: Adana City Education and Research Hospital, Clinical Research Ethics Committee of Adana City Education and Research Hospital, Approval Date: 25.03.2020, Approval no:765.