

RESEARCH
ARTICLEHacı Koc¹¹Private Adatip Hospital,
Sakarya, Turkey**Corresponding Author:***Hacı Koç*
Private Adatip Hospital, Sakarya,
Turkey
mail: hacikoc@gmail.com
Phone: +90 5325170751Received: 02.10.2019
Acceptance: 22-05-2020
DOI: 10.18521/kt.628561**Konuralp Medical Journal**
e-ISSN1309-3878
konuralptipdergi@duzce.edu.tr
konuralptipdergisi@gmail.com
www.konuralptipdergi.duzce.edu.tr**Pars Plana Vitrectomy Results in Proliferative Vitreoretinopathies****ABSTRACT****Objective:** This study was carried out in order to evaluate the clinical features, surgical treatment results and complications encountered in patients who underwent pars plana vitrectomy due to PVR in our clinic.**Methods:** Forty-eight eyes of 47 patients who underwent pars plana vitrectomy for PVR were included in the study. Pars plana vitrectomy was applied to both eyes of one of these cases due to PVR. 29 (61.7%) of the cases were male and 18 (38.2%) were female. Routine ophthalmologic examination was performed to all patients. All operations were performed by the same surgeon.**Results:** Forty-eight eyes of 47 patients with various levels of PVR underwent pars plana vitrectomy. 29 eyes (60.41%) underwent once pars plana vitrectomy, 18 eyes (37.5%) underwent 2 times pars plana vitrectomy and 1 eye (2.08%) underwent 3 times pars plana vitrectomy. In the postoperative period, the patients were followed up between 2 months and 16 months (mean 6.6 months). At the end of the follow-up period, our anatomic success rate was 81.25% and total retinal attachment was achieved in 39 eyes. Retinal detachment was observed in 4 eyes (8.33%) anterior of scleral buckling, while posterior pole was attached. In 5 eyes (10.41%) retinal attachment could not be achieved and 3 of these eyes (6.25%) developed phthisis.**Conclusions:** Vitreoretinal surgery can provide anatomical and functional success in eyes with rhegmatogenous retinal detachment and PVR. This success rate has increased especially in recent years with the use of gas and silicone oil as intraocular tamponade, intraoperative use of perfluorocarbon fluids, introduction of wide angle vision systems and advances in surgical techniques.**Keywords:** Pars Plana Vitrectomy, Proliferative Vitreoretinopathy, Retinal Detachment**Proliferatif Vitreoretinopatilerde Pars Plana Vitrektomi Sonuçlarımız****ÖZET****Amaç:** Kliniğimizde PVR nedeniyle pars plana vitrektomi uyguladığımız olguların klinik özelliklerini, cerrahi tedavi sonuçlarını ve karşılaşılan komplikasyonları değerlendirmek amacıyla bu çalışma yapıldı.**Gereç ve Yöntem:** Proliferatif vitreoretinopati sebebiyle pars plana vitrektomi cerrahisi uygulanan 47 olgunun 48 gözü çalışma kapsamına alınmıştır. Bu olgulardan bir tanesinin iki gözüne de PVR nedeniyle pars plana vitrektomi uygulanmıştı. Olguların 29'u (%61.7) erkek, 18'i (%38.2) kadındı. Çalışmaya dahil edilen olgulara rutin oftalmolojik muayene yapıldı. 32 (%68) olguya genel anestezi, 15 (%32) olguya da lokal anestezi altında pars plana vitrektomi cerrahisi uygulandı. Tüm operasyonlar aynı cerrah tarafından yapıldı.**Bulgular:** Çeşitli düzeylerde PVR'ı olan 47 olgunun 48 gözüne pars plana vitrektomi cerrahisi uygulandı. 29 göze (%60.41) 1 kez pars plana vitrektomi, 18 göze (%37.5) 2 kez pars plana vitrektomi ve 1 göze (%2.08) de 3 kez pars plana vitrektomi cerrahisi uygulandı. Postoperatif dönemde olgular 2 ay ile 16 ay arasında takip edildiler (ortalama 6.6 ay). Takip sürelerinin sonunda elde edilen anatomik başarı oranımız %81.25 olup, 39 gözde total retinal yatışma sağlanmıştır. 4 gözde (%8.33) skleral çökertme önünde retina dekolman, arka kutup yatışık olarak izlenmiştir. 5 gözde (%10.41) ise retinal yatışma sağlanamamış ve bu gözlerden 3 tanesinde (%6.25) ftizis gelişmiştir.**Sonuç:** Regmatojen retina dekolmanı ve PVR' si olan gözlerde vitreoretinal cerrahi ile anatomik ve fonksiyonel başarı sağlanabilmektedir. Özellikle son yıllarda intraoküler tamponad olarak gaz ve silikon yağının kullanılması, perflorokarbon sıvılarının intraoperatif kullanılması, geniş açılı görüş sistemlerinin devreye sokulması ve cerrahi tekniklerdeki gelişmelerle bu başarı oranı artış göstermiştir.**Anahtar Kelimeler:** Pars Plana Vitrektomi, Proliferatif Vitreoretinopati, Retina Dekolmanı.

INTRODUCTION

PVR is characterized by cell proliferation in the vitreous and membrane formation on both surfaces of the retina. It occurs after prolonged retinal detachments and after detachment surgery. Contraction of these fibroproliferative membranes leads to a series of clinical changes ranging from decreased retinal and vitreous mobility to the formation of radial and circular folds (1).

Contraction of these membranes resulting from PVR causes to retinal traction. Retinal traction also leads to re-opening of previously successfully attached tears or the formation of new tears. Thus, recurrent retinal detachment, macular pucker and macular distortion may occur(2).

The presence of clinical features of PVR was known many years ago and was called massive periretinal proliferation and massive vitreous retraction before taking its current name(3-8). In the last 20 years, significant progress has been made in understanding and treating the pathogenesis of PVR (9). Today, successful results are obtained in the treatment of PVR with pars plana vitrectomy surgery.

In this study, we evaluated the clinical features, surgical treatment results and complications of patients who underwent pars plana vitrectomy for PVR in our clinic.

MATERIAL AND METHODS

Forty-eight eyes of 47 patients who underwent pars plana vitrectomy for proliferative vitreoretinopathy between March 1998 and April 2001 in SSK Istanbul Educational Hospital Eye Clinic were included in this retrospective study. Twenty-nine (61.7%) of the cases were male and 18 (38.2%) were female.

The ages ranged from 15 to 73 years (mean 50.1 years). The most frequent age group was 41-60 years. The patients were followed for a mean of 6.6 months between 2 months and 16 months.

The cases we included in the study were routinely: visual acuity examination, intraocular pressure measurement (with applanation tonometer), biomicroscopic anterior segment examination, biomicroscopic and indirect ophthalmoscopic fundus examinations and ultrasonography were performed in cases where the posterior segment could not be viewed

Thirty two patients (68%) underwent pars plana vitrectomy under general anesthesia and 15 patients (32%) under local anesthesia. All operations were performed by the same surgeon.

RESULTS

Preoperative visual acuity of the patients included in our study ranged from light sensation to 0.1 (Figure 1). Preoperative visual acuity of 44 eyes was light sensation.

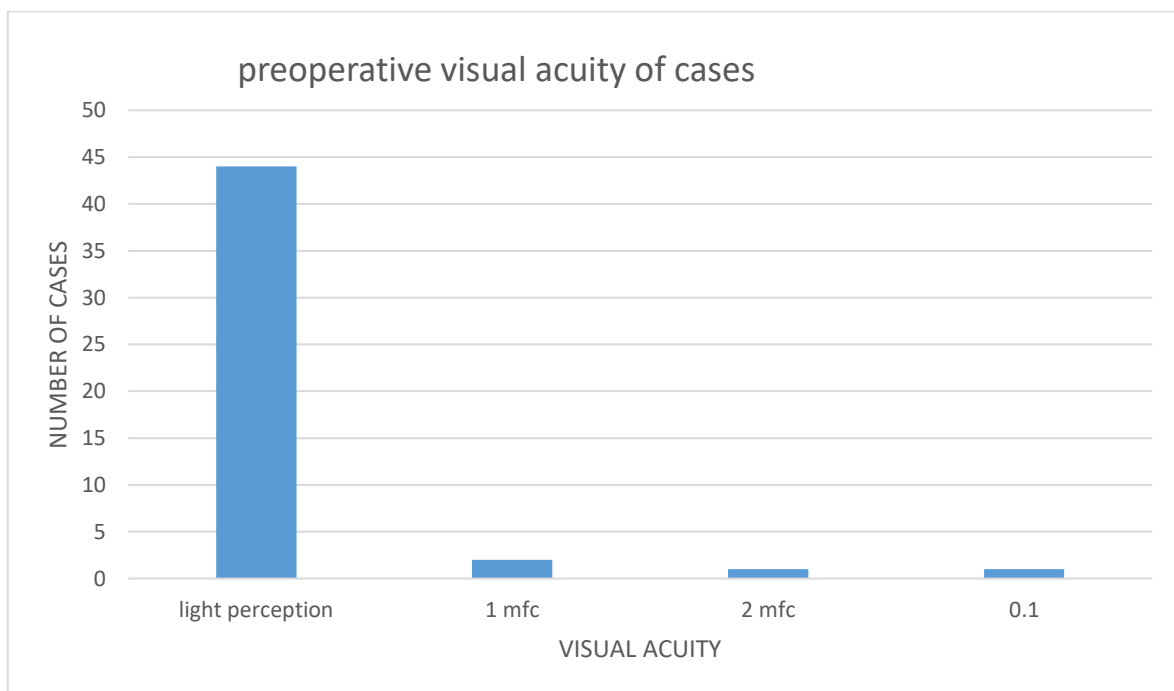


Figure 1. Preoperative visual acuity of patients; mfc: Finger count from 1 m

When the cases were analysed in terms of etiologic factors of PVR, the most common causes were trauma, previous detachment and cataract surgery (Table 1). Five eyes of 22 eyes were aphakic and 6 were pseudophakic. Four aphakic

eyes and two pseudophakic eyes had previously undergone pars plana vitrectomy surgery in other centers. There were no etiologic factors in 10 eyes (20.83%) with retinal detachment and PVR.

Table 1. Etiological factors.

Etiological factors	Number	percent(%)
Trauma	9	18.75
Pseudophakic	13	27.08
Aphakic	13	27.08
Previously performed retinal detachment surgery	22	45.83
Previously performed vitrectomy surgery	6	12.5
Giant tear	1	2.08
High myopia	2	4.16
Marfan syndrome	1	2.08
Stickler syndrome	1	2.08
Unknown	4	8.33

Preoperative PVR levels of the eyes included in our study ranged from C1 to D3 according to the 1983 Retinal Society PVR Classification System. Stage DI PVR was the most common preoperative PVR level with 41.66%.

Forty-eight eyes of 47 patients with various levels of PVR underwent pars plana vitrectomy. 29 eyes (60.41%) underwent ones pars plana vitrectomy, 18 eyes (37.5%) underwent 2 times pars plana vitrectomy and 1 eye (2.08%) underwent 3 times pars plana vitrectomy. The silicone oil was removed from the 13 eyes (27.08%) who underwent surgery once, and 6 eyes (12.5%) underwent 2 surgeries, postoperative 3rd-6th month. 6 eyes (12.5%) had undergone pars plana vitrectomy in other centers before and retinal sedation could not be achieved.

In the postoperative period, the patients were followed up between 2 months and 16 months

(mean 6.6 months). A completely attached retina with clear illumination at the last follow-up was defined as anatomical success. The increase in preoperative visual acuity was accepted as functional success. At the end of the follow-up period, our anatomic success rate was 81.25% and total retinal attachment was achieved in 39 eyes. Retinal detachment was observed in 4 eyes (8.33%) anterior of scleral buckling, while posterior pole was attached. In 5 eyes (10.41%) retinal attachment could not be achieved and 3 of these eyes (6.25%) developed phthisis.

Silicone oil was used in 37 eyes (77.08%) and C3F8 was used in 10 eyes (20.83%) as intraocular tamponade. Because of massive suprachoroidal hemorrhage developed in one eye (2.08%) during the operation, the operation was terminated without intraocular tamponade. In 20 eyes (54.05%) we achieved silicone oil, and in 1 eye (2.70%) retinal attachment posterior of scleral buckling was achieved. Recurrent retinal detachment and PVR developed in 16 eyes (43.24%). One eye (2.70%) with silicone oil was treated with retinal detachment and retinal detachment developed after silicone removal. In 6 eyes (60%) we used C3F8 and in 3 eyes (30%) retinal attachment posterior of scleral buckling was achieved. Recurrent retinal detachment and PVR developed in 1 (10%) of the eyes given C3F8.

Visual acuity increased in 36 eyes (75%), visual acuity remained unchanged in 5 eyes (10.41%) and decreased in 7 eyes (14.58%). A total of 37 eyes (77.03%) had visual acuity of finger counting and over, and 30 (62.91%) of them had visual acuity counting from 1 meter and above. Postoperative visual acuity levels of the eyes included in our study are shown in Figure 2.

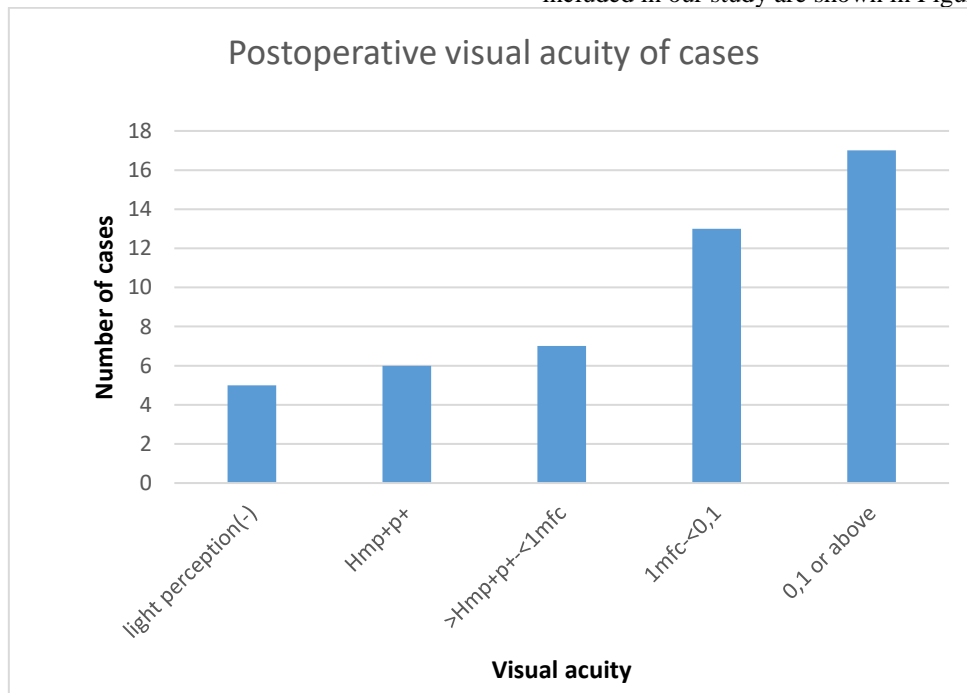


Figure 2. Postoperative visual acuity of cases; Hmp+pt+: Hand movement, 1mfc: Finger count from 1 m

Complications related to pars plana vitrectomy are shown in Table 2.

Table 2. Intraoperative and postoperative complications

Intraoperatively		
Complication	Eye number	Percent(%)
Corneal edema	23	47.91
Vitreous haemorrhage	8	16.66
Miosis	3	6.25
Iatrogenic retinal tear	3	6.25
Retinal incarceration from sclerotomy	1	2.08
Silicon penetration to subretinal region	1	2.08
Massive suprachoroidal haemorrhage	1	2.08
Upper temporal translocation of the macula	1	2.08
Iatrogenic lens trauma	1	2.08
Early postoperative period		
Intraocular pressure increase	8	16.66
Corneal edema	6	12.25
Hypotonia	4	8.33
Intraocular inflammation	3	6.25
Silicon penetration to anterior chamber	2	4.16
Hyphema	1	2.08
Choroidal detachment	1	2.08
Late postoperative period		
Recurran retinal detachment+PVR	19	39.58
Macular pucker	6	12.5
Cataract	5	10.41
Hypotonia	4	8.33
Intraocular pressure increase	3	6.25
Phytisis	3	6.25
Retinal detachment after silicone remove	2	4.16
Perisilicon proliferation	2	4.16
Silicon keratopathy	1	2.08
Optical atrophy	1	2.08

DISCUSSION

In our study, the anatomic success rate obtained at the end of the follow-up period was 81.25%, and total retinal attachment was achieved in 39 eyes. Retinal detachment was observed in 4 eyes (8.33%) anterior of scleral buckling, while posterior pole was attached. In 5 eyes (10.41%) retinal attachment could not be achieved and 3 of these eyes (6.25%) developed phthisis. Visual acuity improved in 36 eyes (75%), visual acuity remained unchanged in 5 eyes (10.41%) and decreased in 7 eyes (14.58%). A total of 37 eyes (77.03%) had finger counts and visual acuities, and 30 of them (62.91%) had visual acuities of 1 meter and above. Although there are differences between the success rates of the studies, success rates in the

treatment of PVR have generally increased in parallel with the developments in surgical techniques. Even if some eyes require more than one surgical intervention due to reproliferation and recurrent retinal detachment, retinal detachment can be achieved successfully in most eyes with retinal detachment resulting from PVR (9).

Lewis and colleagues achieved significant degrees of anatomical and functional success following vitrectomy in eyes with retinal detachment resulting from PVR. They achieved 90% of total retinal attachment and 94% of retinal attachment posterior of scleral buckling. They achieved visual acuity of at least 5/200 in 85% of eyes with total retinal attachment. They did not achieve same success for eyes with recurrence PVR who previously underwent vitrectomy for PVR. In these eyes, 73% of the total retinal attachment and 86% of retinal attachment posterior of scleral buckling were achieved. They achieved 67% of visual acuity 5/200 and above in these eyes with total retinal attachment(10).

In studies performed in Turkey in anatomic success was achieved between 57-80% (11,12). In a series of 26 cases, Karacorlu reported 80% anatomical and 80% functional success (11). Eldem reported 71% anatomical success and 39% functional success (13).

The most important reason of vitreoretinal surgery failure in eyes with PVR is the presence of anterior PVR in the preoperative period, the development of anterior PVR in the postoperative period, or the continuation of pre-existing anterior PVR. Diffuse anterior PVR is also the most important cause of chronic hypotonia (14, 15, 16). Therefore, the elimination of anterior PVR is of great importance. In eyes with PVR, scleral indentation is required in order to effectively clean the vitreous base, peripheral vitreous and anterior proliferative tissue. For this, it may be necessary to remove the crystalline and intraocular lens (17). We removed the crystalline or intraocular lens from 27 pseudophakic or phakic eyes (56.25%) to clean the vitreous base, peripheral vitreous and anterior proliferative tissue.

In complicated retinal detachment surgery, the buffer effect of gases used as intraocular tamponade is more than silicone and no second operation is required to remove the gases (18,19). Unlike gases, silicone is a stabilizer that can keep the eye at the same intraocular pressure. However, in order to maintain this effect, the retina must be free from all traction during the operation (19). The silicone has optical clarity, hemostatic effects and minimal refractive effects, allowing visual rehabilitation to be rapid. This allows easy selection of fundus details and easy application of intraoperative and postoperative laser. In addition, due to the mechanical effect of silicone can slow the spread of detachment, confine the detachment (20).

In our study, we used silicone oil in 37 eyes (77.08%) and C3F8 in 10 eyes (20.83%) as intraocular tamponade. We could not give intraocular tamponade because of massive suprachoroidal hemorrhage developed in one eye (2.08%). We achieved retinal attachment in 20 eyes (54.05%) used silicone oil, and in 1 eye (2.70%) with silicone oil retinal attachment posterior of scleral buckling was achieved. Recurrent retinal detachment and PVR developed in 16 eyes (43.24%). One eye (2.70%) with silicone oil was treated with retinal detachment and retinal detachment developed after silicone removal. Total retinal attachment was achieved in 6 eyes (60%) with C3F8 In 6 eyes (60%) and retinal attachment posterior to scleral buckling was achieved in 3 eyes (30%) with C3F8. Recurrent retinal detachment and PVR developed in 1 (10%) of the eyes given C3F8. We found a higher rate of both anatomical and functional success in eyes with C3F8 as intraocular tamponade. However, we think that using silicone oil in more eyes compared to C3F8 and preferring silicone oil in cases with high PVR stage have an effect on these results.

CONCLUSION

Anatomical and functional success can be achieved with vitreoretinal surgery in eyes with rhegmatogenous retinal detachment and PVR. This success rate has increased especially in recent years with the use of gas and silicone oil as intraocular

tamponade, intraoperative use of perfluorocarbon fluids, introduction of wide angle vision systems and advances in surgical techniques.

Despite these advances in PVR surgery, success rates are not 100%. The most important reason for this is the continuation of the PVR process, which leads to recurrent retinal detachment and reduced functional success. Anterior and posterior membranes should be completely removed to stop the PVR process.

Although silicone oil and gases used as intraocular tamponade can achieve successful results, they do not have ideal tamponade properties because both have various disadvantages. However, silicone oil should be preferred in eyes more than one operated and prone to hypotonia because it has stabilizing and also has prevents phytosis and hypotonia as well as intravitreal tamponade.

Functional and anatomical success will be achieved when the ideal tamponade can be used in PVR surgery and pharmacological agents are used to prevent recurrent epiretinal proliferation, which is the most important complication of PVR surgery.

ACKNOWLEDGEMENTS

I would like to thank associate professor doctor Kadir Eltutar and professor doctor Ziya Kapran for their great contribution in this study.

DECLARATIONS

There are no conflicts of interest to declare.

REFERENCES

1. Peyman GA, Schulman JA. Intraocular surgery. 2nd edition. Connecticut. Appleton and Lange. Proliferative vitreoretinopathy. 1994; Chapter 13: 587-629.
2. Lean SJ. Proliferative vitreoretinopathy. In: Albert DM, Jakobiec FA, eds. Principles and Practise of Ophthalmology. WB Saunders Company. 1994; 1110-21.
3. The Retina Society Terminology Committee: The classification of retinal detachment with proliferative vitreoretinopathy. Ophthalmology. 1983; 90: 121-25.
4. Scott JD. Treatment of massive vitreous retraction. Trans Ophthalmol Soc UK. 1975; 95: 429-432.
5. Havener WH. Massive vitreous retraction. Int Ophthalmol Clin. 1976; 16: 135-55.
6. Hruby K. Massive vitreous retraction. Doc Ophthalmol. 1969; 26: 555-565.
7. Scott JD. The treatment of massive vitreous retraction by the separation of pre-retinal membranes using liquid silicone. Mod Probl Ophthalmol. 1975; 15: 285-90.
8. Havener WH. Massive vitreous retraction. Ophthalmic Surg. 1973; 4(2): 22-67.
9. Thompson JT. Proliferative vitreoretinopathy. In: Ryan SJ and Wilkinson CP, eds. 3rd ed. Retina. Vol. 3. Chapter 138, Mosby Company, 2001; 2287-2316.
10. Lewis H, Aaberg TM, Abrams GW. Causes of failure after initial vitreoretinal surgery for severe proliferative vitreoretinopathy. Am J Ophthalmol. 1991; 111: 8-14.
11. Karaçorlu M, Aktunç T, Üstüner A. Komplike retina dekolmanı olgularında pars plana vitrektomi. TOD XXIV. Ulus Kong Bülteni. 1990; Ankara; Cilt 1: 119-23.
12. Hasanreisioğlu B, Aksünger A, Or M ve ark. afak retina dekolmanlarıklinik özellikleri ile anatomik ve görsel sonuçlar. Retina- Vitreus. 1996; 1: 475-81.
13. Eldem B, Oruç S. Pars plana vitrektomi sonuçları. XXVII. Ulus Kong Bülteni. 1994; İzmir; Cilt 2: 1117-23.
14. Özmert E. Dev yırtıklı retina dekolmanı ve cerrahi tedavisi. Retina-Vitreus. 1995; 3: 254-57.
15. Chang S, Özmert E, Zimmerman NJ, et al. Intraoperative perfluorocarbon liquids in the management of proliferative vitreoretinopathy. Am J Ophthalmol. 1988; 106: 668-74.
16. Abrams GW. Retinotomies and retinectomies. In: Ryan SJ ed. Retina. Mosby Company. St. Louis. 1989; Vol 3; Chap 131; 317-46.
17. Zivonjovic R. Surgical principles in silicone oil in vitreoretinal surgery. Nijhoff and Junk Pub. Dordrecht. 1987; 9-22.

18. Erkam N. Vitreoretinal cerrahide göz içi tampon maddeler. Medical Network Oftalmoloji. 1994; 2: 140-44.
19. Lewis H, Verdauger JT. Surgical management for chronic hypotony and anterior proliferative vitreoretinopathy. Am J Ophthalmol. 1996; 122: 228-35.
20. Montanari P, Troiano P, Marangoni P, Pinotti D, Ratigli R, Miglior M. Glaucoma after vitreo-retinal surgery with silicon oil injection; epidemiologic aspects. Int Ophthalmol. 1997; 20: 29-31.