

Perineal Hernia Causing Intestinal Obstruction After Abdominoperineal Resection and Permanent Colostomy

Afak Durur Karakaya^{1*}, Derya Salim Uymaz², Emre Altınmakas¹, Emre Balık²,
Bengi Gürses¹

¹ Department of Radiology, Faculty of Medicine, Koc University, İstanbul, Turkey

² Department of General Surgery, Faculty of Medicine, Koc University, İstanbul, Turkey

Article History

Received 23 May 2020

Accepted 06 June 2020

Published Online 15 June 2020

*Corresponding Author

Afak Durur Karakaya
Department of Radiology

Faculty of Medicine

Koc University

İstanbul, Turkey

Phone: +905337111996

E-mail: afkarakaya@kuh.ku.edu.tr

ORCID: <http://orcid.org/0000-0003-3604-6791>

Abstract: Internal hernia is a rare condition. It has different etiology according to the anatomical region encountered. In this paper we present a case of intestinal obstruction due to herniation of the small intestine to the perineal area after permanent colostomy with resection of the abdominoperineal colon, rectum and anus. © 2020 NTMS.

Keywords: Perineal Hernia.

1. Introduction

Perineal hernia (PH) is defined as protrusion of intraabdominal structures through a pelvic floor defect into the perineum. Small intestines, colon, bladder, omentum, and uterus can be involved (1,2). It is a rare complication of some surgeries including abdominoperineal resection, pelvic exenteration, and prostatectomy (3-6) and usually occurs within 4-12 weeks following operation. Minimally invasive methods are used for treatment.

2. Material and Methods

2.1. Case

A 46-year-old male patient underwent robotic abdominoperineal resection and permanent colostomy for locally advanced rectal cancer. On postoperative 6th day, he developed lack of bowel sounds, abdominal distension, and pain.

Computerized tomography (CT) of abdomen with intravenous (IV) and oral contrast material was performed for further assessment. CT showed herniation of the small bowel loops through a posterior pelvic floor defect into the perineum. Small bowel loops were diffusely dilated, and passage of oral contrast media was prolonged. Thickening of the hernia wall and increased enhancement were also noted (Figure 1a, 1b and 2). Subsequently, the patient underwent surgery which confirmed the diagnosis (Figure 3).

3. Discussion

Perineal hernia is a rare complication of major pelvic surgeries. The incidence of post-pelvic surgery is 7%, whereas the need for additional surgery is 0.2-0.6% (7-9). It has been attributed to weakness of levator muscle in pelvic floor.

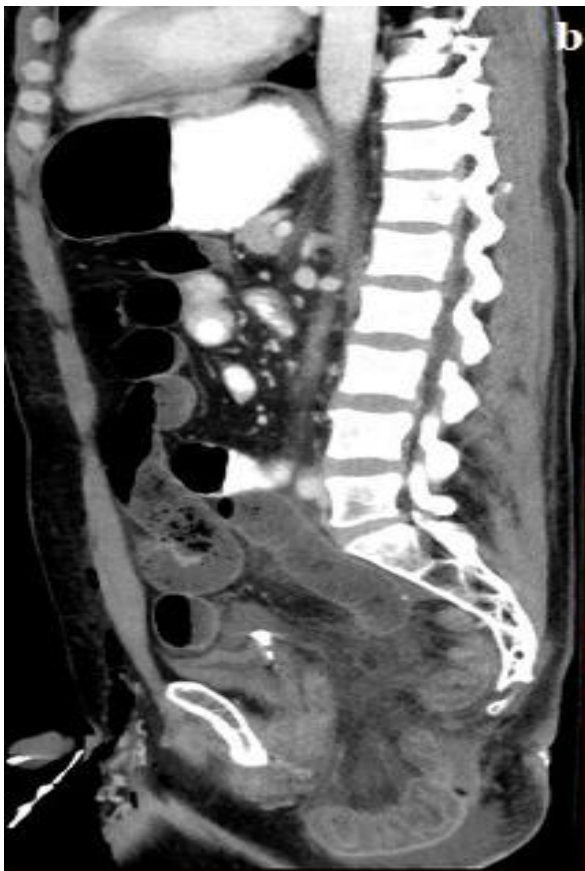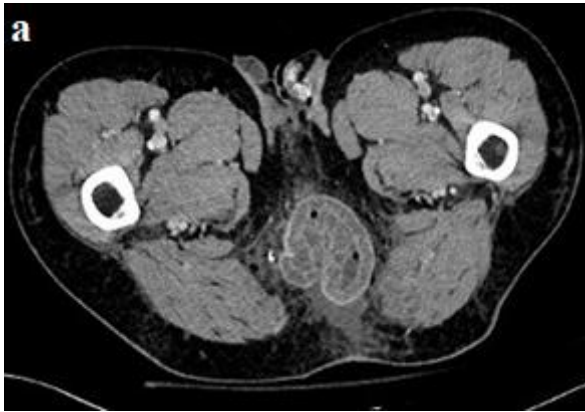


Figure 1a-b: Axial and coronal images of contrast-enhanced CT of abdomen shows herniation of the small bowel loops through a defect in the posterior pelvic floor into the perineum with thickening and increased enhancement of the hernia wall.

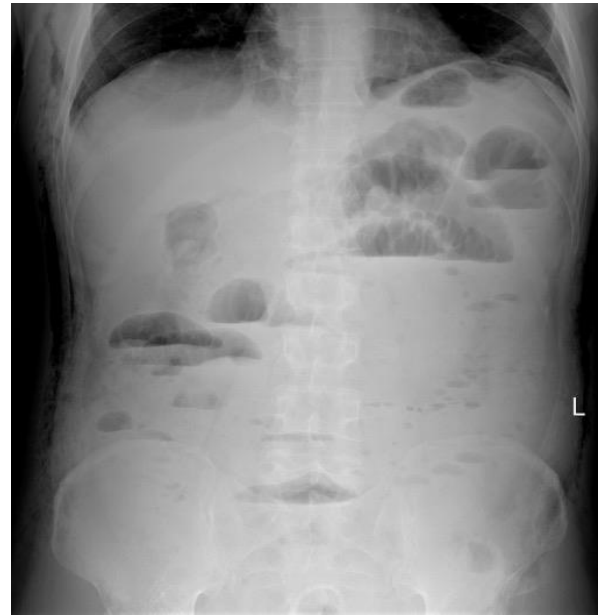

Figure 2: Dilatation of small bowel loops with air-liquid levels.

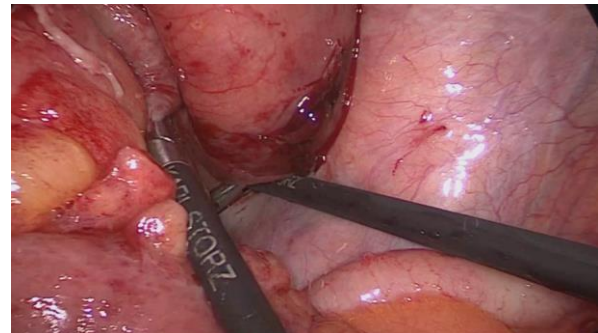


Figure 3: Herniated intestinal loops on laparoscopic images.

It has been reported that PH usually occurs within 4-12 weeks following surgery with no clinical symptoms. In our case, it developed on 6th day of the operation with symptoms of bowel obstruction. This condition can be repaired laparoscopically with transabdominal, perineal or combined abdominoperineal approach when necessary.

4. Conclusion

In our case, diagnostic laparoscopy was performed, and herniated bowel loops were reduced. In conclusion, diagnosis of PH should be considered in patients who are in early or late postoperative period of a major abdominopelvic surgery.

Conflict of interest statement

No conflict of interest.

References

1. Melich G, Lim DR, Hur H, Min BS, Baik SH, Arena GO, Gordon PH, Kim NK. Prevention of perineal hernia after laparoscopic and robotic abdominoperineal resection: review with illustrative case series of internal hernia through pelvic mesh. *Can J Surg* **2016**; 59(1): 54-58.
2. Maurissen J, Schoneveld M, Van Eetvelde E, Allaeyns M. Robotic-assisted repair of perineal hernia after extralevator abdominoperineal resection. *Tech Coloproctol* **2019**; 23(5): 479-482.
3. Skipworth RJE, Smith GHM, Anderson DN. Secondary perineal hernia following open abdominoperineal excision of the rectum: report of a case and review of the literature. *Hernia* **2007**; 11: 541-545.
4. Rayhanabad J, Sassani P, Abbas MA. Laparoscopic repair of perineal hernia. *JLS* **2009**; 13: 237-241.
5. Stephen R, Kavanagh DO, Neary PC. Laparoscopic repair of post-operative perineal hernia. *Case Rep Med* **2010**; 10: 1155.
6. Dulucq JL, Wintringer P, Mahajna A. Laparoscopic repair of post-operative perineal hernia. *Surg Endosc* **2006**; 20: 414-418.
7. George 10 So JB, Palmer MT, Shellito PC. Postoperative perineal hernia. *Dis Colon Rectum* **1997**; 40: 954-957.
8. Aboian E, Winter DC, Metcalf DR, et al. Perineal hernia after proctectomy: prevalence, risks, and management. *Dis Colon Rectum*. **2006**; 49: 1564-1568.
9. Yokoyama Y, Kawai K, Kazama S, et al. A case of extraperitoneal stoma-associated internal hernia after abdominoperineal resection. *World J Surg Oncol* **2014**; 6; 12: 141.

Authors' ORCID

Afak Durur Karakaya

<http://orcid.org/0000-0003-3604-6791>

Derya Salim Uymaz

<http://orcid.org/0000-0002-2590-5872>

Emre Altınmakas

<http://orcid.org/0000-0002-0727-9230>

Emre Balık

<http://orcid.org/0000-0001-5751-1133>

Bengi Gürses

<http://orcid.org/0000-0002-2482-3445>



<https://dergipark.org.tr/tr/pub/ntms>

All Rights Reserved. © 2020 NTMS.