

Veziko-Üreteral Reflü Hastalığında Ultrasonun Rolünü Nasıl Belirleyebiliriz?

How Can We Specify The Role of Ultrasonography in the Vesico – Ureteral Reflux Disease?

Gulsah BAYRAM ILIKAN

Ankara City Hospital, Children's Hospital, Department of Radiology, Ankara, Turkey



ABSTRACT

Objective: We aimed to explain the role of ultrasonography (US) in the diagnosis of vesico-ureteral reflux (VUR) and compare it with the voiding cystourethrography (VCUG) which is gold standard.

Material and Methods: Between April 2010 and March 2019, 532 VCUG and concurrent US tests performed by a single radiologist were evaluated retrospectively. Demographic characteristics, pelvic stasis, pelvi – calyxeal dilatation and hydro – uretero – nephrosis in the US, and reflux in the VCUG were recorded. ROC analysis was performed to compare the two tests.

Results: Ages of patients ranged from 5 months to 18 years and 342 (64.3 %) were female, and 190 (35.7 %) were male. The patients were divided into two groups as below 6 years (n = 286) and over 6 years (n = 246). There was a correlation between US and VCUG findings under the age of 6 (p<0.005, OR=6.977), but not in the cases over (p=0.539). In the ROC analysis of US in detection of VUR, compared to VCUG, sensitivity, specificity, Positive Predictive Value (PPV), and Negative Predictive Value (NPV) below 6 years age were 89.76 %, 47.86 %, 65.1 %, and 81.2 % (AUC= 0.688, p= 0.0001) respectively, and those over 6 years of age were 50.49 %, 53.55 %, 38.0 %, and 65.8 % (AUC=0.520, p= 0.5720).

Conclusion: US is an easy, reproducible, safe and effective method in the diagnosis of VUR. It can be used as a screening test below 6 years of age with high sensitivity (89.7%) and NPV (81.2%). VCUG is the gold standard examination for definitive diagnosis in all age groups.

Key Words: Cysto-urethrography, Diagnosis, Pediatrics, Screening, Ultrasonography, Vesicoureteral reflux, Voiding

ÖZ

Amaç: Ultrasonografinin (US), veziko-üreteral reflü (VUR) tanısındaki rolünü açıklamak ve tanıda altın standart olan voiding sistoüretrografi'yle (VCUG) kıyaslamayı amaçladık.

Gereç ve Yöntemler: Nisan 2010 - Mart 2019 tarihleri arasında tek bir radyolog tarafından uygulanmış 532 VCUG ve eş zamanlı US tetkiki retrospektif olarak değerlendirildi. Demografik özellikler, US'de; pelvik staz, pelvikalkiksiyel dilatasyon, hidroüreteronefroz ile VCUG'de reflü varlığı kaydedildi. İki testi kıyaslamak için ROC analizi yapıldı.

Bulgular: Hastaların yaşları 5 ay- 18 yaş arasında değişmekte ve 342' si (% 64.3) kadın, 190'ı (% 35.7) erkekti. Hastalar 6 yaş altı (n=286) ve 6 yaş üstü (n=246) olmak üzere iki gruba ayrıldı. 6 yaş altında US ve VCUG bulgularında korelasyon saptanırken (p<0.005, OR=6.977), 6 yaş üstünde saptanmadı (p=0,539). ROC analizinde US'nin VUR saptamadaki, sensitivite, spesifite, pozitif prediktif değer (PPV), ve negatif prediktif değeri (NPV) 6 yaş altında; % 89.76, % 47.86 %, % 65.1 ve % 81.2 (AUC= 0.688, p= 0.0001), 6 yaş üstünde % 50.49, % 53.55, % 38.0 ve % 65.8 (AUC=0.520, p= 0.5720) olarak hesaplandı.

Sonuç: Ultrasonografinin (US), VUR tanısında kolay, tekrarlanabilen, güvenli ve etkin bir yöntemdir. Yüksek sensitivite (% 89.7) ve NPV (% 81.2) oranları ile 6 yaş altında tarama testi olarak kullanılabilir. VCUG tüm yaş gruplarında kesin tanı için altın standart incelemidir.

Anahtar Sözcükler: Sistoüretrografi, Tanı, Pediatri, Görüntüleme, Ultrasonografi, Vezikoüreteral reflü, Voiding



BAYRAM ILIKAN G : 0000-0001-5833-022X

Conflict of Interest / Çıkar Çatışması: On behalf of all authors, the corresponding author states that there is no conflict of interest.

Ethics Committee Approval / Etik Kurul Onayı: Local ethics committee approval was received for the study (27.04.2020, no:7).

Contribution of the Authors / Yazarların katkısı: BAYRAM ILIKAN G: Constructing the hypothesis or idea of research and/or article. Organizing, supervising the course of progress and taking the responsibility of the research/study.

How to cite / Atıf yazım şekli : Bayram Ilıkan G. How Can We Specify The Role of Ultrasonography in the Vesico – Ureteral Reflux Disease?. Turkish J Pediatr Dis 2020; 14:348-351.

Correspondence Address / Yazışma Adresi:

Gülşah BAYRAM ILIKAN

Ankara City Hospital, Children's Hospital, Department of Radiology, Ankara, Turkey

E-posta: gulsahbayram@hotmail.com

Received / Geliş tarihi : 07.05.2020

Accepted / Kabul tarihi : 08.05.2020

Online published : 16.06.2020

Elektronik yayın tarihi

DOI: 10.12956/tchd.733936

INTRODUCTION

The etiology is Vesico – ureteral reflux (VUR) disease, in 30-40% of urinary tract infections (UTI) in children (1). Moreover, VUR is a significant cause of renal damage and the reason of 25% of the end stage renal disease (2). Underlying reason in 90% of the pediatric VUR cases is congenital insufficiency of vesico – ureteral junction. Prevalence of VUR is 25% below 4 years of age, and 12% between 4 – 12 years (3).

Voiding cysto – ureterography (VCUG) is the gold standard diagnostic test that is invasive and carries the risk of radiation exposure which is problem with pediatric cases. Less commonly used di – methyl succinic acid (DMSA) renal cortical scintigraphy also has the risk of radiation, as well as less widely available. Because these methods are invasive and carry risk of radiation and other morbidities, they are not the suitable for the initial screening of the suspected cases.

Aim of this study is to explore the proper role and indication for the use of ultrasonography (US) in the VUR disease and compare it with the VCUG which is gold standard.

MATERIAL and METHODS

This is a retrospective analysis of 532 simultaneous VCUG and US examinations applied by a single radiologist between April 2010 and March 2019, in our hospital. Written consent was obtained from the parents of all patients prior to VCUG. Demographic characteristics, pelvic stasis, pelvi – calyceal dilatation and hydro – uretero – nephrosis in the US, and VUR according to the International Reflux Study in Children in the simultaneous VCUG examination were recorded (4). According to this study VCUG findings were categorized as; Grade 0, no reflux; Grade I, solely ureteral dilatation; Grade II, ureter, pelvis and calyces with normal fornices; Grade III, mild or moderate dilatation and/or tortuosity of the ureter and mild or moderate dilatation of the renal pelvis, no or slight blunting of the fornices; Grade IV, moderate dilatation and/or tortuosity of the ureter and moderate dilatation of the renal pelvis and calyces; Grade

V, gross dilatation and tortuosity of the ureter, gross dilatation of the renal pelvis and calyces, the papillary impressions are no longer visible in the majority of the calyces. In the US examination renal pelvis diameter in the transverse section is taken into consideration. If it is obviously dilated, ureter diameter is also recorded.

Cases with operation due to urinary tract pathology, and those without simultaneous US and VCUG examination were excluded. Due to high spontaneous resolution rate below 6 years of age, these cases were compared with the cases over 6 years of age. Study was done according to the rules of Declaration of Helsinki. Local ethics committee approval was received for the study (27.04.2020, no:7).

Correlation test, sensitivity, specificity, positive predictive value (PPV) and negative predictive value (NPV) determined by ROC analysis, and chi – square tests were used with SPSS version 18, or the statistical analysis.

RESULTS

Among the cases between 5 months to 18 years of age, 342 (64.3%) were female, and 190 (35.7%) were male. Main presenting complaints were dysuria, urgency, frequent urination, and fever. Presumptive diagnosis was VUR or hydro – nephrosis. While VUR was not detected in 300 (56.4%) VCUG's, VUR was detected in 232 (43.6%) VCUG's . Varying degrees of collecting duct dilatation was detected in the 312 (58.6%) of the US examinations.

The cases were divided into two groups below 6 years and over 6 years of age (n = 246 (46.2%), n=286 (43.8%) respectively). Table I demonstrates the US and VCUG findings in the groups.

In the cases below 6 years of age, there was a correlation between US and VCUG findings ($p=0.000$, $OR=6977$, 95% Confidence Interval = 3646-13353). On the contrary, in the cases over 6 years of age there was no significant correlation ($p=0.539$, $OR=1.176$, 95% Confidence Interval= 0.725 – 1.906).

Table I: Distribution of the US and VCUG findings in the age groups.

Age Group	US	VCUG	Number of examinations	%
< 6 years	- *	-	56	22.8
	+ †	+	114	46.3
	- (False negative)	+	15	6.1
	+ (False positive)	-	61	24.8
	Total		246	100
≥ 6 years	-	-	98	34.3
	+	+	52	18.2
	- (False negative)	+	51	17.8
	+ (False positive)	-	85	29.7
	Total		286	100

*- Normal findings in US or VCUG, †+ Collecting duct dilatation in US or VUR in VCUG

Table II: Results of the ROC analysis.

Age	Sensitivity %	Specificity %	PPV %	NPV %	p	AUC
< 6 (n= 246)	89.76	47.86	65.1	81.2	0.0001	0.688
≥ 6 (n= 286)	50.49	53.55	38.0	65.8	0.5720	0.520
Total (n= 532)	72.17	51.33	53.2	70.6	0.0001	0.618

PPV: Positive Predictive Value, **NPV:** Negative Predictive Value

In the ROC analysis of US in detection of VUR, compared to VCUG, sensitivity, specificity, Positive Predictive Value (PPV), and Negative Predictive Value (NPV) below 6 years age was 89.76%, 47.86%, 65.1%, and 81.2% (AUC= 0.688, $p=0.0001$), and over 6 years of age was 50.49%, 53.55%, 38.0%, and 65.8% (AUC=0.520, $p=0.5720$) respectively. Results of the ROC analysis were 72.17%, 51.33%, 53.2%, and 70.6% in all patients respectively (AUC= 0.618, $p=0.0001$) (Table II).

DISCUSSION

VUR is seen in 0.5 – 1.5% of children. Because conventional diagnostic modalities like VCUG and DMSA scintigraphy carries high risk of radiation, they are not suitable for screening purposes (3, 5). US can be an ideal candidate for screening as a non – invasive and radiation free modality. However, it has been stated in many studies that its sensitivity is not sufficient to make a definitive diagnosis alone (4, 6).

US can demonstrate calyceal and ureteral dilatation that are characteristic features of VUR as well as it reveals kidney sizes and renal parenchymal thickness showing chronic irreversible renal damage. It is also effective in the differential diagnosis of ureterocele of bladder, and stenosis of the uretero – pelvic junction (UPJ) (1-3,7,8).

Many studies evaluating ultrasound and VCUG in different age groups have shown that the diagnostic value of ultrasound increases at young age. In the study comparing color doppler voiding urosonography with radionuclide voiding cystography, smaller ages had increased sensitivity that was claimed to be probably due to the increased sonographic resolution in small children (9).

In the elegant study by Adibi et al. (1), that compares US with scintigraphy, among 90 cases between 2 – 12 years of age,

they measured pre and post valsalva diameters of renal pelvis and ureter, and distance of vesico – ureteral junction from midline. They revealed that a resting pelvis dilatation over 3 mm has a high sensitivity and specificity for VUR. Overall sensitivity 70.9%, specificity 51.4%, PPV 69.64%, and NPV were 52.94% for detecting VUR in US examination. Despite the fact that decreasing the risk of radiation exposure is ideal for first line diagnostic or screening tool, having a relatively low NPV is a disadvantage. Moreover, relative lack of co – operation in pediatric age group for an effective and reproducible valsalva maneuver is the major drawback for this test. In our study, renal pelvis dilatation (stasis) in routine US examination even below 5 mm is an indicator of VUR below 6 years of age ($p<0.001$). Degree of pelvic dilatation is independent of the extent of VUR disease ($p>0.05$). If the radiologist is experienced and careful enough, he can detect as small as 2 – 3 mm pelvic dilatation revealing VUR, which is quite reliable.

Contrast enhanced sonographic modalities, pulse wave color Doppler or B mode voiding urosonography were other non – invasive modalities tried in the diagnosis of VUR disease. On the other hand, they are not universally available, cheap and non – invasive as the conventional US examination (8,9,11,13,14). These studies showed that VCUG is still the gold standard in the diagnosis of VUR. Most important issue is to prevent unnecessary use of this invasive modality (11,13,15,16).

In the study by Nafisi-Moghadam et al.(3), voiding ultrasonography was compared with VCUG. Sensitivity was found 63% and specificity was found 91% (3). It has been reported that the sensitivity of US is higher in high grade reflux. Munsterer et al compared US and VCUG and demonstrated that, US is especially effective at diagnosis of Grade 3 – 5 VUR. It also clarifies the renal dimension changes or collecting duct dilatation. On the other hand, they emphasized the importance of low grade (grade 1, 2) VURs undergoing spontaneous

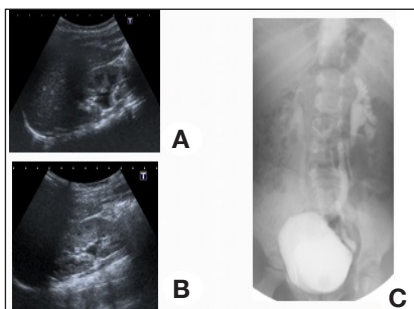


Figure 1 (A-C): A 4 year old girl having bilateral caliectasis in US (1A, 1B), and bilateral grade 4 – 5 VUR in VCUG (1C).

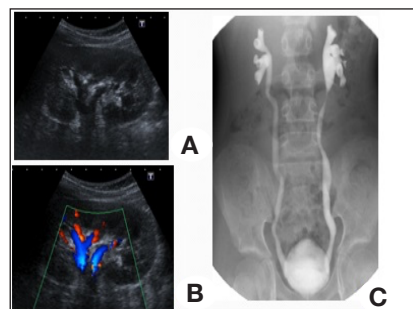


Figure 2 (A-C): Figure 2 (a - c): The same case in 8 years of age with normal findings in US, (2A, 2B) however VCUG demonstrates bilateral grade 4 – 5 VUR (2C).

resolution and leaving no scar (8). This phenomenon is more common in first 5 years of life. The probability of spontaneous resolution rate is more than 50% in the 1-2 year old VURs and the 3-5 year old unilateral VURs, in the first 5 years follow up (10). This data support our findings that in the cases below 6 years of age. In our study, there were 15 patients below 6 years age who were found to have VUR in VCUG despite the normal US examination. 9 (60%) of these 15 patients had grade 1-2 with high probability of spontaneous resolution. Below 6 years of age, high sensitivity (89.7%) and negative predictive value (81.2%) of US means that negative results most probably exclude VUR, making this method a possible screening test. If ultrasound is normal, child should be followed without VCUG.

In 25 children younger than 6 years of age, we found transvers renal pelvis diameter above 10 mm in US, but no VUR in VCUG. Final diagnosis of these patients was stenosis of uretero-pelvic junction. In children under 6 years of age, if the renal pelvis diameter is greater than 10 mm and there is no ureter dilation, UPJ stenosis should be considered first. In this case, VCUG may not be required.

US had a relatively low sensitivity and specificity (50.49%, and 53.55%, respectively) among children above 6 years of age. In this age group US was not as effective as VCUG, and not enough for screening. In the figures 1 and 2, disparity of US to VCUG is clearly seen.

It is difficult to making generalization, because our study included US and VCUG examinations made by a single experienced radiologist in pediatric patients. Studies with tests performed by different radiologists and more patients are needed.

CONCLUSION

At least for a specific group below the age of 6, US is easy, reproducible, safe and effective both for differential diagnosis, staging and learning about the complications of the disease ie. renal parenchymal damage. Its high sensitivity (89.7%), and negative predictive value (81.2%), can make it an ideal initial screening test in this selected sub – group of patients. VCUG as a gold standard modality can be reserved for definitive diagnosis in the suspected cases below the age of 6 and all of the cases after the age of 6.

REFERENCES

1. Adibi A, Gheysari A, Azhir A, Merikhi A, Khami S, Tayari N. Value of Sonography in the Diagnosis of Mild, Moderate and Severe Vesicoureteral Reflux in Children. Saudi J Kidney Dis Transpl 2013; 24: 297-302.
2. Lim R. Vesicoureteral reflux and urinary tract infection: Evolving practices and current controversies in pediatric imaging. Am J Roentgenol 2009; 192: 1197-208.
3. Nafisi-Moghadam R, Malek M, Najafi F, Shishehsaz B. The Value of Ultrasound in Diagnosing Vesicoureteral Reflux in Young Children with Urinary Tract Infection. Acta Med Iran 2011; 49: 588-91.
4. Lebowitz RL, Olbing H, Parkkuleinen KV, Smellie JM, Tamminen-Möbius TE. International system of radiographic grading of vesicoureteric reflux. *Pediatr Radiol* 1985; 15: 105-9.
5. Fallah MM, Falahati M, Mohammadi A, Alizadeh M, Mladkova-Suchy N, Ghasemi-Rad M. Comparative study of color doppler voiding urosonography without contrast enhancement and direct radionuclide voiding cystography for diagnosis of vesicoureteric reflux in children. *J Ultrasound Med* 2012; 31: 55-61.
6. Shaikh N, Spingarn RB, Hum SW. Dimercaptosuccinic acid scan or ultrasound in screening for vesicoureteral reflux among children with urinary tract infections. *Cochrane Database Syst Rev* 2016 Jul 5;7:CD010657.
7. Kenney IJ, Negus AS, Miller FN. Is sonographically demonstrated mild distal ureteric dilatation predictive of vesicoureteric reflux as seen on micturating cystoureterography. *Pediatr Radiol* 2002; 32:175-8.
8. Muensterer OJ. Comprehensive ultrasound versus voiding cysturethrography in the diagnosis of vesicoureteral reflux. *Eur J Pediatr* 2002; 161: 435-7.
9. Otukesh H, Hoseini R, Behzadi AH, Mehran M, Tabbaroki A, Khamesan B, et al. Accuracy of cystosonography in the diagnosis of vesicourethral reflux in children. *Saudi J Kidney Dis Transpl* 2011; 22: 488-91.
10. Thompson M, Simon SD, Sharma V, Alon US. Timing of Follow-up Voiding Cystourethrogram in Children With Primary Vesicoureteral Reflux: Development and Application of a Clinical Algorithm. *Pediatrics* 2005; 115:426-34.
11. Darge K. Diagnosis of vesicoureteral reflux with ultrasonography. *Pediatr Nephrol* 2002; 17:52-60.
12. Ji LN, Cao L, Chen DK, Cui YC, Zhang YL, Ye H, et al. Evaluation of the clinical and imaging examination in high-risk children with vesicoureteral reflux. *Zhonghua Er Ke Za Zhi* 2011; 49: 282-6.
13. Haberlik A. Detection of low-grade vesicoureteral reflux in children by color Doppler imaging mode. *Pediatr Surg Int* 1997;12:38-43.
14. Darge K, Riedmiller H. Current status of vesicoureteral reflux diagnosis. *World J Urol* 2004; 22:88-95.
15. Lee LC, Lorenzo AJ, Koyle MA. The role of voiding cystourethrography in the investigation of children with urinary tract infections. *Can Urol Assoc J* 2016;10: 210-14.
16. Schaeffer AJ, Greenfield SP, Ivanova A, Cui G, Zerlin JM, Chow JS, et al. Reliability of grading of vesicoureteral reflux and other findings on voiding cystourethrography. *J Pediatr Urol* 2017; 13: 192-8.