



ARAŞTIRMA / RESEARCH

Is there a place for sonohysterobiopsy in the evaluation of endometrial pathologies in postmenopausal asymptomatic women with thickened endometrium?

Asemptomatik postmenopozal kadınlardaki endometrial patolojilerin değerlendirilmesinde sonohisterobiopsinin yeri var mı?

Abdurrahman Alp Tokaloğlu¹, Berna Dilbaz², Runa Özelci³, Eda Tokaloğlu¹, Bora Coşkun⁴

¹Ankara City Hospital, Ankara, Turkey

²Etilik Zubeyde Hanım Women's Health Training and Research Hospital, Department of Reproductive Endocrinology and Infertility, ³Department of Reproductive Endocrinology and Infertility, Ankara, Turkey

⁴Liv Hospital, Ankara, Turkey,

Cukurova Medical Journal 2020;45 (3):1080-1088

Abstract

Purpose: The aim of this study was to compare the diagnostic value of sonohysterobiopsy to a method involving saline infusion sonography followed by dilatation and curettage in detecting endometrial pathologies in postmenopausal asymptomatic women with an endometrial thickness greater than 5 mm.

Materials and Methods: Asymptomatic postmenopausal women who were diagnosed by means of transvaginal ultrasonography with endometrial thickness greater than 5 mm were assigned to two diagnostic groups prior to hysteroscopy. The study group included patients who underwent sonohysterobiopsy (SHB) during saline infusion sonohysterography (SIS). The control group included patients who underwent SIS followed by dilatation and curettage (D&C).

Results: In 35 patients (35%), at least one of the risk factors for endometrial malignancy was present. The histopathological evaluation of the specimens showed presence of a polyp in 40 (60%) patients who underwent SIS and D&C. SHB results were more concordant with the hysteroscopic findings compared to those of SIS and D&C. The cut-off value for the accurate diagnosis of an endometrial polyp with SHB was 10 mm, with a sensitivity of 96% and a specificity of 100%.

Conclusion: Sonohysterobiopsy is an efficient and safe procedure with a high sensitivity and specificity for the diagnosis of endometrial pathologies.

Keywords: Postmenopause, endometrial hyperplasia; hysteroscopy, endometrium, endometrium cancer

Öz

Amaç: Bu çalışmanın amacı endometrial kalınlık ölçümü 5 mm üzerinde olan asemptomatik postmenopozal kadınlarda salin infüzyon sonografi sonrası dilatasyon ve kuretaj ile sonohisterobiopsinin (SHB) tanısal değerlerinin karşılaştırılmasıdır.

Gereç ve yöntem: Transvajinal ultrasonografi ile endometrium kalınlığı 5 mm üzeri tespit edilen asemptomatik postmenopozal kadınlar histeroskopi öncesinde iki gruba ayrıldı. Salin infüzyon sonografi (SIS) ile eş zamanlı sonohisterobiopsi yapılan 50 olgu çalışma grubu olarak (Grup 1), salin infüzyon sonografi ardından kuretaj yapılan hastalar ise kontrol grubu olarak belirlendi (Grup 2).

Bulgular: Olguların %35'inde endometrium kanseri açısından en az 1 tane risk faktörü vardı. SIS ve sonrasında kuretaj yapılan hastaların %60'ında histopatolojik incelemede polip bulundu. SHB bulguları SIS ve kuretaj yapılan olgularla karşılaştırıldığında histeroskopik bulgularla daha uyumlu bulundu. SHB ile endometrial poliplerin kesin tanı ve tedavisi için eşik değer % 96 duyarlılık ve %100 özgüllük ile 10 mm olarak bulundu.

Sonuç: SHB endometrial patolojilerin tanı ve tedavisinde yüksek duyarlılık ve özgüllüğe sahip etkili ve güvenli bir yöntemdir.

Anahtar kelimeler: postmenopoz, endometrial hiperplazi; histeroskopi, endometrium kanser

Yazışma Adresi/Address for Correspondence: Dr. Runa Özelci, Etilik Zubeyde Hanım Women's Health Training and Research Hospital, Dept of Reproductive Endocrinology and Infertility, Ankara, Turkey, E-mail: runakara@mail.com
Geliş tarihi/Received: 19.02.2020 Kabul tarihi/Accepted: 21.06.2020 Çevrimiçi yayın/Published online: 30.08.2020

INTRODUCTION

Endometrial cancer, the most frequent malignancy of the genital tract, is on the rise in many countries ¹. According to data from GLOBOCAN 2012, it is the fifth most common cancer among women of all ages ²; in Turkey, the incidence rate is 6.1%. Although vaginal bleeding, the most common presenting symptom, is associated with a 1-10% risk of endometrial cancer, depending on the sensitivity and specificity of screening programs, up to 20% of women may have no symptoms at the time of diagnosis ³.

Some studies have reported that endometrial thickness greater than 5 mm is an appropriate cut-off level in screening for carcinoma in asymptomatic postmenopausal women ^{4,5}. Transvaginal ultrasonography (TVUSG) is frequently used in gynaecology practice, and studies have found that TVUSG increases the likelihood of early diagnosis and other useful additive parameters of sonographic findings may be used to predict endometrial malignancy ⁶. However, it is not reliable as a screening method and is limited in the diagnosis of focal lesions. Saline infusion sonography (SIS) improves the detection and identification of endometrial pathology, with sensitivity and specificity comparable to hysteroscopy. Compared to D&C, the gold standard diagnostic method, SIS is more reliable, safer, cheaper and better tolerated by patients. Sonohysterobiopsy (SHB), the combination of SIS and endometrial sampling, may improve the diagnostic accuracy of either procedure performed alone but there is limited number of publications on the use of sonohysterobiopsy. Moschos et al. compared saline infusion sonography with blind endometrial biopsy in women with abnormal uterine bleeding ⁷ and also Rotenberg et al.⁸ compared saline infusion sonography with endometrial aspiration. Our study differs from previous studies in that it analysed the performance of endometrial biopsy at the time of saline infusion sonography using both sequential and simultaneous.

The aim of the present study is to compare the diagnostic value of sonohysterobiopsy to that of SIS followed by D&C in detecting endometrial pathologies, especially in asymptomatic postmenopausal women with an endometrial thickness greater than 5 mm.

MATERIALS AND METHODS

Postmenopausal women who visited Etlik Zübeyde Hanım Women's Health Training and Research Hospital's Menopause Outpatient Clinic for routine exams between January 1, 2015 and December 31, 2015 were recruited for this retrospective study. Before starting the study, approval was received from the Local Ethics Committee of Etlik Zübeyde Hanım Women's Health Training and Research Hospital (Decision date: 19/10/2015; Approval number: 200) and this study was made in accordance with the principles of the Helsinki Declaration.

Postmenopause was defined as the absence of menstruation for the preceding 12 months or more. If the patients had a history of tamoxifen use, endometrial cancer or endometrial hyperplasia, they were excluded. Postmenopausal asymptomatic women without vaginal bleeding who were diagnosed with endometrial thickness greater than 5 mm as measured by transvaginal ultrasonography met the inclusion criteria. The age of the patients, their body mass index (BMI), their age at menopause, the number of years since menopause, and any comorbid medical illness associated with endometrial cancer, such as diabetes mellitus (DM) or hypertension (HT), were recorded. All the patients signed an informed consent form after being provided with a detailed explanation of all procedures.

Procedure

The initial clinical assessment of the patients was performed by the resident physicians of the clinic, and transvaginal ultrasonography was performed in both the sagittal and transverse planes. Endometrial thickness was measured in the sagittal plane using a 5 MHz endovaginal probe (General Electric Logic 5, Waukesha, Wisconsin, USA). Two additional methods were employed to further evaluate the women, and then hysteroscopy (HS) was performed on all patients in order to improve diagnostic accuracy.

The first group included 50 postmenopausal women who underwent saline-infusion sonography endometrial sampling at the time of their sonohysterography procedure. The second group included 50 postmenopausal women who underwent SIS followed by D&C.

To prepare for the procedure, the external os was cleaned with povidone iodine. A 10-12 F catheter was inserted into the uterus through the cervical canal and then a vaginal probe was reintroduced in the vagina. To expand the uterine cavity, 10-20 ml of sterile saline solution was injected slowly under direct sonographic visualization. Multiple transverse and sagittal images of the uterus were obtained. Injection was performed for a second and third time in doubtful cases.

Saline infusion sonography endometrial sampling (sonohysterobiopsy) was performed in the case of an identified lesion using a (7.2 F/26 cm) sonohysterobiopsy catheter (Goldstein Sonobiopsy Catheter, Cook Incorporated, Bloomington, Indiana, USA) under direct transvaginal sonographic visualization. To obtain a biopsy specimen when a focal lesion was detected, the catheter was pushed so that its edge was in direct contact with the lesion; the biopsy was then taken at the site of endometrial abnormality. If the endometrium had a normal appearance, the biopsy was taken from a representative site in the uterine cavity. On the other hand, in the control group, when the SIS was completed and the catheter removed, endometrial sampling was performed in a blind D&C using an endometrial sampling curette. Neither non-steroidal anti-inflammatory agents nor prophylactic antibiotics were used before the procedures.

Hysteroscopy is considered to be the gold standard in uterine cavity assessment; therefore, final diagnosis was based on the combined hysteroscopic and histologic results. Diagnostic hysteroscopy under general anaesthesia was performed the next day, using a 30 hysteroscope and a diagnostic sheath with a diameter of 5 mm (Karl Storz, Tuttlingen, Germany). Sodium chloride was used as the distension medium. A D&C was performed on those patients who showed no intracavitary lesions during the diagnostic HS. The patients with intracavitary lesions underwent operative hysteroscopy following diagnostic HS in the same session. Tissue was collected for pathologic evaluation that would allow a definitive diagnosis to be made.

Accepting hysteroscopy as the gold standard method, the visual findings and histopathological reports of the specimens obtained by SHB and SIS and D&C were compared to the hysteroscopic findings and hysteroscopy-guided biopsies. The sensitivity, specificity, positive predictive value and negative predictive value of the SHB and SIS and D&C

methods were calculated.

Statistical analysis

Demographic data were analysed by means of descriptive statistics. Baseline characteristics were summarized as mean and SD for normally distributed variables. A chi-square test and Fisher's exact test were used, as appropriate, to compare nominal variables. Analysis of quantitative data were evaluated with independent sample T test. Kappa test was used to test the agreement between the two techniques. Polyp size values as predictors of the diagnostic effectiveness and process performance were analysed using ROC (receiver operating characteristics) curve analysis. When a significant cut-off value was observed, the sensitivity, specificity, and positive and negative predictive values were presented. While evaluating the area under the curve, $p < 0.05$ was considered to be statistically significant. All statistical analyses were performed using SPSS for Windows, Version 2.

RESULTS

Data from 100 patients were included in the present study. The mean age of the patients was 55.9 ± 5.4 years (range: 45-74). The mean BMI was 29.07 ± 4.74 kg/m². The baseline characteristics of the study cohorts are detailed in Table 1. In 58 patients (58%), at least one of the risk factors for endometrial cancer, such as DM, HT, or hyperlipidaemia, was present (Table 2). There were no complications incurred by either method. Of the 50 SHB specimens sent for histologic evaluation, insufficient endometrial tissue was present in only one case (2%), and polyps were diagnosed in 30 patients (60%). In the SIS and D&C group, 12 samples (24%) had insufficient tissue and 15 (30%) women had endometrial polyps. Comparisons between the sonohysterobiopsy and SIS and D&C findings are presented in Tables 3 and 4. When the duration of the procedures is compared, the intervention time of the sonohysterobiopsy was found to be significantly longer than that of the SIS and D&C procedure ($p < 0.001$). The number of patients with incomplete removal of endometrial lesions such as polyps was 22 (44%) in the D&C group and 25 (50%) in the SHB group; there were no significant differences between two groups ($p = 0.548$).

Sonohysterobiopsy showed greater agreement with HS than SIS and D&C (Kappa 1.00, 95%CI 1.00-

1.00) and correctly identified 14 of the 15 polyps. On the other hand, SIS and D&C described 12 specimens as insufficient material, but final pathology diagnosed the specimens as endometrial polyps. The negative and positive predictive value of SIS and D&C were found to be 100% and 50%, respectively. The kappa value was 0.638 (95%CI 0.26-1.00).

In the SIS and D&C group, polyp size showed no significant difference in determining the need for further intervention during hysteroscopy ($p=0.051$). In the sonohysterobiopsy group, however, polyp size was an important factor in determining the need for additional intervention during hysteroscopy ($p<0.001$). The results are shown in Table 5.

Table1. The baseline characteristics of the study cohorts

	SIS and D&C	Sonohysterobiopsy	P
	Mean \pm SD	Mean \pm SD	
Age, years	59.0 \pm 5.4	57.2 \pm 5.4	0.051
Gravida	4.1 \pm 1.7	3.7 \pm 1.6	0.031
Parity	2.8 \pm 1.3	2.5 \pm 1.0	0.388
Age at menarche, years	13.1 \pm 1.2	13.5 \pm 1.4	0.229
Age at menopause, years	50.3 \pm 2.4	48.8 \pm 3.3	0.051
Menopause duration, years	8.8 \pm 5.2	7.2 \pm 5.3	0.077
BMI kg/m ²	32.8 \pm 5.5	33.0 \pm 5.3	0.705

BMI: body mass index, SIS: saline infusion sonohysterography, D&C: dilatation and curettage

Table 2. Risk factors for endometrial carcinoma

Risk factors	SIS and D&C	Sonohysterobiopsy
	n(%)	n(%)
No	19 (38)	22(44)
Hypertension(HT)	13 (26)	8(18)
Diabetes Mellitus(DM)	4 (8)	5(10)
Cardiac Disease	0 (0)	1(2)
Hyperlipidemia	0 (0)	4(8)
HT +Hyperlipidemia	3 (6)	2(4)
HT + DM +Hyperlipidemia	10 (20)	7(14)
DM + Hyperlipidemia	1 (2)	1(2)

Table 3. Comparison of hysteroscopic findings and saline-infusion sonography and D&C

SIS and D&C	Hysteroscopy Hystopathologic findings					
	Polyp n(%)	Polyp+myoma uteri n(%)	Proliferative Endometrium n(%)	Atrophic endometrium n(%)	Myoma uteri n(%)	Total n(%)
Insufficient material	12(24)	-	-	-	-	12(24)
Polyp	21(42)	-	9(18)	-	-	30(60)
Normal endometrium	-	2(4)	-	-	-	2(4)
Atrophic endometrium	-	-	-	6(12)	-	6(12)
Total	33(66)	2(4)	9(18)	6(12)	-	50(100)

SIS: saline infusion sonohysterography, D&C: dilatation and curettage

Table 4. Comparison of hysteroscopic findings and sonohysterobiopsy results

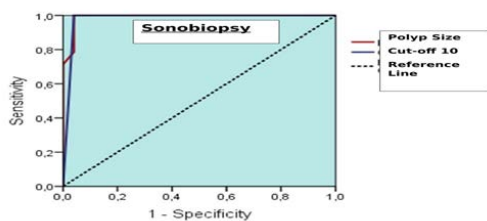
Sonobiopsy Histopathology	Hysteroscopy histopathological findings				
	Polyp n(%)	Proliferative endometrium n(%)	Atrophic endometrium n(%)	Myoma uteri n(%)	Total n(%)
Insufficient material	1(2)	-	-	-	1(2)
Polyp	14(28)	1(2)	-	-	15(30)
Normal endometrium	4(8)	22(44)	-	1(2)	27(54)
Atrophic endometrium	-	3(6)	4(8)	-	7(14)
Total	19(38)	26(52)	4(8)	1(2)	50(100)

Table 5. The relation between polyp size and the need for additional intervention during hysteroscopy

	Unsuccessful Mean± SD	Successful Mean ± SD	P
SIS +D&C			
Polyp size,mm	16 ± 6.6	20.8±7.0	0.051
Sonohysterobiopsy			
Polyp size,mm	19.4± 4.2	8.7±1.3	0.001

SIS : saline infusion sonohysterography; D&C: dilatation and curettage, p values with statistical significance ($p < 0.05$) are shown in bold

In determining the need for additional intervention during hysteroscopy, ROC analysis was used to reveal the polyp size cut-off. A cut-off of 10 mm is used as the threshold to apply the sonohysterobiopsy method, and the AUC of polyp size was detected as 0.980 (0.93-1.00; $p < 0.001$). Therefore, a polyp size of 10 mm as the cut-off for the need of additional intervention during hysteroscopy resulted in a specificity of 96% and a sensitivity of 100%; this data can be seen in Figure 1.

**Figure 1. ROC curve of sonobiopsy to determine the need for additional intervention during hysteroscopy**

DISCUSSION

The aim of the present study was to compare the diagnostic value of sonohysterobiopsy to a method involving saline infusion sonography followed by dilatation and curettage in detecting endometrial

pathologies in postmenopausal asymptomatic women with an endometrial thickness greater than 5 mm. We found that sonohysterobiopsy provides both high sensitivity and specificity in detecting and obtaining adequate tissue samples and it has relatively low cost, low morbidity, less invasive nature and superior diagnostic capability.

Although TVUSG has limited value in the evaluation of intracavitary pathologies, it is still a first-line investigative modality in patients with abnormal uterine bleeding. The alternative diagnostic procedures are SIS and HS⁹. Seckin et al. also reported that mean platelet volume may be a highly valuable tool in distinguishing submucosal fibroids from other causes of abnormal uterine bleeding as a new noninvasive diagnostic tool¹⁰.

Several studies have demonstrated that the combination of SIS and blind endometrial sampling improves the diagnostic accuracy of either procedure performed alone^{11,12}. Some researchers have suggested that to obtain the tissue at the site of endometrial abnormality, endometrial sampling should be performed after sonohysterography and biopsy should be done under the direct visualization of sonoguidance^{13,14}.

Our study differs from previous studies in that it analysed the performance of endometrial biopsy at the time of saline infusion sonography using both sequential and simultaneous. It also reported only on

asymptomatic, rather than symptomatic, postmenopausal women ^{11,13}.

The primary concern about blind D&C is that it may not obtain sufficient material. Reports in the literature differ concerning the general accuracy rate of D&C to the extent that the acceptance of D&C as the gold standard method in detecting uterine pathologies has become controversial ¹⁵. Barut et al. found that the insufficient tissue rate was 49% in postmenopausal women ¹⁶. On the other hand, Demirkıran et al. reported an insufficient tissue rate of 3% ¹⁷. Stock and Kanbour found that less than one half of the endometrium was curetted during the D&C procedure, and 4%-20% of specimens provided inadequate tissue for histological diagnosis ¹⁸. Agostini et al. demonstrated that blind endometrial biopsies were non-diagnostic in 2%-28% of attempts and had a false negative rate of 5%-15% ¹⁹. Bettocchi et al. concluded that D&C was inefficient in detecting endometrial pathologies ²⁰. Karasu et al. reported an insufficient tissue rate of 12.5% ²¹. In our study, 12 specimens from the SIS and D&C group provided inadequate tissue for histological diagnosis, an insufficient tissue rate of 24%. On the other hand, only one case provided insufficient tissue in the sonohysterobiopsy group.

In Budak et al research, the ratio of endometrial polyp in patients with postmenopausal women is 18.3%²². Several studies have shown that a blind D&C alone is especially likely to miss focally growing lesions^{23,24}. Epstein et al. reported that whole or partial focal lesions remained in situ after D&C in 87% of women. They also found that the sensitivity of D&C was 42% for endometrial pathology, and another study found that D&C missed 58% of polyps²⁵. Similarly, Svirsky et al. reported that the performance of endometrial biopsy in the diagnosis of focal endometrial lesions was poor²⁶. In postmenopausal women, it is important that polyps be fully removed rather than sampled with small biopsies because a focus of endometrial cancer involving the stalk or other parts of the polyp may be present ²⁷. Some studies have found a false-negative rate between 2% and 12%^{28,29}.

Although D&C is accepted as the gold standard technique, when D&C is compared with hysterectomy, which is a final pathology, the concordance rate was found to be 70%¹⁷. In accordance with this study, Huang et al. demonstrated that the concordance of histopathology with final pathology was 62.8% for D&C³⁰, but Demirkıran et al. found that the

concordance between D&C and final diagnosis was 94% in women without focal endometrial lesions¹⁷. The greatest challenge to blind endometrial sampling methods is most probably focal endometrial pathologies. Our study showed that the patients who provided insufficient material (n=12) during the SIS and D&C procedure had histopathological findings of endometrial polyps. When comparing SIS and D&C with the final outcomes, the SIS and D&C procedure exhibited lower agreement than the sonohysterobiopsy group (kappa 0.638, 95CI% 0.26-1.00; 1.00, 95CI% 1.00-1.00, p=0.001, respectively).

SIS is another technique for the evaluation of uterine pathologies. Most endometrial pathologies are associated with thickened endometrium, a condition with many causes, including submucosal myoma, hyperplasia, carcinoma and, most frequently, polyps. Because polyps are focal lesions, they are generally overlooked during the D&C procedure. However, using SIS makes detection of focal lesions possible with a high sensitivity compared to a blind evaluation. Moschos et al. found that endometrial biopsy was inferior to SIS as a diagnostic tool; in their study, SIS provided the diagnosis in 89% of women, while D&C provided the diagnosis in 52%¹³.

Hysteroscopy offers another alternative diagnostic procedure. Although HS enables a full visualization of the endometrial cavity and can be used as a diagnostic or therapeutic modality, it is uncomfortable, expensive and invasive. On the other hand, SIS is a simple, non-invasive and cost-effective procedure. Widrich et al. did not find significant differences between SIS and office HS in the diagnosis of polyps³¹. Soguktas et al. reported that, compared to HS, SIS has important advantages in clinical assessment and in the prevention of misdiagnosis³². In addition, SIS enables the measurement of intramyometrial uterine pathologies, such as fibroids, while HS cannot evaluate the depth of myometrial involvement of uterine pathologies. A meta-analysis explained that SIS is accurate in evaluating endometrial abnormalities and showed superior diagnostic performance in the evaluation of the uterine cavity ³³. Most importantly, HS offers treatment as well as diagnosis, and SIS does not. SIS also revealed a low specificity in correctly categorizing lesions as benign or malign⁷.

This limitation of SIS may be overcome by another method called sonohysterobiopsy, which provides sampling of the site of the endometrial pathology during the procedure. Leone et al. reported that

sonohysterobiopsy provided sufficient tissue samples³⁴. They also found that the diagnostic accuracy achieved by sonohysterobiopsy is comparable to that of directed endometrial biopsy with hysteroscopy, and specimen areas were not found to differ significantly. These data agree with previous reports of the diagnostic accuracy of sonohysterobiopsy^{8,35}. On the other hand, Metzger et al. found different results. They reported that their technique did not improve the diagnostic potential of sonohysterobiopsy, and that endometrial sampling had no effect on endometrial assessment by SIS procedure. However, they noted that these results may have been due to use of a stiff catheter of 3.1 mm, thinner than ordinarily used³⁶. Wei et al., who used an Explora curette of 3 mm in diameter for biopsy extraction, reported a high false-positive rate; such a rate can often be explained by the presence of mucous, bubbles or blood clots¹⁴.

In contrast, Moschos et al. found that sonohysterobiopsy allows tissue to be obtained from the site of pathology, and that it approached 100% for sensitivity and specificity, positive predictive value (PPV) and negative predictive value (NPV) in the final histological outcomes⁷. Similarly, Rotenberg et al. suggested that the performance of simultaneous endometrial aspiration at the time of SIS for women at risk for endometrial cancer was good enough; their results demonstrated an 86.7% specificity and 100% PPV in the final histological outcomes⁸. The sonohysterobiopsy group in our study produced only one sample of insufficient tissue, and the insufficient sampling rate was found to be 2%. In line with these studies, the present study demonstrated that the diagnostic accuracy of sonohysterobiopsy is high for endometrial pathology, with a sensitivity of 100% and a specificity of 100%.

Many studies have shown that SIS is a reasonable technique for the evaluation of focal lesions, and that detection of these lesions is possible with SIS and hysteroscopy with high sensitivity compared to D&C^{37,38}. Moschos et al.'s study demonstrated that D&C, which missed 15 of 16 endometrial polyps¹³, was inefficient in detecting focal lesions, in our study, however, sonobiopsy correctly identified 14 of 15 endometrial polyps. ROC curve analysis revealed that the diagnostic and therapeutic performance of sonobiopsy was significantly superior for endometrial polyps lower than 1 cm (AUC polyp size=0.98, Figure 1). Moschos et al. found that the addition of saline infusion sonography endometrial sampling

added approximately 5 minutes to the procedure¹³. In our study, the duration of the sonobiopsy procedure was significantly longer than the SIS and D&C procedure, at 6.9 ± 1.4 vs 7.7 ± 1.5 minutes, respectively ($p=0.001$), and there was no complication in either procedure⁷.

The major strength of our study, which concerned procedures performed by two experienced gynaecologists in a menopause clinic, is that it included only asymptomatic postmenopausal women. Other studies have analysed postmenopausal women who were experiencing abnormal uterine bleeding. The main limitation is the sample size of the cohort, which makes it difficult to extrapolate the data which might tend to invalidate certain of the findings.

In conclusion, our findings suggest that sonohysterobiopsy provides both high sensitivity and specificity in detecting and obtaining adequate tissue samples. Considering the general features and comorbidities of postmenopausal women, we would expect sonohysterobiopsy to become the modality of choice when evaluating this population for endometrial pathologies. Its relatively low cost, low morbidity, less invasive nature and superior diagnostic capability all recommend it; further, in certain cases, it reduces the need for hysteroscopy. On the other hand, in order to improve the success rate of this procedure, we propose modifications to the sonobiopsy catheter that enables it to remove endometrial lesions larger than 10 mm.

Yazar Katkıları: Çalışma konsepti/Tasarımı: BD, AAT; Veri toplama: ET, BC; Veri analizi ve yorumlama: BD, BC, ET; Yazı taslağı: RÖ; İçeriğin eleştirel incelenmesi: AAT; Son onay ve sorumluluk: AAT, BD, RÖ, ET, BC; Teknik ve malzeme desteği: -; Süpervizyon: RÖ; Fon sağlama (mevcut ise): yok.

Etik Onay: Bu çalışma için Ankara Sağlık Bilimleri Etik Zübeyde Hanım Kadın Hastalıkları Eğitim ve Araştırma Hastanesi 19.10.2015 yılında Eğitim Planlama Kurumunda 200 sayılı kararı ile kabul edilmiştir.

Hakem Değerlendirmesi: Dış bağımsız.

Çıkar Çatışması: Yazarlar çıkar çatışması beyan etmemişlerdir.

Finansal Destek: Yazarlar finansal destek beyan etmemişlerdir.

Author Contributions: Concept/Design : BD, AAT; Data acquisition: ET, BC; Data analysis and interpretation: BD, BC, ET; Drafting manuscript: RÖ; Critical revision of manuscript: AAT; Final approval and accountability: AAT, BD, RÖ, ET, BC; Technical or material support: -; Supervision: RÖ; Securing funding (if available): n/a.

Ethical Approval: For this study, Ankara Health Sciences Etik Zübeyde Hanım Gynecology education and Research Hospital was approved in 19.10.2015 by The Decision No. 200 of the Educational Planning institution.

Peer-review: Externally peer-reviewed.

Conflict of Interest: Authors declared no conflict of interest.

Financial Disclosure: Authors declared no financial support

REFERENCES

- Jemal A, Siegel R, Ward E, Murray T, Xu J, Thun MJ. Cancer statistics. *CA Cancer J Clin.* 2007;57:43–66.
- GLOBOCAN 2012. http://globocan.iarc.fr/Pages/fact_sheets_population.aspx.
- Malkasian GD, Annegers JF, Fountain KS. Carcinoma of the endometrium:stage I. *Am J Obstet Gynecol.* 1980;136:872–88.
- Nasri MN, Shepherd JH, Setchell ME, Lowe DG, Chard T. The role of vaginal scan in measurement of endometrial thickness in postmenopausal women. *Br J Obstet Gynaecol.* 1991;98:470–5.
- Blumenfeld ML, Turner LP. Role of transvaginal sonography in the evaluation of endometrial hyperplasia and cancer. *Clin Obstet Gynecol.* 1996;39:641–55.
- Kim A, Lee JY, Chun S, Kim HY. Diagnostic utility of three-dimensional power Doppler ultrasound for postmenopausal bleeding. *Taiwan J Obstet Gynecol.* 2015;54:221–6.
- Moschos E, Bailey AA, Twickler DM. Comparison of saline infusion sonography(SIS) versus SIS-guided endometrial sampling in the diagnosis of endometrial pathology. *J Clin Ultrasound.* 2016;44:416–22.
- Rotenberg O, Renz M, Reimers L et al. Simultaneous endometrial aspiration and sonohysterography for the evaluation of endometrial pathology in women aged 50 years and older. *Obstet Gynecol.* 2015;125:414–23.
- Seshadri S, Khalil M, Osman A, Clough A, Jayaprakasan K, Khalaf Y. The evolving role of saline infusion sonography (SIS) in infertility. *Eur J Obstet Gynecol Reprod Biol.* 2015;185:66–73.
- Seçkin K, Karşlı M, Yücel B et al. The role of mean platelet volume on distinction of submucosal myomas from other etiologies in increased endometrial thickness. *Gynecol Obstet Reprod Med.* 2016;22:32–5.
- Dubinsky TJ, Parvey HR, Gormaz G, Curtis M, Maklad N. Transvaginal hysterosonography: comparison with biopsy in the evaluation of postmenopausal bleeding. *J Ultrasound Med.* 1995;14:887–93.
- O'Connell LP, Fries MH, Zeringue E, Brehm W. Triage of abnormal postmenopausal bleeding: a comparison of endometrial biopsy and transvaginal sonohysterography versus fractional curettage with hysteroscopy. *Am J Obstet Gynecol.* 1998;178:956–61.
- Moschos E, Ashfaq R, McIntire DD, Liriano B, Twickler DM. Saline-infusion sonography endometrial sampling compared with endometrial biopsy in diagnosing endometrial pathology. *Obstet Gynecol.* 2009;113:881–7.
- Wei AY, Schink JC, Pritts EA, Olive DL, Linheim SR. Salinecontrast sonohysterography and directed extraction, resectionand biopsy of intrauterine pathology using a Uterine Explora Curette. *Ultrasound Obstet Gynecol.* 2006;27:202–5.
- Yasa C, Dural O, Bastu E, Ugurlucan FG, Nehir A, Iyibozkurt AC. Evaluation of the diagnostic role of transvaginal ultrasoundmeasurements of endometrial thickness to detect endometrial malignancy in asymptomatic postmenopausal women. *Arch Gynecol Obstet.* 2016;294:311–16.
- Barut A, Barut F, Arikan I, Harma M, Harma MI, Ozmen Bayar U. Comparison of the histopathological diagnoses of preoperative dilatation and curettage and hysterectomy specimens. *J Obstet Gynaecol Res.* 2012;38:16–22.
- Demirkiran F, Yavuz E, Erenel H, Bese T, Arvas M, Sanioglu C. Which is the best technique for endometrial sampling? Aspiration (pipelle) versus dilatation and curettage (D&C). *Arch Gynecol Obstet.* 2012;286:1277–82.
- 18.Stock RJ, Kanbour A. Prehysterectomy curettage. *Obstet Gynecol.* 1975;45:537–41.
- Agostini A, Shojai R, Cravello L, Rojat-Habib MC, Roger V, Bretelle F, Blanc B. Endometrialbiopsy during outpatient hysteroscopy: Evaluation and comparison of two devices. *Eur J Obstet Gynecol Reprod Biol.* 2001;97:220–22.
- Bettocchi S, Ceci O, Vicino M, Marelo F, Impedovo L, Selvaggi L. Diagnostic inadequacy of dilatation and curettage. *Fertil Steril.*2001;75:803–05.
- Karasu A, Ates S, Gurbuz T, Sahin N, Takmaz T, Aydin S. A Clinico-pathological Study of transvaginal endometrial thickness measurement in asymptomatic postmenopausal patients and patients with postmenopausal bleeding. *Gynecol Obstet Reprod Med.* 2019;25:85–88.
- Budak M, Şentürk M, Akgöl S et al. Evaluation of the relationship between histopathological tissue diagnosis and endometrial thickness in cases with postmenopausal bleeding. *Gynecol Obstet Reprod Med.* 2016;21:81–5.
- Domingues AP, Lopes H, Diax I, De Oliveira CF. Endometrial polyps in postmenopausal women. *Acta Obstet Gynecol Scand.* 2009;88:618–20.
- Ferrazzi E, Zupi E, Leone FP, et al. How often are endometrial polyps malignant in asymptomatic postmenopausal women? A multicenter study. *Am J Obstet Gynecol.* 2009; 200(3):235.e1–6.
- Epstein E, Ramirez A, Skoog L, Valentin L. Dilatation and curettage fails to detect most focal lesions in the uterine cavity inwomen with postmenopausal bleeding. *Acta Obstet Gynecol Scand.* 2001; 80(12):1131–1136
- Svirsky R, Smorgick N, Rozowski U et al. Can we rely on blind endometrial biopsyfor detection of focal intrauterine pathology? *Am J Obstet Gynecol.* 2008;199:115.e1–3.
- Lev-Sagie A, Hamani Y, Imbar T, Hurwitz A, Lavy Y. The significance of intrauterine lesions detected by

- ultrasound in asymptomatic postmenopausal patients. *BJOG*. 2005;112:379-81.
28. Fernandez-Parra J, Rodriguez OA, Lopez CS, Parrilla FF, Montoya VF. Hysteroscopic evaluation of endometrial polyps. *Int J Gynaecol Obstet*. 2006;95:144-8.
29. Lieng M, Qvigstad E, Sandvik L, Jorgensen H, Langebrekke A, Istre O. Hysteroscopic resection of symptomatic and asymptomatic endometrial polyps. *J Minim Invasive Gynecol*. 2007;14:189-94.
30. Huang GS, Gebb JS, Einstein MH, Shahabi S, Novetsky AP, Goldberg GL. Accuracy of preoperative endometrial sampling for the detection of high-grade endometrial tumors. *Am J Obstet Gynecol*. 2007; 196(3):243.e1-5.
31. Widrich T, Bradley LD, Mitchinson AR, Collins RL. Comparison of saline infusion sonography with office hysteroscopy for the evaluation of the endometrium. *Am J Obstet Gynecol*. 1996;174:1327-34.
32. Soguktas S, Cogendez E, Kayatas SE, Asoglu MR, Selcuk S, Ertekin A. Comparison of saline infusion sonohysterography and hysteroscopy in diagnosis of premenopausal women with abnormal uterine bleeding. *Eur J Obstet Gynecol Reprod Biol*. 2012;161:66-70.
33. de Kroon CD, de Bock GH, Dieben SW, Jansen FW. Saline contrast hysterosonography in abnormal uterine bleeding: a systematic review and meta-analysis. *BJOG*. 2003;110:938-47.
34. Leone FPG, Carsana L, Lanzani C, Vago G, Ferrazzi E. Sonohysterographic endometrial sampling and hysteroscopic endometrial biopsy: a comparative study. *Ultrasound Obstet Gynecol*. 2007;29:443-8.
35. Mihm LM, Quick VA, Brumfield JA, Connors AF, Finnerty JJ. The accuracy of endometrial biopsy and salinesonohysterography in the determination of the cause of abnormal uterine bleeding. *Am J Obstet Gynecol*. 2002;186:858-60.
36. Metzger U, Bernard JP, Camatte S et al. Sono-Guided endometrial biopsy: comparison with hysteroscopy biopsy. *Gynecol Obstet Invest*. 2004;58:26-31.
37. Bingol B, Gunenc MZ, Gedikbasi A, Guner H, Tasdemir S, Tiras B. Comparison of diagnostic accuracy of saline infusion sonohysterography, transvaginalsonography and hysteroscopy in postmenopausal bleeding. *Arch Gynecol Obstet*. 2011;284:111-7.
38. Mathew M, Gowri V, Rizvi SG. Saline infusion sonohysterography—an effective tool for evaluation of the endometrial cavity in women with abnormal uterine bleeding. *Acta Obstet Gynecol Scand*. 2010;89:140-2.