

# Successful Primary Percutaneous Intervention to the Circumflex Artery Originating From Right Coronary Artery

*Sağ Koroner Arterden Çıkan Sirkümfleks Artere Başarılı  
Primer Perkütan Koroner Girişim*

**Serdal Baştuğ<sup>1</sup>, Abdullah Nabi Aslan<sup>1</sup>, Murat Can Güney<sup>2</sup>,  
Cenk Sarı<sup>1</sup>, Ahmet Göktuğ Ertem<sup>1</sup>**

<sup>1</sup> Atatürk Education and Research Hospital, Department of Cardiology, Ankara

<sup>2</sup> Yıldırım Beyazıt University, Faculty of Medicine, Department of Cardiology, Ankara

## Abstract

The incidence of coronary artery anomalies are reported in 1% to 2% of the population. Although their frequency is rare, these congenital anomalies are important due to their relation with myocardial infarction and sudden cardiac death. In this case, we presented a 56 years old male patient who has been admitted to our emergency service with acute posterior myocardial infarction and transferred to the catheterisation laboratory for the purpose of primary percutaneous coronary intervention. Coronary angiography revealed culprit lesion in anomalous circumflex artery originating from the proximal part of the right coronary artery and the patient was treated with successful primary angioplasty and stent implantation. ( *Sakarya Med J 2015, 5(4):236-239* )

**Keywords:** Coronary artery anomalies; Acute myocardial infarction; Percutaneous coronary intervention

## Özet

Koroner arter anomalilerin sıklığı toplumda %1-2 olarak bildirilmektedir. Sıklığı nadir olsa da bu tür konjenital anomaliler miyokard iskemisi ve ani ölüm ile ilişkili bulunduğundan önem arz etmektedir. Biz bu vakada acil servisimize akut posterior miyokard enfarktüsü ile gelen, primer perkütan koroner girişim amacıyla kateter laboratuvarına alınan ve koroner anjiyografide sağ koroner arterden köken alan sirkümfleks arterde total tıkanıklık saptanan, başarılı primer anjiyoplasti ve stent uyguladığımız 56 yaşında bir erkek hastayı sunduk. ( *Sakarya Med J 2015, 5(4):236-239* )

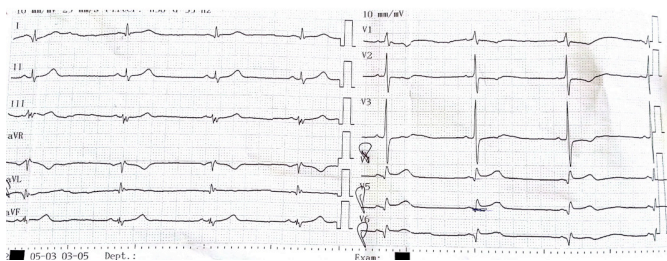
**Anahtar Kelimeler:** Koroner arter anomalileri; Akut miyokard enfarktüsü; Perkütan koroner girişim

## INTRODUCTION

The incidence of coronary artery anomalies have been vastly increased in the last decade due to the extensive use of coronary angiography as a diagnostic procedure. Some of these anomalies have been proven to be related with sudden cardiac death, angina pectoris, acute myocardial infarction and syncope<sup>1,2</sup>. Because of the difficulties encountered during the catheter cannulation, this kind of anomalies create a challenge for the clinicians even during elective coronary angiography (CAG) procedures. In this case report, we presented a 56 years-old male patient with the diagnosis of acute posterior myocardial infarction (MI), who has underwent successful primary percutaneous coronary intervention (PCI) of the culprit lesion in circumflex (Cx) artery which has been originating from the right coronary artery (RCA).

## CASE REPORT

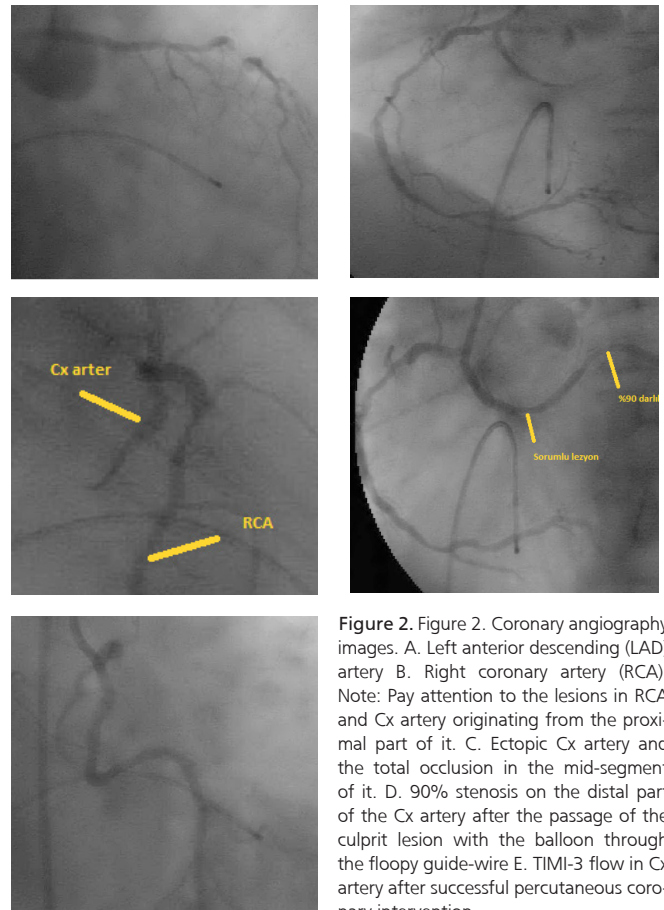
A 56 years old male patient admitted to our emergency room with the symptoms of chest pain localised in retrosternal area lasting for 2 hours and accompanied by nausea and vomiting. Medical history was unremarkable except for smoking history. Physical examination was normal. Electrocardiogram revealed 2 mm ST segment elevation in leads V1, V2, V3 and 2 mm ST segment depression in posterior derivations (Figure 1). Trans-thoracic echocardiography showed akinesis of the posterior wall and hypokinesis of the mid and basal segments of lateral wall and depressed left ventricular ejection fraction (45%).



**Figure 1.** Electrocardiogram showing ST segment elevation in V1-3 derivations

Patient was taken to the cardiac catheterization laboratory with the diagnosis of acute posterior MI for primary PCI. CAG showed normal left main coronary artery 80% stenosis at the level of diagonal (D) 1 and 30% stenosis at the level of D2 branches of left anterior descending artery together with absent Cx artery (Figure 2A). Right coronary angiography showed

the presence of multiple significant lesions in the RCA and its branches (Figure 2B) in addition to the anomalous origin of Cx artery from the proximal part of the RCA (Figure 2C). Primary PCI was planned to the culprit lesion in Cx artery. After the cannulation of Cx artery with right Amplatz 1 (AR1) guiding catheter, lesion was passed with 0.014 inch floppy guiding wire. After we pass through the lesion with a 2.0\*15 mm Simpass balloon, a 90% obstruction was detected just after the culprit lesion (Figure 2D). Predilatations were performed to the distal and culprit lesions respectively with the same balloon. After that, 3 in number drug eluting stents (one 2.5x18 mm and two 2.75x18 mm) were implanted starting from the distal lesion and proceeding to the proximal lesion. The procedure was ended after showing the complete filling of the distal vessel and TIMI-3 flow was maintained (Figure 2E). Then, the patient was transferred to the coronary intensive care unit. After 3 days of hospitalization, the patient was discharged from the hospital without any complications. (Informed consent was obtained from the patient.)



**Figure 2.** Figure 2. Coronary angiography images. A. Left anterior descending (LAD) artery B. Right coronary artery (RCA). Note: Pay attention to the lesions in RCA and Cx artery originating from the proximal part of it. C. Ectopic Cx artery and the total occlusion in the mid-segment of it. D. 90% stenosis on the distal part of the Cx artery after the passage of the culprit lesion with the balloon through the floppy guide-wire E. TIMI-3 flow in Cx artery after successful percutaneous coronary intervention

## DISCUSSION

The frequency of coronary artery anomalies in population is 0.6% to 1.3%<sup>3</sup> and have a tendency to increase with the widespread use of coronary angiography. Cx artery origin anomaly is a well defined entity and also one of the most common type of coronary anomalies seen in 0.37% to 0.7% of the patients. Cx artery typically originates from a separate ostium inside the RCA or as in this case from a proximal branch of the RCA<sup>4</sup>. In a study handled by Mavi et al and included over 10.042 patients, Cx artery origin anomaly was detected in 0.3% of patients undergoing CAG<sup>5</sup>. In this study, Cx artery has been shown to originate from left coronary sinus, right coronary sinus and proximal segment of the RCA in respectively 55.5%, 25.9% and 29.6% of these patients.

Although Cx artery origin anomaly is a safe and often asymptomatic coronary anomaly, sudden cardiac death, acute myocardial infarction and angina pectoris can be seen in small number of patients without any atherosclerotic lesions<sup>6</sup>. There is a limited technical experience in coronary angioplasty of this kind of patients anomaly especially when they present with acute MI. Balloon angioplasty and stent implantation is a convenient revascularization strategy in these patients and determinants of a successful primary coronary intervention are anatomic and angiographic knowledge of these anomalies, proper guiding catheter selection and successful crossing of the balloon through the vessel with anomaly<sup>7,8</sup>.

In our patient circumflex artery was originating from the proximal segment of the RCA and was totally occluded in the mid-segment. As the CAG revealed obstructive lesions in each of the three coronary arteries, primer PCI of the Cx artery was vital for the patient. As cannulation of the coronary anomalies is a challenging issue in clinical practice it is crucial for clinicians to know what to do especially in such a patient presented with acute myocardial infarction. In this case we cannulated the Cx artery with AR-1 guiding catheter and performed successful PCI saving the patient from increased risk of mortality in the early period after the acute MI.

## CONCLUSION

After the origin and tract of the coronary anomaly was determined in a patient presenting with acute MI, therapeutic

strategies should be regarded. For this reason anatomical variations of the coronary anomalies should be well known and taken into consideration during the CAG of the patients admitted with acute MI. In this case report we wanted to remind that if culprit lesion can not be detected in patients with acute MI, possibility of coronary anomaly existence should be kept in mind and primary PCI is feasible in patients with Cx artery originating from the right coronary artery.

## Conflict of interest:

None of the other authors have disclosures of potential conflicts of interest.

# References

1. Roberts WC, Siegel RJ, Ziges DP. Origin of the right coronary artery from the left sinus of valsalva and its functional consequences: Analysis of 10 necropsy patients. *Am J Cardiol* 1982;49:863.
2. Brand B, Martins JB, Marcus ML. Anomalous origin of the right coronary artery from the left sinus of valsalva. *N Eng J Med* 1983;309:596.
3. Page HL, Engel HJ, Campbell WB, Thomas CS. Anomalous origin of the left circumflex coronary artery. Recognition, angiographic, demonstration and clinical significance. *Circulation* 1974;50:768-773.
4. Rozenman Y. Anomalous origin of the circumflex coronary artery from the right sinus of Valsalva as a cause of ischemia at old age. *Clin Cardiol* 1993;16:900-901.
5. Mavi A, Serçelik A, Ayalp R, Pestemalci T, Batyraliev T, Gümüşburun E. Variants in origin of the left circumflex coronary artery with angiography. *Saudi Med J* 2002;23(11):1390-1393.
6. Corrado D, Penelli T, Piovesana P, Thiene G. Anomalous origin of the left circumflex coronary artery from the right aortic sinus of Valsalva and sudden death. *Cardiovasc Pathol* 1994;3:269-71. doi: 10.1016/1054-8807(94)90013-2.
7. Blanchard D, Ztot S, Boughalem K, Ledru F, Henry P, Battaglia S, Louali A, Nader R, Pagny JY, Guermonprez JL. Percutaneous transluminal angioplasty of the anomalous circumflex artery. *J Interv Cardiol* 2001;14:11-16. doi: 10.1111/j.1540-8183.2001.tb00704.x.
8. Angelini P, Velasco JA, Ott D, Khoshnevis GR. Anomalous coronary artery arising from the opposite sinus: descriptive features and pathophysiologic mechanisms, as documented by intravascular ultrasonography. *J Invasive Cardiol* 2003;15:507-514.