



■ Case Report

Primary ovarian pregnancy accurately diagnosed before the operation

Operasyon öncesi doğru şekilde tanı konulan primer ovaryan gebelik

Özde SAKARYA¹ , Derya ERDOĞAN² , *Hakan AY TAN¹ 

¹ Mersin Üniversitesi Tıp Fakültesi, Kadın Hastalıkları ve Doğum Anabilim Dalı

² Mersin Üniversitesi Tıp Fakültesi, Patoloji Anabilim Dalı

Abstract

The aim was to present a very rare case of primary ovarian pregnancy accurately diagnosed before the operation and treated successfully. A 26-year-old multiparous woman, at 9^{1/7} weeks gestation referred to the gynaecology department for a presumptive diagnosis of ectopic pregnancy. She had no complaints, and her physical examination was regular. Transvaginal ultrasound revealed a gestational-free uterus with a 7.5 mm endometrium stripe. A live crown-rump length (CRL) 19.2 mm (8^{3/7} weeks) embryo was detected just near the uterus, on the left adnexal region located on the left ovary. With informed consent, a mini-laparotomy was performed. Intraoperative findings revealed a 6 cm cystic lesion arising from the left ovary. During exploration, the lesion ruptured, and the pregnancy materials, including the embryo, were collected from the cul de sac. The remaining part of the ovarian pregnancy was removed with wedge resection. The histopathological examination confirmed the diagnosis. This case showed that transvaginal ultrasonography is helpful in early detection of primary ovarian pregnancy before any potential surgical emergency.

Key Words: Ovarian pregnancy; preoperative diagnosis; transvaginal ultrasonography

Öz

Amaç operasyon öncesi doğru şekilde tanı konulan ve başarılı şekilde tedavi edilen, nadir görülen bir primer ovaryan gebelik olgusunun sunulmasıdır. Yirmi altı yaşında 9^{1/7} haftalık gebeliği olan multigravid kadın hasta, olası ektopik gebelik ön tanısıyla jinekoloji departmanına başvurdu. Herhangi bir şikayeti yoktu ve fizik muayenesi normaldi. Transvajinal ultrasonografi ile gestasyonel kese içermeyen, 7,5 mm kalınlığında endometriyum gözlemlendi. Baş popo uzunluğu 19,2 mm olan (8^{3/7} hafta) canlı gebelik, uterusun hemen yanında, sol adneksiyal alanda tespit edildi. Hastadan onam alınarak minilaparotomi yapıldı. İntraoperatif bulgu olarak sol overden kaynaklanan 6 cm'lik kistik bir lezyon görüldü. Eksplorasyon esnasında lezyon rüptüre oldu ve gebelik materyali cul-de-sac'tan toplandı. Ovaryan gebeliğin kalan kısımları overden wedge rezeksiyon yapılarak çıkartıldı. Histopatolojik değerlendirme ile tanı kesinleşti. Bu vaka acil cerrahi durum oluşmadan önce transvajinal ultrasonografinin primer ovaryan gebeliğin erken tanısında faydalı olduğunu göstermektedir.

Anahtar Kelimeler: Ovaryan gebelik; preoperatif tanı; transvajinal ultrasonografi

Corresponding Author*: Hakan Aytan, Mersin Üniversitesi Tıp Fakültesi Hastanesi

E mail: drhakanaytan@yahoo.com

ORCID: 0000-0002-2553-7715

Received: 15.05.2020 Accepted: 06.06.2020

1. Introduction

Ovarian pregnancy is a sporadic event accounting for 0.15% of all pregnancies and 3% of all ectopic pregnancies (1). Ovarian pregnancies usually rupture by the 40th gestational day and if not treated, may cause significant complications (2). Diagnosis is challenging and is most frequently made at the surgery and requires histopathological confirmation. Here we report a case of un-ruptured primary ovarian pregnancy of 9^{1/7} weeks of gestation with no symptoms or physical examination findings that was correctly diagnosed before the operation and confirmed with pathologic examination.

2. Case report

A 26-year-old multiparous woman, at 9^{1/7} weeks gestation based on her last menstrual period, referred to the gynaecology department for a presumptive diagnosis of ectopic pregnancy. She was a gravida four para one, with a history of two spontaneous abortions. She had a vaginal delivery five years ago and had neither known systemic diseases nor any previous surgeries. Transvaginal ultrasound revealed a gestational-free uterus with a 7.5 mm endometrium stripe. A live CRL 19.2 mm (8^{3/7} weeks) embryo was detected just near the uterus on the left adnexal region located on the left ovary (**Figure 1a, 1b**). The contralateral ovary appeared unremarkable. There was a scant amount of free fluid in the cul de sac. The patient reported no complaints and her vital signs were within the normal limits. Her abdomen was non-tender. The pelvic examination revealed an anteverted, normal-sized, non-tender uterus and a left adnexal mass of 6 cm. No quantitative beta human chorionic gonadotropin (hCG) was measured as there was an apparent alive embryo. The haemoglobin and hematocrit levels were 13.8 g/dl and 39.8% respectively. A presumptive diagnosis of ovarian ectopic pregnancy was thought and discussed with the patient before the operation. With informed consent, a mini-laparotomy was performed as laparoscopy could not be done for technical reasons. Intraoperative findings revealed a 6 cm cystic lesion arising from the left ovary, adhered to the posterior side of the uterus. Both the tubes and the contralateral ovary were intact. During exploration, the lesion ruptured and the pregnancy materials, including the embryo, were collected from the cul de sac. The remaining part of the ovarian pregnancy was removed with wedge resection. The histopathological examination confirmed the diagnosis (**Figure 1c**). Post-operative recovery was uneventful, and the patient was discharged home after two days.

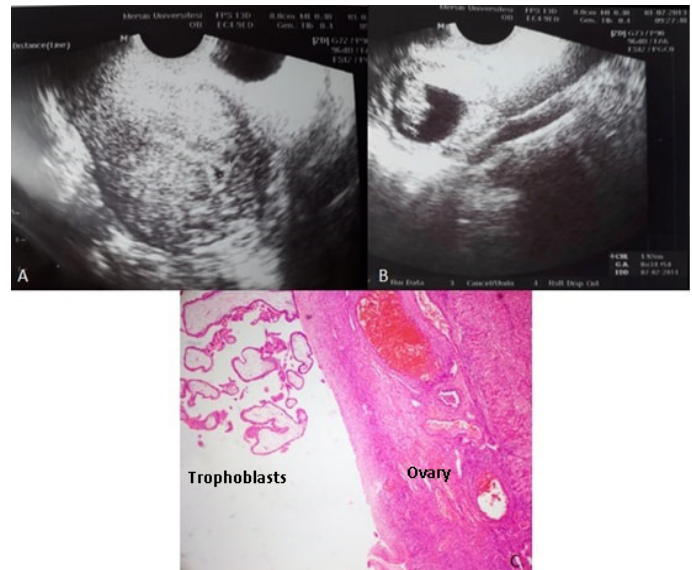


Figure 1. a. Pseudogestational sac in endometrial cavity; b. Ovarian ectopic pregnancy (A live CRL 19.2 mm (8^{3/7} weeks) embryo); c. Histopathological image of ovarian ectopic pregnancy with hemotoxylen-eosine staining.

3. Discussion

Ovarian pregnancy is classified into primary and secondary; the primary is mainly due to ovulatory dysfunction, where fertilization takes place within the follicle, whereas the latter is due to tubal abortion. In 1878, Spiegelberg formulated the diagnostic criteria for ovarian pregnancy as follows: Intact ipsilateral tube, clearly separate from the ovary, gestational sac occupying the position of the ovary, sac connected to the uterus by the ovarian ligament and histologically proven ovarian tissue located in the sac wall (3). Laparotomic and histopathologic findings fulfilled all these criteria in the present case.

It has been suggested that the incidence of primary ovarian pregnancy increases as a result of an increase in the detection rate with improving diagnostic tools such as transvaginal sonography, sensitive quantitative beta hCG measurements and diagnostic laparoscopic surgeries for suspected ectopic gestation (4,5). Transvaginal ultrasonography prompts the early diagnosis and may help in differentiating an ovarian pregnancy from other ectopic pregnancies. In their study, Comstock et al. assessed the ultrasonographic appearance of a proven ovarian ectopic pregnancies and showed a wide, echogenic ring with an internal echolucent area as compared to a thin tubal ring with tubal pregnancies or corpus luteum cyst; a yolk sac or fetal heart motion was also identified on occasion (6). Other reported sonographic findings of ovarian pregnancy include complex adnexal masses or solid-cystic masses, with or without fluid in cul de sac, fluid



surrounding the ovary, and ovarian enlargement (2). In the present case, the embryo was of 9^{1/7} weeks gestation and had normal growing pattern consistent with its gestation week. The left ovary could be visualized with the gestational sac. It should be kept in mind that there may be overlap between the ultrasonographic appearances of tubal pregnancies, corpus luteum and ovarian pregnancies (6) and therefore surgical exploration continues to be the gold standard diagnosis of primary ovarian pregnancy as it also enables a histological diagnosis (7).

Vaginal bleeding, abdominal pain and a palpable pelvic mass are considered to be the clinical triad of signs and symptoms (6). In cases of rupture, shock, syncope, dizziness, or shoulder pain may also be present. In the present case, the diagnosis was made before the rupture while the patient was still asymptomatic, and this prevented a surgical emergency.

The role of medical management in ovarian pregnancy remains controversial. There are reports suggesting that ovarian pregnancy can be treated with methotrexate like other ectopic pregnancies (8). However, we prefer to apply the consensus statement of The Practice Committee of the American Society for Reproductive Medicine on the medical treatment of women with primary ovarian pregnancies (7) that is a primary ovarian pregnancy can only be diagnosed definitively at the time of surgical exploration and if an invasive procedure is required to confirm the diagnosis, definitive surgical management should be accomplished at the same time (9), and therefore methotrexate is not a suitable first-line treatment for this condition.

Declaration of Interest

The authors report no conflict of interest.

References

1. Odejinmi F, Rizzuto MI, Macrae R, Olowu O, Hussain M. Diagnosis and laparoscopic management of 12 consecutive cases of ovarian pregnancy and review of literature. *J Minim Invasive Gynecol* 2009; 16:354-359.
2. Gupta N, Gupta A, Onyema G, et al. Accurate preoperative diagnosis of ovarian pregnancy with transvaginal scan. *Case Rep Obstet Gynecol*. 2012; 2012:934571.
3. Spiegelberg O. Zur casuistic der ovarial Schwangerschft. *Archiv f"ur Gynaekologie*. 1873; 13:73–76.
4. Hassan S, Arora R, Bhatia K. Primary ovarian pregnancy: case report and review of literature. *BMJ Case Rep Nov* 21;2012. pii: bcr2012007112
5. Riethmuller D, Sautière JL, Benoit S, Roth P, Schaal JP, Maillet R. Ultrasonic diagnosis and laparoscopic treatment of an ovarian pregnancy. A case report and review of the literature. *J Gynecol Obstet Biol Reprod (Paris)* 1996; 25:378-383.
6. Comstock C, Huston K, Lee W. The ultrasonographic appearance of ovarian ectopic pregnancies. *Obstet Gynecol* 2005; 105:42-45.
7. Practice Committee of the American Society for Reproductive Medicine. Medical Treatment of ectopic pregnancy. *Fertil Steril* 2006; 86:96-102.
8. Kudo M, Tanaka T, Fujimoto S. A successful treatment of left ovarian pregnancy with methotrexate. *Nihon Sanka Fujinka Gakkai Zasshi* 1988; 40:811-813.
9. Einenkel J, Baier D, Horn LC, Alexander H. Laparoscopic therapy of an intact primary ovarian pregnancy with ovarian hyperstimulation syndrome: case report. *Human Reprod* 2000; 15:2037–2040.