



Sabuncuoglu Serefeddin Health Science (SSHS)

ISSN: 2667-6338, 2020/Vol.2:2

ACUTE RENAL INFARCTION IN A PATIENT WITH COVID-19 RECEIVING WARFARIN THERAPY

¹Gokhan PERINCEK, ¹Canver ONAL, ^{*2}Sema AVCI

¹Kars Harakani State Hospital, Department of Pulmonology, Kars, Turkey

²Uşak University, Faculty of Medicine, Department of Emergency Medicine, Usak, Turkey

Case Report

Received: 24/07/2020, Accepted: 30/07/2020

*Corresponding author: dnzlsema@gmail.com

Abstract

Acute renal infarction is a rare clinical condition that usually occurs as a result of atherosclerosis, autoimmune diseases, hypercoagulability, atrial fibrillation and infectious diseases. In herein, we aimed to present a case of renal infarction in a 63-year-old male patient who was hospitalized due to COVID-19 infection, receiving warfarin therapy and had a high international normalized ratio (INR) value.

Key words: Renal infarction, COVID-19, Warfarin.

Özet

Akut renal infarkt genellikle ateroskleroz, otoimmün hastalıklar, hiperkoagulabilite, atriyal fibrilasyon ve enfeksiyon hastalıkları sonucu ortaya çıkan nadir görülen klinik bir durumdur. Burada, COVID-19 nedeniyle hastanede yatan, warfarin tedavisi alan ve yüksek INR değerine sahip 63 yaşındaki erkek bir renal infarkt olgusunu sunmayı amaçladık.

Anahtar kelimeler: Renal infarkt, COVID-19, Warfarin.

1. Introduction

Acute renal infarction is a rare clinical condition that usually occurs as a result of atherosclerosis, autoimmune diseases and hypercoagulability, and also particularly atrial fibrillation (AF) and hypercoagulability are well-known risk factors for renal infarction (Lee, et al., 2018). In addition to these risk factors, systemic or localized infections increase both venous and arterial thrombosis 2-20 times, such as myocardial infarction, cerebrovascular diseases, deep vein thrombosis and pulmonary embolism (Lee et al.,2016; Covarrubias et al., 2019). Increasing level of inflammation in this process, especially pneumonia, urinary tract infection, periodontitis, gingivitis and abdominal infections, increases the activation of the procoagulant phase and accelerates the occurrence of thrombus (Lee et al.,2016; Covarrubias, et al., 2019). The cases of arterial and venous thrombosis triggered by COVID-19 infection caused by coronavirus, which appeared in Wuhan city, China in December 2019, accepted as a pandemic by World Health Organization in March 2020, are reported (Tang et al., 2020).

In herein, we aimed to present a case of renal infarction in a 63-year-old male patient who was hospitalized due to COVID-19, receiving warfarin therapy and had a high international normalized ratio (INR).

2. Case

A 63-year-old male patient expressed a sudden onset of abdominal pain and flank pain on the sixth day of hospitalization while under follow-up with COVID-19. On the first lung computed tomography (CT) of the patient, ground glass opacities (GGOs) and consolidations were observed in the lung compatible with COVID-19. On physical examination, abdominal tenderness was detected in the patient's right upper quadrant. It was learned that the patient had a history of diabetes mellitus and AF, and using oral antidiabetic agent, beta blocker and warfarin. Vital and laboratory signs were as follow: blood pressure 130/80 mmHg, pulse 88 per/min, respiratory rate 20 per/min, oxygen saturation 88%, creatinine 1.17 mg/dL, aspartate aminotransferase 81 U/L, alanine aminotransferase 48 U/L, total bilirubine 0.72 mg/dL, direct bilirubin 0.49 mg/dL, c-reactive protein 82.9 mg/dL, d-dimer 3661 µgFEU/L (<500 reference value), procalcitonin 0.366 µg/L, troponin T 17.52 ng/L, lactate 2.4 mmol/L, white blood cell $9.85 \times 10^9/L$, hemoglobin 10.8 g/L, platelet $266 \times 10^9/L$, aPTT 58.7 sec (27-45 reference value), prothrombin time 51.5 sec (11-16 reference value), INR 4.02 (0.8-1.2 reference value), ferritin 157.9 ug/L, lymphocyte count $1.40 \times 10^9/L$. Any pathology was detected on the patient's abdominal ultrasonography, and additionally, lung and abdominal

tomography were performed due to persistent abdominal pain. A notable regression was detected in some areas of the GGOs and consolidations but some of them were still same as the initial CT findings (Figure 1).

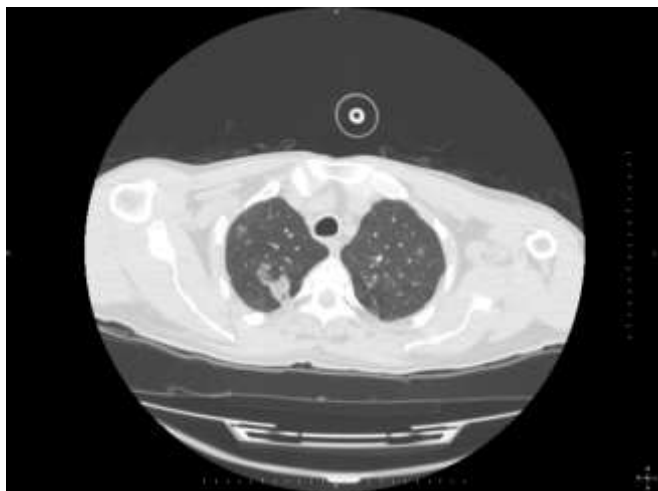


Figure 1. Ground glass opacities and consolidations were observed in the lung compatible with COVID-19

As newly developed imaging finding, right sided massive pleural effusion and concomitant compression atelectasis were recorded in the right hemithorax. In the left hemithorax, there was a moderate pleural effusion. An abdominal contrast enhanced CT was promptly performed. Contrast-enhanced CT images were taken at the nephrogram phase. The right kidney was small sized while the left kidney dimensions were normal. Main renal artery and its branches sized smaller compared to left ones. At the level of the right renal artery origin, there was stenosis due to atherosclerotic soft plaque. The findings were consistent with chronic right renal atrophic changes caused by the stenosis of the right renal artery. In addition to atrophy; CT demonstrated hypodense, non-enhanced corticomedullary areas in the middle one-third of right kidney (Figure 2). Some of the affected zone were seen as wide-wedge shaped, clearly demarcated areas while other areas were seen as ill defined, focal, peripherally located hypodensities. There was also a mild amount of peripheral and pelvic free fluid in the abdomen. The patient was diagnosed with acute renal infarction and warfarin treatment was stopped and low molecular weight heparin treatment was started. The patient is on the 15th day of hospitalization and his treatment continues.

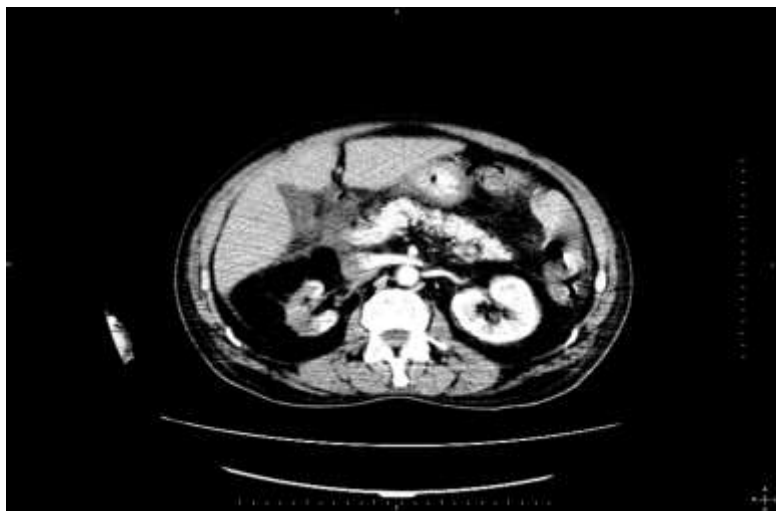

Figure 2. The right kidney was small sized while the left kidney dimensions were normal. Main renal artery and its branches sized smaller compared to left ones. CT demonstrated hypodense, non-enhanced corticomedullary areas in the middle one-third of right kidney. Some of the affected zone were seen as wide-wedge shaped, clearly demarcated areas while other areas were seen as ill defined, focal, peripherally located hypodensities.

3. Discussion

Renal infarction usually occurs as a consequence of a heart or aortic-induced thromboembolism, and also the most common disease causing this condition is AF (Eltawansy et al., 2020). This atrial dysrhythmia, which is also present in our patient, is the main risk factor for infarction. Sudden onset flank and abdominal pain are the most common symptoms of renal infarction, the incidence of this condition among patients with AF is 2%, and factors leading to hypercoagulability can increase the infarct possibility (Eltawansy et al., 2020). Infections caused by viruses such as varicella, variola, measles, dengue virus, ebola, influenza, hepatitis, human immunodeficiency virus and cytomegalovirus may lead to thrombus formation by targeting hemostasis and coagulation cascade (Covarrubias et al., 2019). Tissue factor expression occurs in mononuclear phagocytes that trigger coagulation system activation in virus-infected cell models, and in particular activated macrophage-associated fibrin deposits in the liver, spleen and kidney lead to inflammation-related thrombosis and cardiovascular complications (Geisbert, et al., 2003). In another cell model in which acute respiratory distress syndrome caused by influenza, platelet aggregation,

pulmonary microvascular thrombus, endothelial damage and hyperinflammatory cytokine response were shown (Short et al., 2014). Arterial and venous thrombosis cases associated with COVID-19, a new type of viral infection caused by coronavirus, are common, and this infection may cause prolongation of aPTT and prothrombin time, increase level of d-dimer and inflammatory markers such as interleukin-6, erythrocyte sedimentation rate, and c-reactive protein (Tang et al., 2020; Connors, et al.,2020). A widespread endothelial cell inflammation, dysfunction or endothelial surface abnormality, impaired blood flow, abnormal platelet activation, high level of von Willebrand factor, factor XI activation, thrombin and fibrin formation cause coagulopathy related to COVID-19 infection (Becker, 2020). As in our patient, aPTT and PT prolongation and increased d-dimer level may occur in coagulopathy associated with COVID-19, PTT and PT prolongation may be prolonged due to the use of a vitamin K antagonist for AF prophylaxis. In conclusion, we believe that using warfarin in thromboembolism prophylaxis in a patient with COVID-19 cannot prevent the formation of an arterial thrombus.

4. Conclusion

In conclusion, COVID-19 may cause coagulopathy and physicians should pay attention to patients with COVID-19.

Conflicts of interest

The authors declare that there are no potential conflicts of interest relevant to this article.

References

- Becker, R.C. (2020). COVID-19 update: Covid-19-associated coagulopathy. *J Thromb Thrombolysis*, 15: 1–14.
- Connors, J.M., Levy, J.H. (2020). COVID-19 and its implications for thrombosis and anticoagulation. *Blood*, 135 (23): 2033–40.
- Covarrubias, N.B., Toledo, M.P., Thomas, M.R., Henderson, I.R., Watson, S.P., Cunningham, A.F. (2019). Understanding infection-induced thrombosis: lessons learned from animal models. *Front Immunol*, 10: 2569.

- Eltawansy, S.A., Patel, S., Rao, M., Hassanien, S., Maniar, M. (2014). Acute renal infarction presenting with acute abdominal pain secondary to newly discovered atrial fibrillation: a case report and literature review. *Case Rep Emerg Med*, 981409.
- Geisbert, T.W., Young, H.A., Jahrling, P.B., Davis, K.J., Kagan, E., Hensley, L.E. (2003). Mechanisms underlying coagulation abnormalities in ebola hemorrhagic fever: overexpression of tissue factor in primate monocytes/macrophages is a key event. *J Infect Dis*, 188:1618–29.
- Short, K.R., Kroeze, E., Fouchier, R.A.M., Kuiken, T. (2014). Pathogenesis of influenza induced acute respiratory distress syndrome. *Lancet Infect Dis*, 14:57–69.
- Tang, N., Li, D., Wang, X., Sun, Z. (2020) Abnormal coagulation parameters are associated with poor prognosis in patients with novel coronavirus pneumonia. *J Thromb Haemost*, 18:844–47.
- Yang, J., Lee, J.Y., Na, J.Y., Lim, S.Y., Kim, M.G., Jo, S.K., et al. (2016). Risk factors and outcomes of acute renal infarction. *Kidney Res Clin Pract*, 35(2): 90–95.