

RESEARCH ARTICLE

Indicators of Isotretinoin-Induced Myopathy: Neutrophil/Lymphocyte Ratio, Cobb Angle of Spine

Densel Araç¹, Rukiye Güner²

¹Necmettin Erbakan University Meram School of Medicine, Department of Neurosurgery, Konya, Turkey

²Cumhuriyet University School of Medicine, Department of Dermatology, Sivas, Turkey

Received: 06 August 2020, Accepted: 03 December 2020, Published online: 31 December 2020

© Ordu University Institute of Health Sciences, Turkey, 2020

Abstract

Objective: There are many side effects of isotretinoin on the musculoskeletal system, liver, nervous system and dermatological side effects. To investigate usage and side effects of isotretinoin (13-cis retinoic acid), which is popularly recommended by dermatologists for the treatment of acne vulgaris, on young patients admitted to the hospital with severe low back and neck pains.

Methods: We evaluated 61 patients who, using isotretinoin for the treatment of acne vulgaris for an average of eight months, experienced cervical and lumbar pain between 2017-2019. The age range of patients was between 16 and 38 years, there were 45 female and 16 male patients. These patients used isotretinoin at a dose of 0.5-0.8 mg/kg/day for the treatment of acne vulgaris for about eight months. The patients were questioned about cervical and lower back pain, joint pain, muscle weakness, myoglobinuria, creatine phosphokinase (CPK), Visual Analog Scale (VAS), inflammation myopathy, neutrophil/lymphocyte ratio (Neu/Lymp ratio), and Cobb angle of the spine during monthly controls.

Results: The VAS and Neu/Lymp ratio, cervical and lumbar Cobb angles of the patients were statistically analyzed and the relationship between them was shown.

Conclusion: The Neu/Lymp ratio and Cobb angle of the cervical and lumbar spine should be considered as an alternative or additional parameter to diagnose drug-induced myopathy.

Key words: Cobb angle, Inflammation, Myopathy, Neu/Lymp ratio, Pain

Suggested Citation: Arac D. Guner R. Indicators of Isotretinoin-Induced Myopathy: Neutrophil/Lymphocyte Ratio, Cobb Angle of Spine. Middle Black Sea Journal of Health Science, 2020; 6(3):299-304.

Address for correspondence/reprints:

Densel Araç

Telephone number: +90 (544) 601 01 27

ORCID-ID 0000-0003-0616-8835

E-mail: denselarac@hotmail.com

DOI: 10.19127/mbsjohs.776897

Introduction

Isotretinoin (13-cis retinoic acid) is a synthetic vitamin A analog used in the treatment of resistant cystic acne that is not responsive to conventional treatments and isotretinoin shows its effectiveness by suppressing sebaceous glands (Layton, 2009). There are many side effects of isotretinoin on the musculoskeletal system, liver, nervous system and dermatological side effects (Scuderi et al, 1993; Neshor and Zuckner, 1995). Musculoskeletal side effects were reported as 15–20% in the literature (McLane, 2001). Since musculoskeletal side effects are not very common, cervical and lumbosacral myalgia complaints are not considered or neglected by clinicians; most of musculoskeletal side effects

disappear shortly after the drug is released (Cengiz et al., 2018). There are a few reports in the literature that isotretinoin is associated with inflammatory rheumatologic symptoms; for example, sacroiliitis and inflammatory myopathic back pain (Elias et al., 1991; Fiallo and Tagliapietra, 1996; Dincer et al., 2008).

Muscles constitute 45% of total body mass and skeletal muscles are responsible for 80% of total glucose uptake and over 30% of resting metabolic rate (Sameem and Semira, 2016). Because of these properties, muscles are vulnerable to the toxic effects of circulating drugs including isotretinoin.

In this study, new parameters with easy applicability and accessibility and auxiliary radiological examinations that can be used in the diagnosis and follow-up of cervical and lumbar myalgia caused by drug-induced myopathy were investigated.

Methods

We evaluated 61 patients who used isotretinoin for the treatment of acne vulgaris for about eight months and complained of lumbar and cervical pain between 2017 and 2019 retrospectively. 45 of 61 patients were female, 16 were male and the age range was between 16-38 years. These patients used isotretinoin at a dose of 0.5-0.8 mg/kg/day for about eight months to treat acne vulgaris. Liver and kidney function tests, complete blood count, creatine phospho-kinase (CPK), sedimentation and C-reactive protein (CRP), erythrocyte sedimentation rate (ESR), anti-nuclear anticor (ANA), and rheumatoid factor (RF) values were examined in monthly controls. Patients with a rheumatological disease such as sacroiliitis, seronegative arthritis, degenerative spinal disease such as cervical and lumbar disc hernias or operated on, for this reason, traumatic spinal injuries, malignancy, renal and liver failure, HIV-infected, endocrinopathy were excluded from this study. Patients were questioned about other drug usage inducing myopathic reactions such as statins, immune-suppressive agents, and antiviral agents during monthly follow-up periods, and patients using these drugs were excluded from the study. Neurological examination and spinal magnetic resonance imaging (MRI) of the patients included in the study were within normal limits.

Patients using isotretinoin experienced cervical and lumbar pain admitted to the neurosurgery clinic. We preferred to discontinue the isotretinoin treatment and follow up complaints of patients and no other medications such as non-steroidal anti-inflammatory drugs were given for the treatment of pain.

After the discontinuation of isotretinoin, complaints of the patients gradually decreased and disappeared at the end of the third month of the follow-up period. Visual Analog Scale (VAS), Complete blood count, liver and kidney function tests, CPK, and neutrophil/lymphocyte ratio examined during monthly control of the patients.

Cobb angles of the cervical and lumbar spine of the patients were made on lateral roentgenography at the admission to neurosurgery clinic and at the end of the third month after discontinuation of the drug, and obtained data were analyzed statistically.

Statistical analysis

Data analysis was performed using SPSS for Windows, version 20.0 (IBM Corp., Armonk, NY, USA), if the parametric test assumptions are not met in the evaluation of the data, the Kolmogorov-Smirnov test, Wilcoxon signed rank test, and Spearman correlation coefficient will be calculated and the level of error is 0.05 as received.

Results

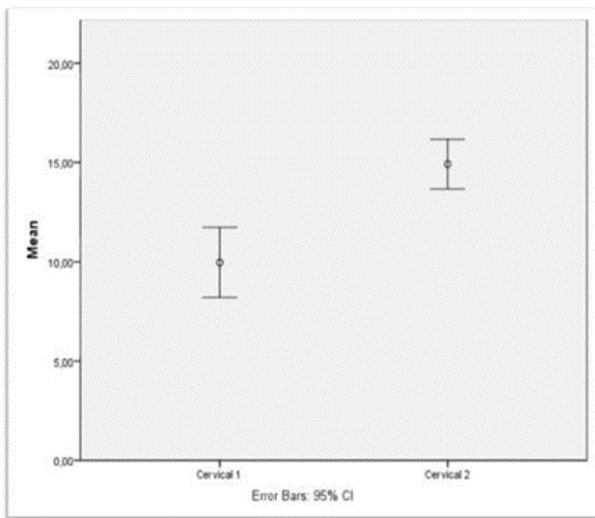
The relationship between the variables was tested with the Spearman correlation test: according to this; as lymphocyte (Lymp) increases, VAS decreases with a probability of 60.4%, as neutrophil (Neu) increases with a probability of 44.2%, VAS increases with a probability of 72.3%.

There was no significant relationship between creatine and VAS values. However, a significant positive correlation was found between Neu/Lymp and VAS values ($p < 0.05$, $r: 0,723$), as a result; the Neu/Lymp value increases, the VAS score increases, and the patient's symptoms increase (Table 1). There was a statistically significant difference between cervical and lumbar Cobb angle measurements (Wilcoxon signed rank test $p < 0,05$) performed on the day the patients applied to the clinic and at the end of the third month after isotretinoin discontinuation (graph 1,2).

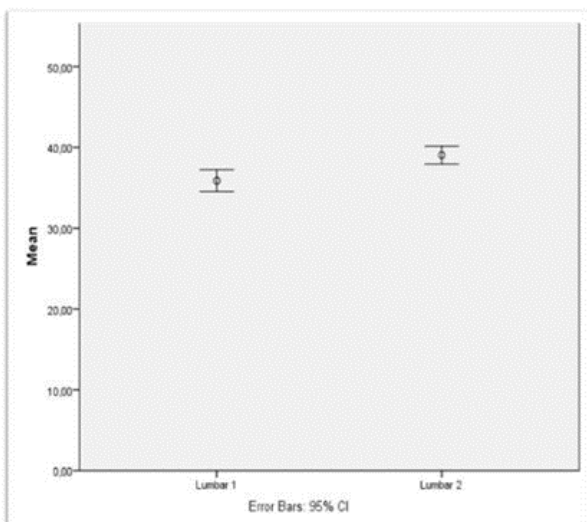
Table 1: Spearman correlation test results of data and VAS scores of the patients show a positive correlation between the VAS and the Neu/Lymp ratio

Variables	Max.	Min.	Mean	SD	Statistics	VAS
Creatine	1,18	0,51	0,76	0,141	r	0,051
					p	0,350
Lymp	4,12	0,83	2,39	0,6601	r	-,604**
					p	<0,001
Neu	8,2	1,86	4,08	1,378	r	,442**
					p	<0,001
Neu/ Lymp	5,75	0,56	1,85	0,923	r	,723**
					p	<0,001

** There was a significant correlation between values (r), and there is a significant relationship between the two variables p<0,05



Graph 1. Cervical 1 and lumbar 1: Cobb angles of cervical and lumbar spine at the admission day. (Wilcoxon signed rank test)



Graph 2. Cervical 2 and lumbar 2: Cobb angles of cervical and lumbar spine at the end of third month. (Wilcoxon signed rank test)

There were statistically significant differences between Cobb angles of spine (Cervical 1 versus Cervical 2, and Lumbar 1 versus Lumbar 2) p<0,05.

Discussion

Drug-induced myopathy is defined as a manifestation of myopathic symptoms such as muscle weakness, myalgia, creatine kinase (CK) elevation, or myoglobinuria that can occur in patients, who have not muscle disease, using specific drugs (Dalakas, 2009). There are many myotoxic drugs such as immunosuppressive agents (glucocorticoids), cholesterol-lowering drugs (statins), antivirals (interferons, clevudine), rheumatologic agents (antimalarials), and in this study, we investigated dermatologic agents (isotretinoin).

Isotretinoin induced musculoskeletal side effects can include myalgia, sacroiliitis, back pain, diffuse idiopathic skeletal hyperostosis, ligament and tendon calcifications, bone resorption, and attenuated collagen synthesis (Penniston and Tanumihardjo, 2006; DiGiovanna, 2001). Symptoms in patients may occur such as mild muscle pain and cramps to severe muscle weakness, resulting in rhabdomyolysis, renal failure, and death (Sameem and Semira, 2016). Myalgia and muscle stiffness were reported in 16-51% of patients with acne vulgaris treated with isotretinoin, and serum Creatine Kinase (CK) levels were found to be increased in 41% of these patients (Dicken, 1984; Heudes and Laroche, 1998; Janati, 2014). It is reported in the literature that exercise can increase serum CK levels in patients who use isotretinoin, as well as in all people (McBurney and Rosen, 1984), and also serum CK levels are normal in many patients with muscle pain and symptoms using isotretinoin (Fiallo and Tagliapietra, 1996; Hodak et al., 1986; Karagun 2019). Drug-induced myotoxicity is explained as multifactorial: brunt may be on muscle organelles, for example, mitochondria, lysosomes, and myofibrillar proteins; muscle antigens can be altered leading to inflammation or

immunologic reaction; nutritional and electrolyte imbalances may occur resulting in muscle dysfunction (Valiyil and Christopher-Stine, 2010). Isotretinoin-induced myalgia may be related to TRAIL-mediated muscle cell apoptosis (Bodo C. Melnik, 2017) (Figure 1). The nuclear FoxOs transcription factor can create an artificial starvation state on muscle metabolism and cause hemostasis to transform into catabolic events in the muscle cell, which may open the isotretinoin-induced myalgia mechanism (Melnik 2011) (Figure 2).

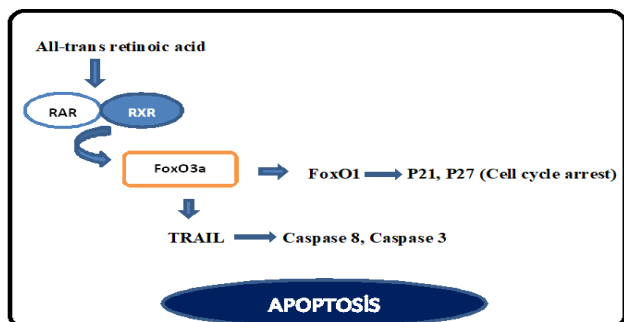


Figure 1. Mechanism of Isotretinoin-induced myopathy (apoptosis).

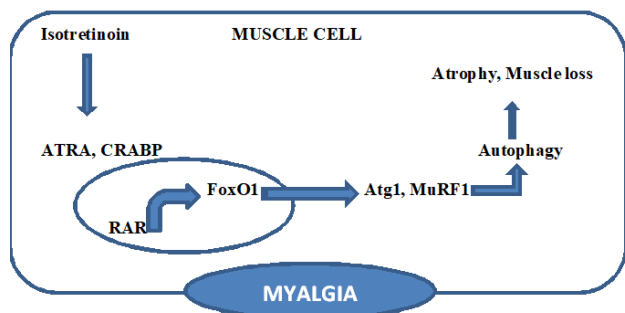


Figure 2. Mechanism of Isotretinoin-induced myopathy (myalgia)

Isotretinoin initiates an inflammatory cascade especially in the synovial membrane of joints like sacroiliac joint causing sacroiliitis reported by Aydog E et al., Dincer et al., Levinson et al. (Dincer et al., 2008; Levinson et al., 2012; Aydog et al., 2019). Many hypotheses suggest it affects immunomodulation and starts the inflammatory process by various mechanisms such as isotretinoin and cytokine balance alteration; the detergent-like effect of isotretinoin causes changes in lysosomal membrane structures, resulting in degeneration of synovial cells (Dincer et al., 2008). Levinson et al. (Levinson et al., 2012) indicated that retinoic acid can activate matrix metalloproteinase 2 (MMP-2), causing synovial membrane degradation in joints. In our study, patients using isotretinoin complained of cervical and lumbar pain because of myalgia, and no

evidence or examination of synovial membrane inflammation such as sacroiliitis, spondylarthritis, or facet joint hypertrophy was observed. Radicular pain examinations of our patients did not yield a positive result; besides, the pain was alleviated or completely disappeared in the follow-up periods after discontinuation of the drug.

Cases similar to our study, pain caused by isotretinoin are in the literature such as Alkan S. et al. in 2015 reported isotretinoin related spondyloarthropathy series that most common SpA symptoms were inflammatory back pain (Alkan et al., 2015). In a series of four cases reported by Pehlivan et al., isotretinoin-related inflammatory low back pain present and symptoms disappeared completely after drug discontinuation (Pehlivan et al., 2011). In these studies, lower back pain caused by the inflammatory process that could occur in the lower back muscles was emphasized.

In our study, patients using isotretinoin experienced cervical and lumbar pain caused by an inflammatory myopathic process in spinal muscles were reported, and none of our patients had concomitant sacroiliitis. Neurological examinations of the patients were within normal limits and no radicular pain was detected and there was a significant direct correlation between the Neu/Lymp ratio and the severity of myalgia. Inflammatory responses secondary to isotretinoin usage led to myalgia, causing cervical and lumbar pain. In contrast to the literature, myalgia because of isotretinoin was evaluated with neutrophil/lymphocyte ratio instead of CPK level which shows a myopathic inflammatory process and may show false positivity. In this study, we detected a relation between VAS of cervical and lumbar myalgia and Neu/Lymp ratio. After discontinuation of isotretinoin, the decrease of the inflammatory myopathic process occurred simultaneously with the decrease of the Neu/Lymp ratio.

Cobb angles of the cervical and lumbar spine of the patients showed a statistically significant difference between admission to the clinic and the end of the treatment. There was a decrease in lordosis of the cervical and lumbar spine according to normal limits on lateral roentgenography on the admission day, but there was an increase in lordosis of the cervical and lumbar spine and approaching normal limits on lateral roentgenography at the end of 3rd month after discontinuation of isotretinoin. While drug-induced myopathy is the main mechanism responsible for myalgia in the low back and neck, decreasing lordosis of the cervical and lumbar spine are another mechanism to produce pain in that area.

Myopathy related muscle weakness decreasing normal lordosis of cervical and lumbar spine could cause pain in the neck and lower back regions. There was a significant difference in the Cobb angles of the cervical and lumbar spine of the patients between admission day and the end of the third month after discontinuation of the drug. While the mean Cobb angle of the cervical spine was 9,96 \pm 6,82 degrees on the first day, the mean Cobb angle of the cervical spine was 14,91 \pm 4,84 at the end of the third month. The same event is seen on the lumbar spine, while the mean Cobb angle was 35,89 \pm 5,20 at first, the mean Cobb angle was 39,05 \pm 4,30 after discontinuation of the drug.

The differential diagnosis for toxic myopathies can be quite broad. Elevated CPK levels and muscle weakness and pain may indicate toxic myopathy, but endocrine disorders such as hypo/hyperthyroidism, hyperparathyroidism, muscular dystrophies such as limb-girdle muscular dystrophy, Becker's and Duchenne's muscular dystrophies, metabolic disorders such as glycogen or lipid storage diseases, mitochondrial myopathies, and exercise intolerance can elevate CPK levels and cause muscle weakness and pain mimicking drug-inducing myopathy (Valiyil and Christopher-Stine, 2010). Isotretinoin-induced myopathies can manifest as muscle weakness, increased CPK levels, myalgia, myoglobinuria, EMG, histologic changes and we want to add Neu/Lymp ratio as a new indicator for isotretinoin induced myopathy to the literature by this article. Because many metabolic disorders, endocrinologic diseases, and severe exercise can elevate CPK levels, to be more precise diagnose the isotretinoin-related myopathy, we want to discuss the efficiency of Neu/Lymp ratio in facilitating the diagnosing of isotretinoin induced myopathy causing cervical and lumbar pain.

Limitations in our article, evaluating isotretinoin as a meta-analysis in a larger number of patients, will enable us to get clearer results. The mechanism of the side effects of isotretinoin on the muscle is still unclear.

Conclusion

Isotretinoin causes severe low back and cervical pain. Patients should be well informed about the side effects of isotretinoin commonly used in the treatment of acne vulgaris and clinicians should be aware of side effect during follow-up periods.

In cases of cervical and lumbar pain seen as a side effect, inflammatory myopathic processes secondary to drug usage should be questioned before interventional procedures and radiological evaluation

of the patients. The Neu/Lymp ratio and Cobb angle of the lumbar and cervical spine should be considered as an alternative or additional parameter due to its ability to be applied and accessed as an alternative or additional parameter to muscle biopsy and CPK measurements performed for diagnosis and follow-up in drug-induced myopathy cases.

Ethics Committee Approval: This study was conducted with the approval of Cumhuriyet University Clinical Research Ethics Committee number 2019-02/22.

Peer-review: Externally peer-reviewed.

Author Contributions: Concept- RG, DA, Design- DA, Supervision- RG, DA, Analysis and/or Interpretation- RG, DA, Literature Review- DA, Writing- DA, Critical Review- DA.

Conflict of Interest: No conflict of interest was declared by the authors.

Financial Disclosure: The authors declared that this study hasn't received no financial support.

References

- Aydog E, Ozturk G, Comert A, Tasdelen N, Akin O, Geler Kulcu D. Sacroiliitis during isotretinoin treatment: Causal association or coincidence? *North Clin Istanbul* 2019;6(1):75–80. doi: 10.14744/nci.2018.93798
- Bodo Melnik. Isotretinoin and FoxO1, *Dermato-Endocrinology*, 2011;3:3, 141-165, DOI: 10.4161/derm.15331
- Cengiz AB, Ozyilmaz C, Tabaru A, Kayabasi S, Ege SS, Ruzgar S et al. Effects of oral isotretinoin on normal and wounded nasal mucosa: an experimental study. *European Archives of Oto-Rhino-Laryngology* 2018;275(12), 3025-3031, <https://doi.org/10.1007/s00405-018-5190-2>
- Dalakas MC. Toxic and drug-induced myopathies. *J Neurol Neurosurg Psychiatry*. 2009 Aug;80(8):832-8. doi:10.1136/jnnp.2008.168294.
- Dicken CH. Retinoids: a review. *J Am Acad Dermatol* 1984;11: 541-552. Doi: 10.1016/s0190-9622(84)70204-0
- DiGiovanna JJ. Isotretinoin effects on bone. *J Am Acad Dermatol*. 2001;45:S176-S182. Doi:10.1067/mjd.2001.113721
- Dincer U, Cakar E, Kıralp MZ, Dursun H. Can isotretinoin induce sacroiliitis: three cases. *Romatizma/Rheumatism* 2008;23:157-9.

- Ebru Karagun. The Effect of Isotretinoin-Induced Myalgia on Daily Quality of Life and Evaluation of Serum Creatine Phosphokinase Levels, *Van tıp Derg.*2019;26(4):452-455
doi:10.5505/vtd.2019.26918
- Elías LM, Gómez MI, Torrelo A, Boixeda JP, Ledo A. Acnefulminans and bilateral seronegative sacroiliitis triggered by isotretinoin. *J Dermatol* 1991;18:366-7. doi: 10.1111/j.1346
- Farah Sameem, Semira. Isotretinoin-induced acute severe myopathy involving pelvic girdle muscles: A case report. *Indian journal of pharmacology* 2016; 48(5), 601. doi: 10.4103/0253-7613.190764
- Fiallo P, Tagliapietra AG. Severe acute myopathy induced by isotretinoin. *Arch Dermatol* 1996;132:1521-2.
doi:10.1001/archderm.132.12.1521
- Heudes AM, Laroche L. [Muscular damage during isotretinoin treatment]. *Ann Dermatol Venereol* 1998;125: 94-97. PMID: 9747221
- Hodak E, Gadoth N, David M, Sandbank M. Muscle damage induced by isotretinoin. *Br Med J (Clin Res Ed)* 1986;293: 425-426. DOI: 10.1136/bmj.293.6544.425, doi: 10.1136/bmj.293.6544.425
- Janati A, Naif AG, Ghorbel S, Al-Emadi BA, Al-Shurtan KS,Alghassab AS et al. Pelvic Girdle Myopathy Caused by Isotretinoin: Case Report and Discussion of Pathophysiology. *J Clin Exp Pathol* 2014;4: 160. doi:10.4172/2161-0681.1000160
- Layton A. The use of isotretinoin in acne. *Dermatoendocrinology* 2009;1(3):162–169. doi: 10.4161/derm.1.3.93648138.1991.tb03100.x
- Levinson M, Gibson A, Stephenson G. Sacroiliitis secondary to isotretinoin. *Australas J Dermatol* 2012;53:298–300. doi: 10.1111/j.1440-0960.2011.00841.x.
- McLane J. Analysis of common side effects of isotretinoin. *J Am Acad Dermatol* 2001;45:S188eS194.
doi:10.1067/mjd.2001.113719
- Melnik BC. Apoptosis May Explain the Pharmacological Mode of Action and Adverse Effects of Isotretinoin, Including Teratogenicity. *Acta Derm Venereol.* 2017 Feb 8;97(2):173-181. doi: 10.2340/00015555-2535
- Nesher G, Zuckner J. Rheumatologic complications of vitamin A and retinoids. *Semin Arthritis Rheum* 1995;24:291e296.doi:10.1016/s0049-0172(95)80039-5
- Pehlivan Y, Kisacik B, Sayiner ZA, Onat AM. Inflammatory backpain in patients treated with isotretinoin. *J Rheumatol* 2011;38:2690. doi:10.3899/jrheum.110703
- Penniston KL, Tanumihardjo SA. The acute and chronic toxic effects of vitamin A. *Am J Clin Nutr.* 2006;83:191-201. DOI: 10.1093/ajcn/83.2.191
- Samet Alkan, Nuriye Kayiran, Orhan Zengin, Ali Kalem, Gezmis Kimyon, Emine Ozkul Kilinc et al. Isotretinoin-induced Spondyloarthritis-related Symptoms: A Prospective Study. *The Journal of Rheumatology* November 2015, 42 (11) 2106-2109;
doi:https://doi.org/10.3899/jrheum.150013
- Scuderi AJ, Datz FL, Valdivia S, Morton KA. Enthesopathy of the patellar tendon insertion associated with isotretinoin therapy. *J Nucl Med* 1993;34:455e457. PMID: 8441038
- Valiyil R, Christopher-Stine L. Drug-related myopathies of which the clinician should be aware. *Curr Rheumatol Rep.* 2010;12:213–20. doi: 10.1007/s11926-010-0104-3.