



ARAŞTIRMA / RESEARCH

Effect of tadalafil treatment on ovarian ischemia injury in rats

Tadalafil tedavisinin ratlarda over iskemi hasarına etkisi

Dilan Altıntaş Ural¹, Duygun Altıntaş Aykan², Sezen Koçarslan³, Adem Doğaner⁴

¹Kahramanmaraş Sütçü İmam University Faculty of Medicine, Department of Pediatric Surgery, ²Department of Pharmacology, ³Department of Medical Pathology, ⁴Department of Biostatistics and Medical Informatics, Kahramanmaraş Turkey

Cukurova Medical Journal 2021;46(1):55-62

Abstract

Purpose: Ovarian ischemia, which is known as one of the most common gynecologic surgery emergencies in women of all ages, is the disruption of the ovarian perfusion. Herein, we aimed to investigate the effect of tadalafil, a phosphodiesterase-5 inhibitor, at different doses and durations in the management of ovarian survival in ischemia-reperfusion injury model in rats. **Materials and Methods:** Thirty female Wistar albino rats were divided into five groups. Ovarian ischemia was induced by clamping the adnex of uterine tuba for three hours and reperfused for one hour. Drug treatments were given as follows: Group 1: saline (ischemic control), Group 2: tadalafil 1 mg/kg, Group 3: tadalafil 10 mg/kg, Group 4: tadalafil 1 mg/kg for 7 days, Group 5: tadalafil 10 mg/kg for 7 days. At the end of the treatments, ovaries were removed and evaluated for histopathological analysis. **Results:** Group 4 and Group 5 showed significant decrease in vascular congestion, hemorrhage, edema, neutrophilic infiltration compared to Group 1. All groups showed significant decrease in neutrophilic infiltration compared to Group 1. We found that treatment with tadalafil for 7 days significantly decreased the ovarian tissue damage scores in rats compared to the ischemic control.

Conclusion: Our results showed that tadalafil treatment in ischemic ovarian injury is effective in limiting ovarian damage. The reduction in the tissue damage scores suggested that treatment with PDE5 inhibitors, such as tadalafil, may contribute to the healing of conservatively treated ovaries and may play a role in the treatment of adnexal torsion.

Keywords: tadalafil, ovary, ischemia

Öz

Amaç: Her yaşta kadında en sık görülen jinekolojik cerrahi acil durumlarından biri olarak bilinen over iskemisi, yumurtalık perfüzyonunun bozulmasıdır. Sıçanlarda iskemi-reperfüzyon hasarı deneysel modelinde bir fosfodiesteraz-5 inhibitörü olan tadalafilin farklı doz ve tedavi süresinde over sağkalımı üzerindeki etkisini araştırmayı amaçladık.

Gereç ve Yöntem: Otuz dişi Wistar albino sıçan beş gruba ayrıldı. Yumurtalık iskemisi, tuba uterina adneksinin üç saat klemplenmesi ve bir saat reperfüze edilmesi suretiyle gerçekleştirildi. İlaç tedavileri şu şekilde verildi: Grup 1: salin (iskemik kontrol), Grup 2: tadalafil 1 mg / kg, Grup 3: tadalafil 10 mg / kg, Grup 4: tadalafil 1 mg / kg x 7 gün, Grup 5: tadalafil 10 mg / kg x 7 gün. Tedavilerin sonunda overleri çıkarıldı ve histopatolojik olarak değerlendirildi.

Bulgular: Grup 4 ve Grup 5'te, Grup 1'e kıyasla vasküler konjesyon, kanama, ödem ve nötrofilik infiltrasyon anlamlı derecede daha azdı. Tüm gruplar, Grup 1'e kıyasla nötrofilik infiltrasyonda anlamlı düşüş gösterdi. 7 günlük tadalafil tedavisinin iskemik kontrol grubu ile karşılaştırıldığında sıçanlardaki over doku hasarını belirgin derecede azalttığını tespit ettik.

Sonuç: Bu çalışmadaki sonuçlar overin iskemik hasarında tadalafil tedavisinin bu hasarını sınırlamada etkili olduğunu göstermiştir. Doku hasarı skorlarındaki azalma, tadalafil gibi PDE-5 inhibitörleri ile tedavinin konservatif olarak tedavi edilen overlerin iyileşmesine katkıda bulunabileceğini ve adneksiyal torsiyonun tedavisinde rol alabileceğini ortaya koymaktadır.

Anahtar kelimeler: tadalafil, over, iskemi

Yazışma Adresi/Address for Correspondence: Dr. Dilan Altıntaş Ural, Kahramanmaraş Sütçü İmam University Faculty of Medicine, Department of Pediatric Surgery, Kahramanmaraş Turkey E-mail: dilanaltintas@yahoo.com
Geliş tarihi/Received: 25.08.2020 Kabul tarihi/Accepted: 11.10.2020 Çevrimiçi yayın/Published online: 10.01.2021

INTRODUCTION

Ovarian torsion is the rotation of the ovary completely or partially on the ligamentous supports, often causing an ischemia due to the disruption of ovarian perfusion¹. This condition is one of the most important gynecological emergencies and it can be seen at any age. It constitutes 2.7% of abdominal pain in children and adolescents².

Rapid diagnosis is important to maintain the tubal functions and to prevent the associated morbidity since ischemia is a fatal clinical condition. Vascular and inflammatory events trigger each other, resulting in adhesion, migration and activation of leukocytes. During the reperfusion of the target tissue, increased level of the reactive oxygen species (ROS) and reactive nitrogen types (RNS) cause damage to membrane lipids, nucleic acids, enzymes and receptors in tissues³. Symptoms can be confused with other clinical diseases⁴.

Lymphatic drainage, venous flow and arterial circulation are interrupted due to the rotation of the infundibulopelvic ligament. Since venous vessels are more compressed than arteries, venous flow is disturbed firstly. Instead, blocked venous outflow leads to a significant ovarian enlargement and ovarian edema. Ovarian ischemia occurs later and may result in necrosis, infarction and local bleeding. Urgent intervention including adnexal distortion and ovarian preservation should be planned even in the case of a necrotic ovary⁵. In previous animal studies, the ovarian ischemia models were formed by placing vascular clamps on ovarian adnexa^{6,7}.

Tadalafil, a phosphodiesterase 5 (PDE5) inhibitor, is indicated in the management of benign prostatic hyperplasia, erectile dysfunction, and pulmonary artery hypertension. The role of tadalafil in these tissues involves PDE5 inhibition, leading a reduction in the proliferation of smooth muscle and endothelial cells, thus induction of smooth muscle relaxation and enhancement of perfusion⁸.

In our study, we hypothesized that tadalafil may lead to an improvement in ovarian tissue damage. We applied two different doses of tadalafil (1 mg / kg and 10 mg / kg) and two different period treatments (1 day and 7 days). We aimed to compare the therapeutic efficacy of tadalafil in the ischemic area in treatment groups and the control group.

MATERIALS AND METHODS

Experimental animals and housing conditions

This is an experimental study including thirty adult female Wistar rats, weighing 200–300 g. Rats were kept at 22°C temperature and 60±5% humidity with a 12 hours light/dark cycle during the experiment. Acclimatization to the study conditions was allowed for one week before the experiments. All experiments were conducted in strict accordance with the National Institutes of Health Guidelines for the Care and Use of Laboratory Animals. Experimental protocols were approved by the Local Animal Experimentation Ethics Committee (File no: 2019/03 Approval date: 08.02.2019).

Drugs

Tadalafil (Deparion®) was obtained from Abdi Ibrahim (Istanbul, Turkey). It was homogeneously dissolved in tap water. In 1 day and 7 day periods, 1 mg / kg and 10 mg / kg doses were administered to the rats by orogastric gavage. Tadalafil doses were based on the doses in the previous ischemia-reperfusion models^{9,10}.

Experimental design

A total of thirty female Wistar albino rats were subjected to the ovarian ischemia model. Firstly, the rats were anaesthetized with intramuscular injection of 50 mg/kg of ketamine hydrochloride (Ketalar®; Pfizer, Istanbul, Turkey)¹¹. The left ovary was clamped for 3 hours¹². At the end of the third hour, the clamp was opened and ovarian reperfusion was allowed for 1 hour. At the second hour of clamping, drug administration was carried out as follows:

- Group 1: saline (ischemia control),
- Group 2: tadalafil 1 mg/kg for 1 day (ischemia + T 1mg-1day)
- Group 3: tadalafil 10 mg/kg for 1 day (ischemia + T 10mg-1day)
- Group 4: tadalafil 1 mg / kg for 7 days (ischemia + T 1mg-7days)
- Group 5: tadalafil 10 mg / kg for 7 days (ischemia + T 10mg-7days)

Group 4 and Group 5 were kept alive for 7 days in sterile conditions, and were followed up for any contaminations. At the end of the experiment, rats were anesthetized with ketamine HCl (80 mg/kg i.p.)

and xylazine (10 mg/kg i.p.), and the left ovary was removed in all groups and evaluated histopathologically.

Surgical process

In all groups, ovarian ischemia model was formed before the administration of drugs. Rats were fixed to the operation table with dorsal supine position. The lower abdomen midline was shaved. A 2 cm longitudinal incision was made in the midline of the lower abdomen to reach the uterine horns. The torsion model was formed by attaching an atraumatic vascular clamp to the adnexa of the left uterine tube just proximal to the left ovary.

Ovarian ischemia was induced by clamping for 3 hours. At the end of the third hour, the vascular clamp was released and ovarian reperfusion was allowed for 1 hour. Subsequently, the left ovary was removed and evaluated histopathologically. The surgical incisions were closed using 3/0 silk sutures under sterile conditions. At the end of the experiment, the rats were sacrificed by cervical dislocation.

Evaluation of histopathological ischemic changes in ovarian tissue

Examination and scoring of the ovarian sections was performed blinded by the same pathologist. Histomorphological changes of ischemic ovarian damage were examined in five groups. Once the ovary was dissected, it was fixed in a 10% formalin solution for 24 hours. Subsequently, 4- μ m sections were stained with hematoxylin and eosin (H&E).

Tissue damage was evaluated histopathologically for vascular congestion, hemorrhage, edema and polymorphonuclear leukocyte infiltration. Five separate microscopic regions were examined for scoring of samples. Each sample was scored for the severity of histopathological changes: (0, no damage; 1, mild lesion; 2, moderate lesion; 3, severe lesion), as described by Melekoglu et al¹³.

Statistical analysis

The suitability of the data in the study to normal distribution was evaluated with the Shapiro-Wilk test. As a result of the evaluation, it was determined that

the data did not show normal distribution. Kruskal Wallis H test, which is one of the nonparametric statistical methods, was used to compare the groups for non-normally distributed data. Dunn-Sidak test was used for post-hoc binary comparisons. Statistics parameters were expressed in Median (min-max). Statistical significance was accepted as $p < 0.05$. Data were evaluated with IBM SPSS Statistics for Windows version 22 (IBM SPSS for Windows version 22, IBM Corporation, Armonk, New York, United States).

RESULTS

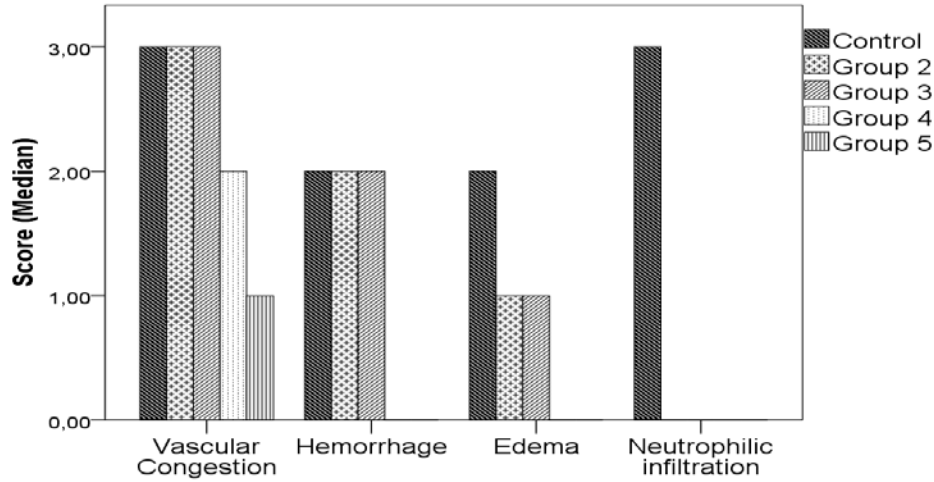
Macroscopically all ischemic ovaries were dark colored and hemorrhagic (Fig.1a). Tissue damage was evaluated histopathologically by parameters of vascular congestion, hemorrhage, edema, and polymorphonuclear neutrophil *leukocytes* (PMNL) infiltration. Histological scores of each group after ischemia is shown in Table-1.

In the ischemic control (saline) group, we found that vascular congestion was severe, hemorrhage was moderate (Fig. 1b), edema was moderate (Fig 1c), and neutrophil infiltration was severe (Fig. 2a). In both Group 2 (ischemia + T 1mg-1day) and Group 3 (ischemia + T 10mg-1day), we found that vascular congestion was severe, hemorrhage was moderate, edema was mild, neutrophil infiltration was not observed (Fig. 2b).

Ovaries of the animals that received tadalafil for 7 days (Group 4 and Group 5) showed significant decrease in vascular congestion, hemorrhage, edema, neutrophil infiltration compared to Group 1 ($p < 0.05$). We found that in Group 4 (ischemia + T 1mg-7days), vascular congestion was seen moderately, while hemorrhage, edema, neutrophil infiltration were not observed ($p < 0.05$) (Fig. 2c).

In Group 5 (ischemia + T 10mg-7days), vascular congestion was mild, while hemorrhage, edema and neutrophil infiltration were not observed ($p < 0.05$) (Fig. 2d) (Table 1 and 2). All groups showed significant decrease in neutrophil infiltration compared to Group 1 ($p < 0.05$). Hence, we found that treatment with tadalafil for 7 days resulted in a significant decrease in the tissue damage scores in rats when compared to Group 1 (ischemic control) ($p < 0.05$).

Table 1. Histological scores of each group after ischemia



Group 1: saline (ischemia control), **Group 2:** (ischemia + T 1mg-1day), **Group 3:** (ischemia + T 10mg-1day), **Group 4:** (ischemia + T 1mg-7days), **Group 5:** (ischemia + T 10mg-7days). Group 4 and Group 5 showed significant decrease in vascular congestion, hemorrhage, edema, neutrophilic infiltration compared to Group 1 ($p < 0.05$). All groups showed significant decrease in neutrophilic infiltration compared to Group 1 ($p < 0.05$).

Table 2. Comparison of histopathologic parameters among groups

	Control	Group 2	Group 3	Group 4	Group 5	p
	Med (Min-Max)	Med (Min-Max)	Med (Min-Max)	Med (Min-Max)	Med (Min-Max)	
Vascular congestion	3,00 (3,00-3,00) ^{d,e}	3,00 (3,00-3,00) ^{d,e}	3,00 (2,00-3,00) ^e	2,00 (1,00-2,00) ^{a,b}	1,00 (1,00-1,00) ^{a,b,c}	p<0.001
Hemorrhage	2,00 (2,00-3,00) ^{d,e}	2,00 (2,00-2,00) ^{d,e}	2,00 (1,00-2,00) ^{d,e}	0,00 (0,00-1,00) ^{a,b,c}	0,00 (0,00-0,00) ^{a,b,c}	p<0.001
Edema	2,00 (2,00-3,00) ^{d,e}	1,00 (1,00-2,00) ^{d,e}	1,00 (1,00-1,00) ^{d,e}	0,00 (0,00-0,00) ^{a,b,c}	0,00 (0,00-0,00) ^{a,b,c}	p<0.001
PMNL infiltration	3,00 (3,00-3,00) ^{b,c,d,e}	0,00 (0,00-1,00) ^a	0,00 (0,00-0,00) ^a	0,00 (0,00-1,00) ^a	0,00 (0,00-0,00) ^a	p<0.001

Kruskal Wallis H test; a: 0.05; Post-hoc: Dunn-Sidak Test; a: The difference between the control group is statistically significant; b: The difference between group 2 is statistically significant; c: The difference between group 3 is statistically significant; d: The difference between group 4 is statistically significant; e: The difference between group 5 is statistically significant. PMNL: Polymorphonuclear neutrophil leukocytes

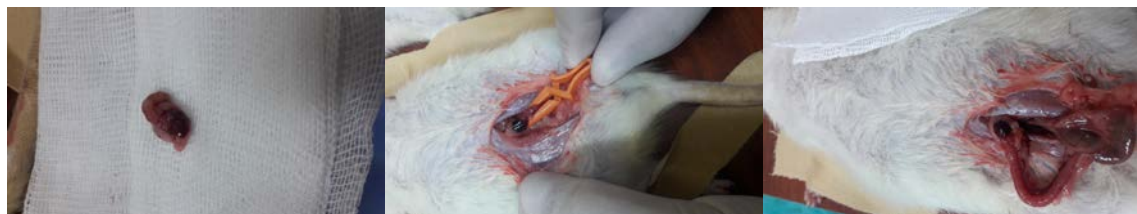

Figure 1: a. Macroscopically all ischemic ovaries were dark coloured and hemorrhagic. b. Ischemic area indicators in the ischemic control (saline) group. c. Group 1 after reperfusion.

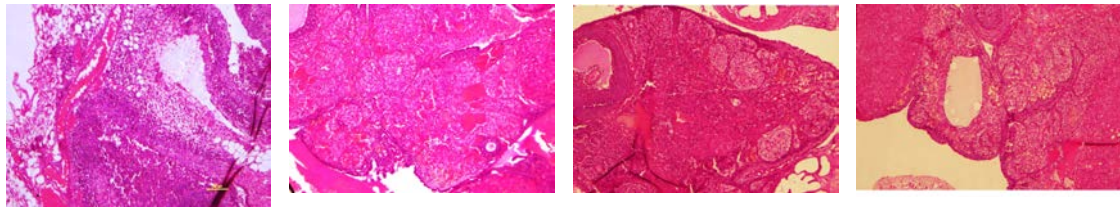


Figure 2. Pathological evaluation of groups with Hematoxylin & Eosin x100. a. In the ischemic control (saline) group, vascular congestion was severe, hemorrhage was moderate, edema was moderate, and neutrophilic infiltration was severe. b. In Group 2 and Group 3, vascular congestion was severe, hemorrhage was moderate, edema was mild, neutrophilic infiltration was not observed. c. In Group 4, vascular congestion was seen moderately, while hemorrhage, edema, neutrophilic infiltration were not observed ($p < 0.05$). d. In Group 5, vascular congestion was mild, while hemorrhage, edema and neutrophilic infiltration were not observed ($p < 0.05$).

DISCUSSION

In this experimental study, we showed that tadalafil 1 and 10 mg / kg for 7 days resulted in significant improvement compared to ischemic control ovaries. Tadalafil 1 mg/kg for 7 days caused a moderate vascular congestion, while hemorrhage, edema, neutrophil infiltration were not observed. In addition, tadalafil 10 mg/kg for 7 days caused mild congestion, while hemorrhage, edema, neutrophil infiltration were not observed.

The ovaries have arterial and venous blood flow. The arterial perfusion is maintained by the ovarian and the adnexal branches of the uterine arteries. If kinking of the pedicles or vascular disruption occurs, the venous flow diminishes initially. In advanced ischemia conditions, the arterial circulation in the ovary is reduced. Ovarian ischemia requires emergency management, and onset of intervention time is crucial for preserving ovarian functions and fertility. If early treatment cannot be applied, it usually requires oophorectomy. The diagnosis can be challenging in clinical practice despite advances in surgical and radiological techniques (14).

The degree of ovarian damage is strictly related to the time elapsed since cessation of vascular flow and onset of hypoxia. Once the ischemia begins, a number of events are triggered, such as vasoconstriction, epithelial cell necrosis, interstitial edema, calcium flow and depletion of adenosine triphosphate. After gaining circulation, damage to the ovarian cells progresses with the supply of oxygen to the tissue, which leads to the leukocyte activation, increased level of reactive oxygen species, dysfunction in mitochondria, and increased expression of endothelial adhesion molecules¹⁵. In

our study we induced ovarian ischemia by clamping on the tuba uterina for 3 hours. The vascular clamps were released at the end of the third hour so that ovarian reperfusion was allowed for 1 hour. In this case, reperfusion of ovaries after hypoxia can be effective in lesion formation. Inflammatory cells, edema and necrosis are histological indicators of acute ovarian ischemic injury⁹. Ischemia and reperfusion cause tissue damage through increased ROS levels and secretion of inflammatory factors. The severity of ischemic histological damage depends on two important factors: duration and degree of torsion¹⁶. ROS have been reported as a possible cause of ischemia reperfusion-induced damage. An increase in the ROS level leads to DNA damage and cell apoptosis. Therefore, many agents have been reported to prevent reperfusion injury after ovarian torsion / detorsion or ischemic / reperfusion, and the results have been evaluated histopathologically¹⁷.

When ischemia occurs, ATP concentration is decreased in cells due to the interruption in energy production. These cells start producing anaerobic energy. Subsequently, the increasing levels of intracellular lactic acid lowers the pH level of the cells. To prevent this, previous studies have shown that tadalafil reduced the histopathological damages related to the ischemia¹⁸.

Various endogenous mechanisms and several drugs exist to inhibit ischemic lesions. The mechanisms of ischemic injury protection are multifactorial and are still not clearly defined. There are studies determining that tadalafil decreased oxidative damage and had a protective effect in ovarian ischemia model^{18,19}. However, the results obtained in this study should be validated with more comparable models in terms of dose and drug administration periods. Hence, we

used 1 and 10 mg/kg tadalafil doses orally for different periods to evaluate the therapeutic drug efficacy in ovarian ischemia model in rats.

PDE5 inhibitors are previously evaluated in ischemia by their action in the maintenance of intracellular calcium at lower levels, smooth muscle relaxation and vasodilation¹⁹. Tadalafil, a novel therapeutic agent in the management of erectile dysfunction, is a potent, reversible and competitive inhibitor of phosphodiesterase 5 (PDE5). It inhibits the degradation of cGMP which acts mainly through activated protein kinase G (PKG). PDE5 inhibitors are effective through the NO-cGMP pathway, and are important to enhance the effect of endogenously released NO. In previous studies, tadalafil protected the testis tissue damage and replaced the testicular function by suppressing oxidative stress after testicular torsion²⁰. Tadalafil has a half-life of 17.5 hours and an effect time of 36 hours²¹. The reason we used a single dose of tadalafil in this study was because the drug has a long half-life. We also administered tadalafil for 7 days in comparison to the single dose in efficacy. On the other hand, the torsion of adnexa requires early diagnosis and emerging surgery. The estimated time after adnexal torsion for the ovaries not to lose their function is not clear. It is recommended that surgery should be performed within 8 hours after symptoms appear, but there are also surgeries performed 1-3 days after the symptom begins. In some clinical cases, it was stated that chronic adnexal torsion surgery was performed 9 days after the onset of symptoms²².

Tadalafil is available in oral pharmaceutical tablet forms for use in humans. Therefore, we gave the drug by orogastric gavage in our study. The reason for using Wistar albino rats in this study was the suitability and easy use of this species in imitating human physiology. The drug doses used in this study have been defined based on the basic studies for the evaluation of tadalafil in ischemia models. It was important to use as few animals as possible to detect histological changes that could be statistically significant. Previous studies have demonstrated diffuse edema, leukocyte infiltration, hemorrhage, and vascular congestion in ovarian tissue exposed to ischemic damage^{23,24}. In our study, we observed vascular congestion and an increase in ovarian damage score results in all ischemic groups consistent with previous studies. Because of the antioxidant and anti-inflammatory effects of tadalafil, a typical structure and decreased hemorrhage was observed in

the follicles after tadalafil administration. The decrease in hemorrhage and edema was significant in 7 days-tadalafil administration. However, the decrease in vascular congestion was only moderate.

A number of *in vivo* and *in vitro* studies have been conducted to examine the effects of PDE5 inhibitors on fertility parameters. Some of these studies have not shown any significant effect of PDE5 inhibitors on fertility. However, several studies have shown the positive activity of sildenafil on PDE5 isoforms and tadalafil on PDE11 isoforms²⁵.

As previously described, infiltration of inflammatory cells is one of the histological markers of acute ischemic damage. This study showed statistically significant less infiltration of leukocytes in the ovarian tissues in all tadalafil groups. Although the presence of leukocytes is part of the ischemic conditions, its role in injury or repair has not been clearly defined. Although leukocytes play a role in ischemic injuries and regeneration conditions, their exact role is unclear⁹. The findings of leukocyte infiltration in this study defined less local inflammation with tadalafil. The reduction in the leukocyte infiltrations was similar to the results of tadalafil use in ischemic experiments.

We should note the limitations of our study. One of our main limitations was the absence of biochemical analyzes in the blood parameters of animals in this experimental model. Confirming inflammation with blood parameters strengthens our work. Another limitation may be that this model we created in rats may not be exactly compatible with typical ovarian torsion cases frequently seen in clinical practice. No statistical significance was found in some histological parameters analyzed. However, in order to obtain more statistical strength, we may have better used a greater number of samples. On the other hand, our findings provide a basis for studies in the future. This study is a preliminary assessment showing that tadalafil has a histological effect on the ovarian tissue, due to differences in dosing and administration periods during the ischemic process. As tadalafil is a commonly used drug in clinics, it may be an alternative for the improvement of ovarian tissue.

In conclusion, our results showed that tadalafil treatment in ischemic ovarian injury in the rat model is effective for limiting ovarian damage. The reduction of tissue damage scores with tadalafil, a PDE5 inhibitor, indicates that this agent may contribute to the healing of the ovaries. In this case,

tadalafil may likely play a role in the treatment of adnexal torsion.

Yazar Katkıları: Çalışma konsepti/Tasarımı: DAU, DAA; Veri toplama: DAU, SK, AD; Veri analizi ve yorumlama: DAU, DAA, SK, AD; Yazı taslağı: DAU, DAA; İçeriğin eleştirilme: DAU, DAA; Son onay ve sorumluluk: DAU, DAA, SK, AD; Teknik ve malzeme desteği: DAU, SK; Süpervizyon: DAU, DAA; Fon sağlama (mevcut ise): yok.

Etik Onay: Bu çalışma için Kahramanmaraş Sütçü İmam Üniversitesi Tıp Fakültesi Hayvan Deneyleri Yerel Etik Kurulundan 19.02.2019 tarih ve 2019/01-03 sayılı kararı ile etik onay alınmıştır.

Hakem Değerlendirmesi: Dış bağımsız.

Çıkar Çatışması: Yazarlar çıkar çatışması beyan etmemişlerdir.

Finansal Destek: Yazarlar finansal destek beyan etmemişlerdir.

Author Contributions: Concept/Design : DAU, DAA; Data acquisition: DAU, SK, AD; Data analysis and interpretation: DAU, DAA, SK, AD; Drafting manuscript: DAU, DAA; Critical revision of manuscript: DAU, DAA; Final approval and accountability: DAU, DAA, SK, AD; Technical or material support: DAU, SK; Supervision: DAU, DAA; Securing funding (if available): n/a.

Ethical Approval: Ethical approval was obtained for this study from Kahramanmaraş Sütçü İmam University Faculty of Medicine Animal Experiments Local Ethics Committee with the decision dated 19.02.2019 and numbered 2019 / 01-03.

Peer-review: Externally peer-reviewed.

Conflict of Interest: Authors declared no conflict of interest.

Financial Disclosure: Authors declared no financial support

REFERENCES

1. Erturk N, Elbe H, Erdemli ME, Aktas S, Yigitturk G, Aksungur Z et al. Protective effects of sildenafil and resveratrol on ovarian ischemiareperfusion injury in rats. *Biomed Res.* 2017;28:9113-20.
2. Laganà AS, Sofo V, Salmeri FM, Palmara VI, Triolo O, Terzić MM et al. Oxidative stress during ovarian torsion in pediatric and adolescent patients: changing the perspective of the disease. *Int J Fertil Steril.* 2016;9:416-23.
3. Isik A, Peker K, Gursul C, Sayar I, Firat D, Yilmaz I et al. The effect of ozone and naringin on intestinal ischemia/reperfusion injury in an experimental model. *Int J Surg.* 2015;21:38e4439.
4. Dasgupta R, Renaud E, Goldin AB, Baird R, Cameron DB, Arnold MA et al. Ovarian torsion in pediatric and adolescent patients: A systematic review. *J Pediatr Surg.* 2018;53:1387-91.
5. Childress KJ, Dietrich JE. Pediatric ovarian torsion. *Surg Clin North Am.* 2017;97:209-21.
6. Yildirim N, Simsek D, Kose S, Yildirim AGS, Guven C, Yigitturk G et al. The protective effect of Ginkgo biloba in a rat model of ovarian ischemia/reperfusion injury: Improvement in histological and biochemical parameters. *Adv Clin Exp Med.* 2018;27:591-7.
7. Çalgın H, Şimşek M, Bal R. Can adnexal torsion be predicted by measuring plasma heat shock protein 70 level? An experimental study. *Arch Gynecol Obstet.* 2017;296: 941-6.
8. Altıntaş Aykan D., Yaman S. Tadalafil exerts a dual effect in behavioral pain responses in rats. *Ann Med Res.* 2020;27:749-54.
9. Wietzikoski EGG, Foiatto JC, Czezko NG, Malafaia O, Koleski FC, Mierzwa TC et al. Tadalafil protector effect during ischemia-reperfusion in rats. *Acta Cir Bras.* 2017;32:973-83.
10. Gasanov F, Aytac B, Vuruskan H. The effects of tadalafil on renal ischemia reperfusion injury: an experimental study. *Bosna J Basic Med Sci.* 2011;11:158-62.
11. Ural A, Bilgen F, Altıntaş Aykan D, Bahar AY, Bekerecioğlu M, Altıntaş Ural D. Effects of dabigatran and fondaparinux on degloving injuries: An experimental study. *Ulus Travma Acil Cerrahi Derg.* 2020;26:343-50.
12. Shokri F, Shokoohi M, Abadi ARS, Kalarestaghi H. The ameliorative effect of Galega officinalis extract on histological damages, oxidative stress induced by torsion-detorsion in adult rats' ovarian, *Int J Womens Health Reprod Sci.* 2019;7:119-23.
13. Melekoglu R, Ciftci O, Eraslan S, Alan S, Basak N. The protective effects of glycyrrhetic acid and chrysin against ischemia-reperfusion injury in rat ovaries. *Biomed Res Int.* 2018;2018:5421308.
14. Balasubramaniam D, Duraisamy KY, Ezhilmani M. Laparoscopic detorsion and fertility preservation in twisted ischemic adnexa a single-center prospective study. *Gynecol Minim Invasive Ther.* 2020;9:24-8.
15. Refaie MMM, El-Hussieny M. Protective effect of pioglitazone on ovarian ischemia reperfusion injury of female rats via modulation of peroxisome proliferator activated receptor gamma and heme-oxygenase 1. *Int Immunopharmacol.* 2018;62:7-14.
16. Shokoohi M, Soltani M, Abtahi-Eivary SH, Niazi V, Poor MJR, Ravaei H, Salimnejad R et al. Effect of hydro-alcoholic extract of *Olea europaea* on apoptosis-related genes and oxidative stress in a rat model of torsion/detorsion-induced ovarian damage. *Asian Pacific Journal of Reproduction.* 2019;8:148-56.
17. Malihe S, Maryam M, Hosein A, Majid S. The protective effect of *Matricaria chamomilla* extract on histological damage and oxidative stress induced by Torsion/Detorsion in adult rat ovary, *International Journal of Womens Health and Reproduction Sciences.* 2017;5:187-92.
18. Şahin Ç, Yıldırım N, Hortu İ, Akdemir A, Özşener S, Yigittürk G et al. Tadalafil attenuates ischemic damage as well as reperfusion injury in the rat ovary. *J Turk Ger Gynecol Assoc.* 2020;21:35-40.
19. Kumar S, Ashraf M. Tadalafil, a phosphodiesterase inhibitor protects stem cells over longer period against hypoxia/reoxygenation injury through STAT3/PKG-I Signaling. *Stem Cells Dev.* 2015;24:1332-41.
20. Mojtaba A, Mohaddesh S H, Maryam M, Majid S. Protective effect of tadalafil and verapamil on testicular function and oxidative stress after torsion/detorsion in adult male rat, *Andrologia.* 2018;50:e13068.
21. Elmadbouh I, Ashraf M. Tadalafil, a long acting phosphodiesterase inhibitor, promotes bone marrow stem cell survival and their homing into ischemic myocardium for cardiac repair. *Physiol Rep.*

- 2017;5:e13480.
22. Takeda A, Hayashi S, Teranishi Y, Imoto S, Nakamura H. Chronic adnexal torsion: An under-recognized disease entity. *Eur J Obstet Gynecol Reprod Biol.* 2017;210:45-53.
 23. Hortu I, Ozceltik G, Sahin C, Akman L, Yildirim N, Erbas O. Granulocyte colony-stimulating factor prevents ischemia/reperfusion-induced ovarian injury in rats: evaluation of histological and biochemical parameters. *Reprod Sci.* 2019;26:1389-94.
 24. Sipahi M, Gunaydin M, Kesicioglu T, Usta M, Yavuz BT, Tomruk C. A new approach to prevent ischemia/reperfusion injury in a rat model: remote ischemic conditioning. *Arch Gynecol Obstet.* 2019;299:1691-9.
 25. Cavallini G, Biagiotti G. The role of Tadalafil in treatment of infertility. *Asian Pacific Journal of Reproduction.* 2012;1:258-61.