

## AMYAND'S HERNIA IN PEDIATRIC AGE: A SINGLE SURGEON EXPERIENCE

### PEDİATRİK YAŞTA AMYAND HERNİSİ: TEK CERRAH DENEYİMİ

Yasemin DERE GÜNAL<sup>1</sup>

<sup>1</sup>Department of Pediatric Surgery, Kırıkkale University, Medical Faculty, Kırıkkale, Turkey

**Cite this article as:** Dere Günel Y. Amyand's Hernia In Pediatric Age: A Single Surgeon Experience. Med J SDU 2020; 27(3): 403-408.

#### Öz

##### Amaç

Amyand hernisi, inguinal herni kesesinde apendix vermiformisin varlığı ile karakterize nadir görülen bir herni türüdür. Çoğunlukla inkarsere inguinal herni ön tanısı ile ameliyat edilen hastalarda tesadüfen tanı konulur. Bu nadir patoloji hakkındaki deneyimin sunulması amaçlandı.

##### Gereç ve Yöntem

Bu çalışmada 2011-2017 tarihleri arasında tek bir çocuk cerrahı tarafından ameliyat edilen on Amyand hernili çocuk hastanın retrospektif bir analizi yapıldı. Hastaların demografik özellikleri (yaş, cinsiyet), başvuru şikayetleri, tedavi yöntemleri, histopatolojik bulguları ve postoperatif sonuçları değerlendirildi.

##### Bulgular

Amyand hernili tüm hastalar erkekti. Yaş ortalaması 12.02 aydı (17 gün-8 yaş). Hepsinde sağ inguinal herni mevcuttu. Hastaların 4'üne inkarsere inguinal herni ön tanısıyla acil cerrahi uygulandı. Geri kalan 6 hasta, elektif herni onarımı sırasında tesadüfen tanı aldı. Dokuz hastaya konvansiyonel herni onarımı yapıldı ve sadece bir hasta laparoskopi kullanılarak ameliyat edildi. Ameliyat bulguları 7 hastada normal apendiks ve 3 hastada inflame apendikti. Apendiksi fıtık kesesine yapışık olan 3 hastanın ikisinde inflame apandisit birinde lenfoid hiperplazi saptandı. Dört hastada inguinal herni onarımı sırasında apendektomi, diğer 6 hastada apendektomi yapılmadan herni onarımı yapıldı. Hiçbir hastada tekrarlayan fıtık görülmedi.

#### Sonuç

Sağ inguinal hernisi olan hastaların ayırıcı tanısında Amyand hernisi unutulmamalıdır. Fıtık kesesine yapışık apendiks inflamasyon durumu uygun bir tedavi kararı verebilmek için dikkatle değerlendirilmelidir.

**Anahtar Kelimeler:** Inguinal; Amyand hernisi; Çocuk; Apendektomi;

#### Abstract

##### Objective

Amyand's hernia is the presence of appendix in the hernia sac and rarely seen. The diagnosis is mostly made incidentally during the operation performed due to the incarcerated inguinal hernia. It is aimed to present the experience about this rare pathology.

##### Materials and Methods

A retrospective analysis of 10 children with Amyand's hernia operated by a single pediatric surgeon between 2011 and 2017 was performed. Demographic features (age, gender), complaints, treatment methods, histopathological findings and postoperative results were evaluated.

##### Results

All patients were male. The average age of patients was 12.02 months (17 days-8 years) and all had a right inguinal hernia. Emergency surgery was performed in 4 of the patients with an initial diagnosis of incarcerated inguinal hernia. The remaining 6 patients were diagnosed incidentally during elective hernioplasty.

İletişim kurulacak yazar/Corresponding author: drderegunal@yahoo.com,

Müracaat tarihi/Application Date: 15.07.2020 • Kabul tarihi/Accepted Date: 20.07.2020

ORCID IDs of the authors: Y.D.G. 0000-0003-4488-236X

lasty. While 9 patients were treated with conventional hernia repair, only one underwent laparoscopy. Surgical findings included 7 normal appendices ve 3 inflamed appendices. Of the 3 patients with appendix adhered to the hernia sac, 2 has appendicitis and 1 has lymphoid hyperplasia. Appendectomy was performed during inguinal hernia repair in 4 patients and hernia repair was performed in 6 patients without appendectomy. Recurrent hernias were not observed in any patients.

## Introduction

Amyand's hernia is an uncommon surgical pathology identified by the presence of normal or inflamed appendix vermiformis within the inguinal hernia sac (1 - 3). Claudius Amyand was the first to identify this pathology, by performing an appendectomy through the hernia in the groin area of a boy and entered the literature with his name (1). Amyand's hernia is considered to account for approximately 1% (0.19-1.7%) of all inguinal hernias. Appendicitis in the inguinal canal is rarer in all cases of acute appendicitis, with a rate of approximately 0.1% (0.07-0.13%) (4). Amyand's hernia is often reported in the right inguinal hernia sac as a result of the usual position of the appendix (2,4). It is much rarer in the left inguinal region and may be related to bowel malrotation or situs inversus, (5).

Preoperative diagnosis of Amyand's hernia is difficult. Patients usually present with tenderness and swelling in the groin area and are accidentally diagnosed with a complicated hernia (6). Sometimes it is detected unexpectedly during the repair of an inguinal hernia. (7). There is still controversy about, particularly, how to manage the normal-appearing appendices detected incidentally in the hernia sac during surgery. Some authors recommend only hernia repair without doing an appendectomy (2,8,9), while others prefer appendectomy in all patients (10,11).

Since Amyand's hernia is an uncommon clinical entity in children, there are not enough studies on large series. In this study, it was aimed to present the experience in the management of children with Amyand's hernia that was operated by a single pediatric surgeon.

## Materials and Methods

The study protocol was carried out with the approval of the ethics committee (2020.06.22). Ten children with Amyand's hernia who were operated between

## Conclusion

Amyand's hernia should be kept in mind in the differential diagnosis of patients with right inguinal hernia. The inflammation status of appendix adhering to the hernia sac should be carefully evaluated for an appropriate treatment decision.

**Keywords:** Inguinal; Amyand's hernia; Child; Appendectomy

January 2011 and April 2017 by a single pediatric surgeon were analyzed retrospectively. All patients with appendix within the hernia sac were included in this study. The demographic features (age, gender), complaints during admission, treatment methods, features of the surgery, if any, histopathological findings, post-operative results, length of hospital stay, and whether recurrent hernia or appendicitis developed during follow-up were evaluated.

## Results

During the study period, 886 children underwent inguinal hernia surgery and in 942 patients appendectomy was performed due to the diagnosis of acute appendicitis. Appendix was within the hernia sac in 10 of the patients. In this study, the incidence of Amyand's hernia among inguinal hernia patients was 1.1%. Acute appendicitis within the hernia sac was detected in 0.3% of patients who underwent appendectomy. Demographic data and clinical features of patients with Amyand's hernia are summarized in Table 1. All patients were male and had indirect right inguinal hernias. The mean age during surgery was  $12.02 \pm 29.7$  months (17 days - 8 years). The most frequent findings on physical examination were swelling in the right inguinal region, then, tender and irreducible swelling in the right inguinal region, abdominal pain and vomiting. Emergency surgery was performed in 3 of the patients due to incarcerated inguinal hernia and 1 of them due to acute abdomen. In remaining 6 patients, the appendix was found within the hernia sac incidentally and elective surgery was performed within 1 week after diagnosis.

No patients were diagnosed preoperatively. Two patients who admitted with incarcerated hernia had preoperative ultrasonography and reported as bowel loop with increased wall thickness expanding from the right inguinal canal to the scrotal area. Leukocytosis was observed in only one patient preoperatively. All patients underwent surgery under general anesthesia. In one patient with vomiting and tenderness

in the right lower quadrant with swelling in the right groin area, laparoscopy was performed due to initial diagnosis of acute abdomen. In laparoscopy, it was observed that the appendix was in the inguinal canal and adhered to the hernia sac and it was hyperemic and edematous. Laparoscopic appendectomy and repair of inguinal hernia was performed. Its pathology was reported to be lymphoid hyperplasia. In all remaining patients, a hernia sac was found by making a transverse inguinal incision and it was opened. If the appendix was adherent to the sac and hyperemic, patients underwent simultaneous appendectomy and high ligation of the hernia sac. If the appendix was

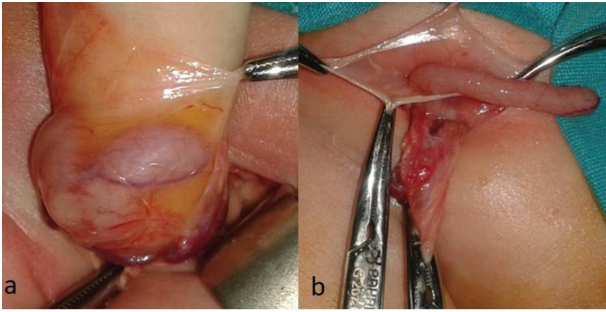
normal-looking and not adherent to the wall, it was reduced into the abdomen and a hernia repair was performed solely (Figure 1).

Appendectomy was carried out in 4 of the patients with Amyand's hernia. The appendix appeared macroscopically edematous and inflammatory in three of them (Figure 2). Their pathology report was acute appendicitis in two and lymphoid hyperplasia in one. In the other patient, the appendix looked normal, but the meso of the appendix was adhered so that it could not be separated from the sac wall (Figure 3). And the pathological diagnosis was acute appendicitis.

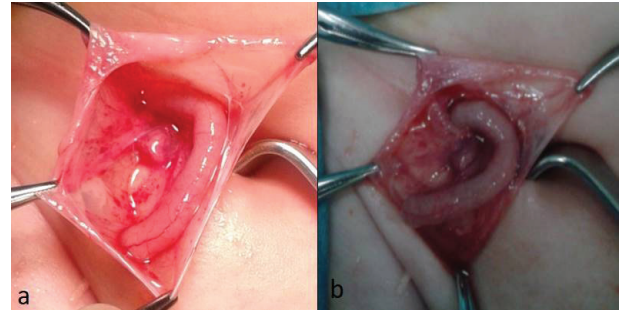
**Table 1** Demographic data and clinical features of patients

	Age	Gender	Side	Clinical presentation	Appearance of appendix	Surgery	Pathological result
1	30 days	M	Right	Groin swelling	Normal	Hernioplasty*	-
2	25 days	M	Right	Groin swelling	Adherent to sac wall, hyperemic, edematous	Appendectomy+ Hernioplasty	Acute appendicitis
3	35 days	M	Right	Groin swelling	Normal	Hernioplasty	-
4	2 months	M	Right	Groin swelling	Adherent to sac wall, normal	Appendectomy+ Hernioplasty	Acute appendicitis
5	30 days	M	Right	Groin swelling	Normal	Hernioplasty	-
6	50 days	M	Right	Groin swelling	Normal	Hernioplasty	-
7	8 years	M	Right	Groin swelling; vomiting; tenderness and defense in right lower quadrant; leukocytosis +	Adherent to sac wall, hyperemic, edematous	Laparoscopic appendectomy + Hernioplasty	Lymphoid hyperplasia
8	13 months	M	Right	Incarceration; tender and irreducible swelling in the groin	Normal	Hernioplasty	-
9	17 days	M	Right	Incarceration; tender and irreducible swelling in the groin, vomiting	Normal	Hernioplasty	-
10	3 months	M	Right	Incarceration; tender and irreducible swelling in the groin, vomiting	Non-adherent, inflamed, edematous	Appendectomy+ Hernioplasty	Acute appendicitis

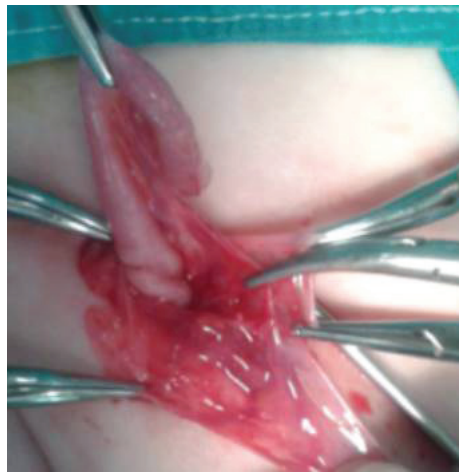\*Reduction of appendix into the abdomen and high ligation of inguinal hernia sac, M:Male



**Figure 1. a,b:**  
Normal-looking appendix within the hernia sac



**Figure 2. a:**  
Hyperemic and edematous appendix adherent to hernia sac, b; inflamated appendix in incarcerated hernia sac



**Figure 3:**  
Appendix meso is attached to the wall of hernia sac, appendix is normal-looking (however, the pathology revealed acute appendicitis)

The postoperative course was uneventful. Patients undergoing only hernia repair due to normal appendix were discharged on the same day. Patients who underwent appendectomy were discharged on the 3rd postoperative day. Postoperative wound infection did not develop in any of patients.

No recurrent hernia was encountered during the follow up of the patients. One patient presented to our clinic with acute abdominal pain 3 years later. Since the appendix looked normal at 50 days old and was not adherent to the sac, it was reduced into the abdomen and a hernia repair was performed. He was operated by another pediatric surgeon with a preliminary diagnosis of acute appendicitis, and the pathology was reported to be lymphoid hyperplasia. Appendicitis was not observed in the follow-up of other patients.

### Discussion

Inguinal hernia surgery is one of the most frequent pediatric surgery procedures in childhood. Inguinal

hernia is usually diagnosed upon a careful history taking and physical examination, without requiring radiological imaging (12). While the prevalence of inguinal hernia reported in premature infants ranged from 6.3% to 13.7% (13), this rate was reported to be 4.2% between the ages of 0-6 (14). Inguinal hernia is 10 times more often in boys and 3 times more often on the right side (15). As a consequence, Amyand's hernia is primarily seen on the right side and is more common in males and especially in infants. While Amyand's hernia constitutes for 1% of all adult inguinal hernia cases, it is estimated to account for only 0.1% of all appendicitis cases (16). The incidence in pediatric patients is not clear. In this study, the incidence of Amyand's hernia was 1.1%, and the rate of inflamed appendix within the hernia was 0.3%. These results emphasize that this clinical condition is rare.

Whether the relationship of Amyand's hernia with acute appendicitis is coincidental or related with incarceration and inflammation is still debated (9,17). It is generally accepted that as a result of the elevation

of abdominal pressure due to the abdominal muscle contraction, the appendix enters into the hernia sac, and in the advanced stage bacterial overgrowth and inflammation develop in the appendix by disruption of blood supply (18,19). According to the other theory, it has been suggested that manipulation of appendix during an attempt to reduce the incarcerated inguinal hernia can provoke secondary appendicitis, but no scientific evidence of this claim has been shown (1,20). In this study, this hypothesis is not supported, considering that there was no history of repeated manual reduction in two of 3 patients with appendicitis and 1 patient with lymphoid hyperplasia.

It has been published that patients diagnosed with Amyand's hernia usually present with a painful, irreducible mass in the groin area and are taken to emergency surgery with preliminary diagnosis of incarcerated or strangulated hernia (2,9). However, there are cases that have been detected incidentally during elective surgery who have no incarceration findings other than swelling in the right or left groin. In a study of 46 Amyand hernia patients, appendix was observed incidentally in the hernia sac in 37 patients without incarceration symptoms (7). In this study, similarly, Amyand's hernia was found incidentally in 6 patients without incarceration findings. In two of these patients, the appendix was too adhered to separate from the hernia sac and an appendectomy was performed. Although the appendix was appeared to be normal in one, the pathology results of both were reported to be acute appendicitis. The appearance of the appendix is a crucial factor for the appendectomy decision. However, sometimes it can be difficult to distinguish a normal or inflamed appendix macroscopically. Adhesion of the hernial sac to the appendix causes inflammation and impaired blood circulation (21). According to these, it should be remembered that acute appendicitis can be observed histopathologically, even if there are no clinical signs of intestinal obstruction, particularly in appendices adhering to the hernia sac, therefore, more attention should be paid when making the surgical decision.

The benefit of diagnostic imaging is debated for the diagnosis of inguinal hernia (22). It is difficult to identify Amyand's hernia preoperatively and usually occurs incidentally during operation. However, some authors suggest that radiological imaging may help diagnosing Amyand's hernia and give information about the status of the appendix within the hernia sac (23). Preoperative diagnosis can avoid manipulating the appendix within the hernia sac and aid to select the appropriate surgical approach, however, it is not used in routine management of inguinal hernias. In the liter-

ature, Amyand hernia was reported to be overlooked in most ultrasonographic examinations (24). In contrast, Okur et al. evaluated 21 patients with Amyand's hernia, and performed preoperative ultrasonography in 12 patients and reported that they diagnosed Amyand's hernia in 9 patients by showing a tubular structure that ended blindly in the inguinal canal (8). They suggested that the incidence of radiological diagnosis of Amyand's hernia can be increased by informing the radiologists about the Amyand hernia especially in patients with swelling in the right groin area (8). In this study, only two patients underwent preoperative ultrasonography, and both were reported as incarcerated bowel loops and could not be diagnosed. We do not use routine ultrasonography in inguinal hernias and this may prevent radiologists from gaining experience in this regard. Abdomino-pelvic computerized tomography is more useful method for direct imaging of the appendix in the hernia sac (25). However, since the aid of the preoperative diagnosis to the treatment decision is not clear, it is not appropriate to use tomography in routine practice due to the children being exposed to unnecessary radiation.

The optimum treatment of Amyand's hernia is still controversial. Treatment choices vary by the condition of the appendix and the existence of accompanying pathologies. In the presence of perforated or acute appendicitis, the most reasonable approach is to perform appendectomy and repair of hernia through the same incision (2,7,8,26). It is controversial whether an additional appendectomy is required when there is no findings of inflammation in the appendix. According to many authors, traumatization of the appendix in the hernia sac may start an inflammatory process and an appendectomy should be performed to eliminate the risk of acute appendicitis during life (20). Some others argued that the benefit of a prophylactic appendectomy has not been proven and should be evaluated only in appropriate cases (2,7). The appendix; since it is a frequently used organ in appendicocostomy, appendicovesicostomy and in some urinary and urethral procedures, it is recommended that the removal of a normal appendix should be avoided particularly in pediatric cases with a long life expectation (2,7,8,26). It seems logical to avoid incidental appendectomy unless absolutely necessary due to the possibility of being used in different reconstructive surgeries in the future.

Recent advances in minimally invasive surgery has made laparoscopic hernia repair more applicable in children. The laparoscopic treatment of Amyand's hernia facilitates the reduction of the hernia and provides an early diagnosis of ischemic appendix that

may be undetected and cause serious complications. Many authors have reported that laparoscopy was successfully used in the treatment of Amyand's Hernia (27-29). In this series, only one case underwent laparoscopy due to the signs of acute abdomen. Laparoscopic surgery is considered to have an effective role in the treatment of incarcerated inguinal hernia and is useful in determining unexpected disorders.

As a result, Amyand's hernia is an uncommon condition and should be kept in mind in the differential diagnosis of patients with right inguinal hernia. The choice of surgery varies depending on the existence of normal or inflamed appendix. An unnecessary appendectomy should be avoided in pediatric cases with a long life expectation. In particular, the inflammation status of appendix adhering to the hernia sac should be carefully evaluated and the treatment options should be decided accordingly. In addition, the laparoscopy appears to be an effective and safe procedure in pediatric cases with Amyand's hernia.

## References

- Hutchinson R. Amyand's hernia. *J R Soc Med.* 1993;86(2):104-5.
- Sharma H, Gupta A, Shekhawat NS, Memon B, Memon MA. Amyand's hernia: a report of 18 consecutive patients over a 15-year period. *Hernia.* 2007;11(1):31-5.
- Almetaher HA, Mansour MA, Arafa MA. Management of Amyand's hernia in children: should appendectomy be mandatory or not?. *Annals of Pediatric Surgery.* 2020;16:14. doi: 10.1186/s43159-020-00021-3
- Patoulias D, Kalogirou M, Patoulias I. Amyand's Hernia: an Up-to-Date Review of the Literature. *Acta Medica (Hradec Kralove).* 2017;60(3):131-4.
- Bakhshi GD, Bhandarwar AH, Govila AA. Acute appendicitis in left scrotum. *Indian J Gastroenterol.* 2004;23(5):195.
- Vermillion JM, Abernathy SW, Snyder SK. Laparoscopic reduction of Amyand's hernia. *Hernia* 1999;3:159-60.
- Cigsar EB, Karadag CA, Dokucu AI. Amyand's hernia: 11 years of experience. *J Pediatr Surg.* 2016;51(8):1327-9.
- Okur MH, Karacay S, Uygun I, Topcu K, Ozturk H. Amyand's hernias in childhood (a report on 21 patients): a single-center experience. *Pediatr Surg Int.* 2013;29(6):571-4.
- Cankorkmaz L, Ozer H, Guney C, Atalar MH, Arslan MS, Koyluoglu G. Amyand's hernia in the children: a single center experience. *Surgery.* 2010;147(1):140-3.
- Priego P, Lobo E, Moreno I, Sanchez-Picot S, Gil Olarte MA, Alonso N, et al. Acute appendicitis in an incarcerated crural hernia: analysis of our experience. *Rev Esp Enferm Dig.* 2005;97(10):707-15.
- Gurer A, Ozdogan M, Ozlem N, Yildirim A, Kulacoglu H, Aydin R. Uncommon content in groin hernia sac. *Hernia.* 2006;10(2):152-5.
- Lao OB, Fitzgibbons RJ, Cusick RA. Pediatric surgery pediatric inguinal hernias, hydroceles, and undescended testicles. *Surg Clin North Am.* 2012;92(3):487-504.
- Fu YW, Pan ML, Hsu YJ, Chin TW. A nationwide survey of incidence rates and risk factors of inguinal hernia in preterm children. *Pediatr Surg Int.* 2018;34(1):91-5.
- Pan ML, Chang WP, Lee HC, Tsai HL, Liu CS, Liou DM, et al. A longitudinal cohort study of incidence rates of inguinal hernia repair in 0- to 6-year-old children. *J Pediatr Surg.* 2013;48(11):2327-31.
- Ein SH, Njere I, Ein A. Six thousand three hundred sixty-one pediatric inguinal hernias: a 35-year review *J Pediatr Surg.* 2006;41(5):980-6.
- Michalinos A, Moris D, Vernadakis S. Amyand's hernia: a review. *The American Journal of Surgery.* 2014;207(6):989-95.
- Bar-Maor JA, Zeltzer M. Acute appendicitis located in a scrotal hernia of a premature infant *J Pediatr Surg.* 1978;13(2):181-2.
- Abu-Dalu J, Urca I. Incarcerated inguinal hernia with a perforated appendix and periappendicular abscess: report of a case. *Dis Colon Rectum.* 1972;15(6):464-5.
- Weber RV, Hunt ZC, Kral JC. Amyand's hernia. Etiologic and therapeutic implications of two complications. *Surg Rounds.* 1999;22:552-6.
- Ofili OP. Simultaneous appendectomy and inguinal herniorrhaphy could be beneficial. *Ethiop Med J.* 1991;29(1):37-8.
- Gündüz M. Amyand's Hernia in Children. *Haydarpaşa Numune Medical Journal.* 2018;58(1):45-7.
- Tisdale JB, Barwell NJ. Amyand's hernia and peri-appendicular abscess in primary care. *Hernia.* 2008;12(3):311-2.
- Celik A, Ergün O, Ozbek SS, Dökümcü Z, Balık E. Sliding appendiceal inguinal hernia: preoperative sonographic diagnosis. *J Clin Ultrasound.* 2003;31(3):156-8.
- Inan I, Myers PO, Hagen ME, Gonzalez M, Morel P. Amyand's hernia: 10 years' experience. *Surgeon.* 2009;7(4):198-202.
- Ash L, Hatem S, Ramirez GA, Veniero J. Amyand's hernia: a case report of prospective ct diagnosis in the emergency department. *Emerg Radiol.* 2005;11(4):231-2.
- Kaymakci A, Akillioglu I, Akkoyun I, Guven S, Ozdemir A, Gulen S. Amyand's hernia: a series of 30 cases in children. *Hernia.* 2009;13(6):609-12.
- Rehman MR, Panteli C, Tsang T. Laparoscopic repair of Amyand's hernia in an 8-week-old infant. *Hernia.* 2010;14(4):443-5.
- Tycast JF, Kumpf AL, Schwartz TL, Coln CE. Amyand's hernia: a case report describing laparoscopic repair in a pediatric patient. *J Pediatr Surg.* 2008;43(11):2112-2114.
- Li B, Zhang JY, Wang YB, et al. Laparoscope-assisted diagnosis and treatment for Amyand's hernia in children-report of six cases. *Pediatr Surg Int.* 2013;29(5):525-8.