

Investigation of Os Coxae in Horses Using Geometric Morphometry Method

Ozan GÜNDEMİR^{1, a}, Ermiş ÖZKAN^{1, b}, Nazan GEZER İNCE^{1, c}, Gülsün PAZVANT^{1, d}, İsmail DEMİRCİOĞLU^{2, e*}, Sedat AYDOĞDU^{3, f}, Ali KOÇYİĞİT^{3, g}, Mustafa Orhun DAYAN^{3, h}

¹Department of Anatomy, Faculty of Veterinary Medicine, İstanbul University-Cerrahpaşa, İstanbul, Turkey

²Department of Anatomy, Faculty of Veterinary Medicine, Harran University, Şanlıurfa, TURKEY

³Department of Anatomy, Faculty of Veterinary Medicine, Selçuk University, Konya, Turkey

^aORCID:0000-0002-3637-8166; ^bORCID: 0000-0002-5000-5075; ^cORCID: 000-0003-1627-5757; ^dORCID: 0000-0001-5986-3992; ^eORCID: 0000-0002-0724-3019; ^fORCID: 0000-0002-9354-3519; ^gORCID: 0000-0002-9354-7480;

^hORCID: 0000-0003-0368-4607

Geliş Tarihi: 29.09.2020

Kabul Tarihi: 07.12.2020

Abstract: In contrast to normal morphometric measurements, geometric morphometry is a method that can explain the differences and variations on the x-y coordinates of the specified points on a 2D plane. In this method, two-dimensional samples, such as pictures or x-rays, are used. The study aims to investigate the right os coxae of 23 adults (12 males, 11 females) horses geometrically. Photographs were taken from each sample at 120 centimeters distance and landmarks were made on these samples. 13 determining landmarks were used on os coxae. Medial endpoint of the narrowest section of the body of ilium and medial endpoint of ischial spine points were found to be statistically significant in terms of female and male distinction ($P < 0.001$). It was seen that the remaining points in the ventrolateral section did not have a statistically significant difference in gender discrimination. However, the difference between the genders in the ventral endpoint of coxal tuber and midpoint of coxal tuber in the dorsolateral section was statistically significant ($P < 0.001$). The difference between females and males is visually indicated using the morphology program. In females, it was observed that the points in the inner region are more lateral than males. Gender analysis studies can be conducted on materials such as bone using the morphometric results obtained as a result of such modeling studies.

Key words: Geometric analysis, Horse anatomy, Os coxae, Veterinary anatomy.

Geometrik Morfometri Yöntemi Kullanılarak Atlarda Os Coxae'larının İncelenmesi

Özet: Geometrik morfometri, normal morfometrik ölçümlerin aksine 2D düzlemde belirtilen noktaların x-y koordinatlarındaki farklılıkları ve varyasyonları açıklayan bir yöntemdir. Resim veya röntgen gibi iki boyutlu örnekler kullanılır. Bu çalışmada erişkin 23 (12 erkek, 11 dişi) tane atın sağ os coxae'sı geometrik olarak incelenmesi amaçlanmıştır. Her örnekten 120 santimetre uzaklıktan fotoğraflar alınmış ve bu örnekler üzerinden işaretlemeler yapılmıştır. Os coxae üzerinde 13 adet belirleyici nokta kullanılmıştır. Cinsiyet ayrımı bakımından, spina ischiadica'nın orta noktası ve ilium gövdesinin en dar bölümünün medial uç noktası arasında istatistiksel olarak anlamlı bir fark bulunmuştur ($P < 0.001$). Ventrolateral bölümde kalan noktaların cinsiyet ayrımında istatistiksel olarak anlamlı bir fark göstermediği görülmüştür. Bununla birlikte, cinsiyetler arasında tuber coxae'nin ventral son noktası ve dorsolateral bölümünün orta noktası istatistiksel olarak anlamlıydı ($P < 0.001$). Dişi ve erkekler arasındaki fark, morfoloji programı kullanılarak gösterildi. Dişilerde iç bölgedeki noktalar erkeklere göre daha yanal olduğu gözlemlendi. Bu modelleme çalışmaları sonucunda elde edilen morfometrik sonuçlar kullanılarak kemik gibi materyaller üzerinde cinsiyet analizi çalışmaları yapılabilmektedir.

Anahtar Kelimeler: Geometrik analiz, At anatomisi, Os coxae, Veteriner anatomi.

Introduction

Hip bone (os coxae) is the largest flat bone. It combines with the sacrum and the first caudal vertebrae and generates the pelvis (Dursun, 2006). Hip bone has important functions such as protects the reproductive organs and transmits movement from the hindlimb to the trunk (Ashdown and Done, 2001; König and Liebich, 2004). Also, the pelvis protects the caudal organs of the abdomen, particularly those of the urinary and intestinal tracts; nerves and vessels pass from the obturator foramen nutritive tissues and organs (Rebsamen et al., 2014; Colville and Bassert, 2015; Dyce et al.,

2016). Os coxae initially consist of three separate bones. Then they merge at the joint cavity called the acetabulum. Although the bones that fuse at a common point are called os coxae. They are called os ilium, os ischium, and os pubis to define their region (Bahadır and Yıldız, 2010; Colville and Bassert, 2015). The two os coxae join in the ventral and form the joint called symphysis pelvis. It forms two strong sacroiliac joints with the sacrum. Thus it is connected with columna vertebralis. Os ilium is the largest bone located in the dorsal, os ischium forms most of the pelvic cavity and the caudo-

ventral of this cavity. Os pubis is the smallest bone of os coxae and fuses with other os pubis (Konig and Liebich, 2004; Frandson et al., 2009; Bahadır and Yıldız, 2010).

Even though male and female pelvises are very similar to each other in the horses, there are some differences used to differentiate them. Pelvis diameters in females are larger than males. Ischial arch wider in females (Dursun, 2006). The reference information states that while the terminal line is egg-shaped in males, it is circular in females (Klingenberg, 2011). The floor of the pelvis section on the pubic bone is concave in females and flat in males (Bahadır and Yıldız, 2010).

Equine bone structure and function can be evaluated for clinical or research investigation of pathologic, pharmacologic, and physiologic processes. Noninvasive diagnostic techniques are reported but provide insufficient samples for assessment of bone architecture or measurements of remodeling and mineral apposition. Invasive bone biopsies remain the gold standard for quantitative assessment of bone remodeling by Allen (2013) and efforts have previously been made to find the least invasive method to obtain adequate bone samples from horses (Savage et al., 1991a; Savage et al., 1991b; Delguste et al., 2011; Allen, 2013). Samples must be large enough for the architecture to be undamaged by the biopsy technique, must provide enough tissue for multiple histologic sections to be examined, and be of sufficient quality to assess trabecular and cortical bone (Steiger et al., 1999).

In contrast to normal morphometric measurements, geometric morphometry is a method that can explain the differences and variations on the x-y coordinates of the specified points on a 2D plane. In this method, two-dimensional samples, such as pictures or x-rays, are used. It provides more information and results than the morphometric method (Aytekin, 2017). Reference points are determined on the pictures and statistical comments are made on these points. This method is used in many fields of science, primarily in anthropology (Bernal, 2007; Slice, 2007; Ozdemir et al., 2010). Anthropologists use some bones such as neurocranium and mandible with this method for the determination of gender, ancestry classification, and age variation in the human (Franklin et al., 2007; Maass and Friedling, 2019; Noble et al., 2019). In addition to these bones, os coxae is frequently used especially in gender determination studies. Besides gender determination, this method has examined the variations of os coxae belonging to individuals of the same gender, thus revealing the change in the pelvic cavity (Bytheway and Ross, 2010; Gonzales et al., 2017).

There are also studies of geometric morphometry in the science of veterinary anatomy. In a study conducted on the crania of the Anatolian Wild Sheep breed and the Akkaraman Sheep breed, the differences between these two breeds were examined (Yalçın and Kaya, 2009). In a study, the differences between wolf and German Shepherd's mandible bone and skull shapes were determined using geometric analysis (Gürbüz et al., 2020). Gender analysis was performed using photographs of turkey skulls and statistical differences were revealed (Gündemir et al., 2020). In another study, mandibular bones of the same breeds were examined via this method (Yalçın et al., 2010). In a different study, geometric morphometric studies were performed on three different rodent species (Yalçın et al., 2007). With this method, pelvis, hindlimb bones, and lumbar vertebrae of some mammal species have been analyzed (Álvarez et al., 2013). In the gray fox, the pelvis and cranium bones have been examined in terms of size and shape. Besides, the cranium has been analyzed with geometric morphometry in marmots and domestic dogs (Cardini et al., 2006; Schutz et al., 2009; Drake and Klingenberg, 2010). In a study conducted in *E. lutescens*, cranium and mandible have been examined with this method. The relationship between dogs and wolves using cranium by the geometric morphometric method has been examined (Geiger et al., 2017; Kaya et al., 2018).

The shape and morphological differences were examined with geometric morphometry in horses. Especially posture positions that give information about behavior, the phylogenetic, the population of, inter- or intra- individual levels in horses were investigated by using geometric morphometry (Cervantes et al., 2009; Fureix et al., 2011). With this method, using metacarpals and metatarsals of the horses living in ancient populations, mobility and migration of horses were revealed between the regions where the horses live (Bignon et al., 2005). Again in the fossil record of horses, dental morphology is the primary importance of taxonomic research was examined. Variations in tooth size and enamel patterns are considered to be too greatly influenced by age and continuous tooth wear. Thus, dental morphology has been a useful marker for horse domestication and is used in geometric morphometry. Generally, digital photographs are used in many geometric morphometric studies such as fossil record and phylogenetic. But recent years measurements are made using three-dimensional models in parallel with the developments in medical imaging and the increase in the use in veterinary medicine (Seetah et al., 2014; Danilo et al., 2015).

As a result of the study using geometric morphometry in Catalan Pyrenean horses; It is

stated that males were misclassified more than females and the iliac landmarks were contributed to the total variance of shape with a higher degree. According to the shape, the ischiopubic complex was contributed less to gender differentiation (Parés-Casanova, 2014)

The motivation of this study is that studies and knowledge on gender discrimination using hip bone in horses are limited. The study aimed to investigate the hip bones of the horses by using the geometric analysis method and to contribute to the literature knowledge. The variations between the specified points and individuals were revealed and the differences between the females and males were statistically examined.

Materials and methods

In the study, the right hip bones of 23 adults (12 males, 11 females) horses that were brought as dead to the Faculty of Veterinary Medicine, Istanbul University-Cerrahpaşa were used. The photographs of the bones were taken from a distance of 120 centimeters from the cranial by using Canon 650D machine. All the photographs were taken from the same perspective. The photographs obtained were transferred to the computer. To use the photographs in the marking program, tpsUtil32 (Version 1.74) program was used to make them suitable. Then, 13 landmarks were determined on the hip bone (Figure 1A). For the study, ethical approval was obtained from the Ethics Committee of Istanbul University-Cerrahpaşa Faculty of Veterinary Science (No: 2019/40).

The tpsDig232 (Version 2.30) program was used to make these markings (Rohlf, 2015). The photographs of each individual were marked separately. After these processes, the files were converted to a "text" extension for the statistical analysis of the data. Past (Version 2.17c) program was used to show the variations occurring between the points and the main components that were determinative of the variations between the individuals were obtained (Hammer et al., 2001) Also, the differences between the groups (male and female) were examined by this program. Then, the points causing the change are shown in Figure 1B by using the MorphoJ (Version 1.07a) program (Klingenberg, 2011). Via the MorphoJ program, the variations between the individuals were shown by symbols. Procrustes analysis was done using MorphoJ. Generate Covariance Matrix was applied to create a covariance matrix for essential components. "Principal Component Analysis" was done for the basic component analysis. Discriminant analysis was applied using MorphoJ to visualize gender differences.

SPSS program (SPSS for Windows, version 21.0) was used for statistical analysis. Differences between genders were tried to be statistically revealed by using multi-directional variance analysis (MANOVA) for "x" and "y" values located in the coordinate plane of each landmark. Whether there is a statistical difference is explained by the results of Wiks'Lambda. Bonferroni test was used because a different number of samples were used in the study. Covariance Matrices results are added to the study data to check that the preliminary assumption has been fulfilled.

Results

Twenty-two main components were obtained by using the Past program and they were shown in Table 1. The first main component alone accounted for 22.22% of the variation between the individuals. The first five main components accounted for 72.39% of the total variation. Variations between males and females were also examined by using these main components. In a 95% confidence interval, the difference between the genders by using the main components 1 and 2 was shown via

Table 1. Principal component analysis (Past).

Main Component	Eigenvalues	% Variation
1	0.000722933	22.22
2	0.000540385	16.609
3	0.000440521	13.54
4	0.000361551	11.113
5	0.000289715	8.9046
6	0.000202508	6.2243
7	0.000174036	5.3491
8	0.000125743	3.8648
9	0.000107864	3.3153
10	8,21909E-05	2.5262
11	5,93202E-05	1.8233
12	4,75675E-05	1.462
13	3,55616E-05	1.093
14	2,00077E-05	0.61495
15	1,82972E-05	0.56238
16	1,05775E-05	0.32511
17	7,54557E-05	0.23192
18	3,72153E-05	0.11438
19	2,48869E-05	0.076492
20	9,37875E-05	0.028826
21	5,81609E-05	0.0017876
22	1,62428E-05	4,9924E-29

geometric morphometric analysis in Figure 2. In the coordinate system, only one female was found to be in the negative region on x coordinates. It was observed that all of the male individuals were in the negative region according to the x coordinates. As in the confidence interval ellipse, it was observed that 7 females were exactly separated from the males with these values. According to the first two

Table 2. Statistical differences among landmarks in the coordinate plane between gender (MANOVA).

Landmarks	Covariance Matrices	Sex	
		F	Significant
Ventral endpoint of coxal tuber	0.258	11.177	0.001
Midpoint of coxal tuber	0.852	7.565	0.004
Dorsal endpoint of coxal tuber	0.185	0.051	0.950
Midpoint of iliac crest	0.657	7.267	0.004
Dorsal endpoint of sacral tuber	0.059	5.796	0.010
Medial endpoint of the narrowest section of body of ilium	0.666	12.926	0.000
Medial endpoint of ischial spine	0.089	16.737	0.000
Caudo-dorsal endpoint of pelvic symphysis	0.009	7.253	0.004
Cranio-ventral endpoint of pelvic symphysis	0.70	1.521	0.243
Extreme point of ischial tuberosity	0.403	0.736	0.492
Ventral endpoint of acetabulum	0.136	0.287	0.753
Dorsal endpoint of acetabulum	0.975	0.281	0.758
Lateral endpoint of the narrowest section of body of ilium	0.764	0.276	0.761

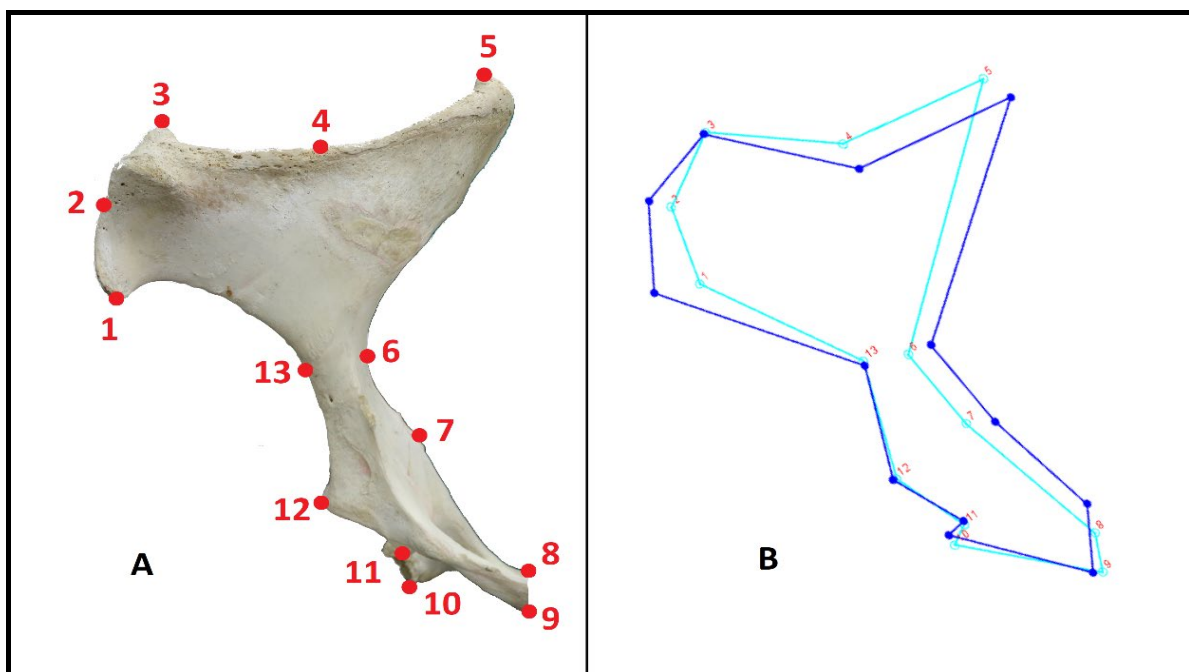


Figure 1. A: Marking points taken on hip bone; (1) Ventral endpoint of coxal tuber; (2) Mid end of coxal tuber; (3) Dorsal endpoint of coxal tuber; (4) Midpoint of iliac crest; (5) Dorsal endpoint of sacral tuber; (6) Medial endpoint of the narrowest section of body of ilium; (7) Medial endpoint of ischial spine; (8) Caudo-dorsal endpoint of pelvic symphysis; (9) Cranio-ventral endpoint of pelvic symphysis; (10) Extreme point of ischial tuberosity; (11) Ventral endpoint of acetabulum; (12) Dorsal endpoint of acetabulum; (13) Lateral endpoint of the narrowest section of body of ilium. **B:** Linear presentation of the shape differences for the first principal component (MorphoJ).

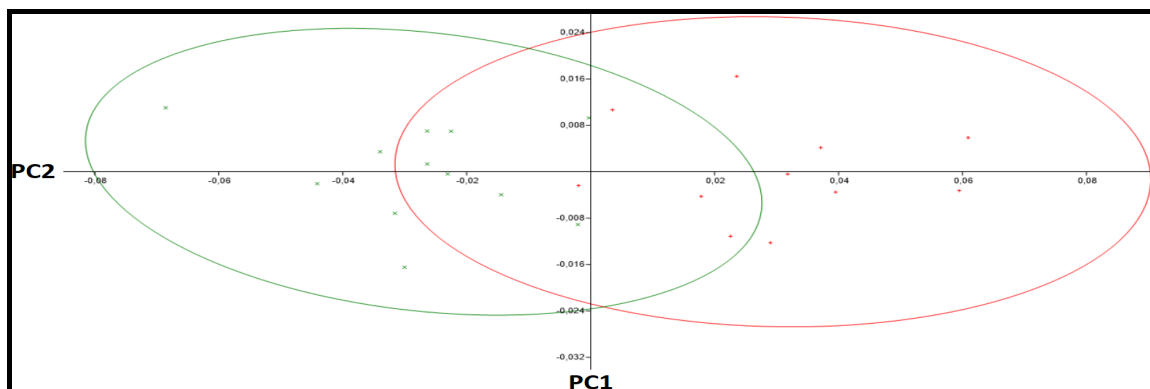


Figure 2. 95% confidence ellipse plot of the 13 marked analyses of hip bone. Red points represent female horses and green points represent male horses.

components, 5 male individuals were completely separated from the females. The remaining 11 individuals were not exactly separated by this basic component and were situated in the joint intersection area.

Without gender discrimination according to the first main component, the variation between the ventral endpoint of the coxal tuber, the midpoint of the iliac crest, the dorsal endpoint of the sacral tuber, and the medial endpoint of the ischial spine was found to be higher than other points.

In Figure 3, the difference between female and male is visually indicated using the morphology program. In females, it was observed that the points in the inner region are more lateral than males (the midpoint of the iliac crest, the dorsal endpoint of the sacral tuber, the medial endpoint of the narrowest section of the body of the ilium, the medial endpoint of the ischial spine and the caudo-dorsal endpoint of the pelvic symphysis). The change in the ventral endpoint of the coxal tuber point was visually higher than the other points. It was observed that this point was closer to the medial in females. The least change between females and males was observed in the dorsal endpoint of coxal tuber, the ventral endpoint of acetabulum, and the dorsal endpoint of acetabulum points.




Figure 3. The dots show the average of the female samples. The length of the lines extending from the points represents male samples. The length of the lines shows the amount of change between the genders and in which direction this change is directed (MorphoJ).

The statistical differences of the Landmarks used as a result of geometrical analysis between males and females are given in Table 2. Results similar to the visual data obtained with the MorphoJ program were obtained. The medial endpoint of the narrowest section of body of ilium and medial endpoint of ischial spine points were found to be statistically significant in terms of female and male distinction. It was seen that the remaining points in the ventrolateral section did not have a statistically significant difference in gender discrimination. However, the difference between the genders in the ventral endpoint of coxal tuber and midpoint of coxal tuber in the dorsolateral section was statistically significant.

Discussion

In the present study, the geometric morphometry of right hip bone belonging to 23 adult horses was examined and the differences between the male and female specimens used in the study were tried to be revealed. In a study conducted previously on the hip bone of 28 non-adult horses (mean 271 days), 16 determinative points were used and it was reported that 12 main components were obtained as a result of statistical analyses (Parés-Casanova, 2014). It was specified that the first main component accounted for 46.21% of the difference between the individuals. In the present study, 11 determinative points were used and 22 main components were obtained, and the first main component alone accounted for 22.22% of the variation among individuals. The variation difference between the two studies is considered to be caused by the use of the determinative points with different amounts and at different points. It is also known that the results of the geometric morphometric analysis of the photographs taken from different perspectives will be different.

In normal morphometric analyses, the distance between two points is measured and the differences between these distances are statistically analyzed. However, the geometric analysis makes a different comment. For example, in the present study, when the female and male hip bones were compared, the variations of the change between specific points on the coordinate plane were taken as a basis. And the deviation of the change to which direction on which points can be determined. In the present study, when the gender differences were considered, it was found that the midpoint of iliac crest on the medial margin, the dorsal endpoint of sacral tuber, the medial endpoint of the narrowest section of body of ilium, the medial endpoint of ischial spine, and the caudo-dorsal endpoint of

pelvic symphysis showed variation towards the outer points. However, in a normal morphometric study performed on the pelvis bone, it was stated that the difference between iliopubic eminence and sacroiliac joint was higher in females than males in female and male cats (Boonsri et al., 2019) By using these two methods together, it is predicted that more comprehensive studies would be possible where different comments can be made.

It is thought that such studies can be developed in the field of anatomy via the different interpretation of the geometric morphometric analysis. Additionally, it is predicted that the studies in which normal morphometric analyses could not be performed with this method would be possible. For example, in a study, the geometric analysis of facial expressions of the cats before and after the operation was prepared and the morphometric analysis of the difference between the facial expressions was carried out (Finka et al., 2019).

In the reference information, it is asserted that males have a more angular and narrower pelvis when viewed from the front (Dyce et al., 2016). It is also stated that the distance between the symmetrical parts of the pelvis is always greater in females (Dursun, 2006). It is said that the pelvic canal and caudal pelvic aperture are narrower in males than females and the floor of the pelvis section is flat in males and concave in females (Bahadır and Yıldız, 2010). When the differences between males and females were considered in the present study, it was seen that the determinative points shifted from the center to outside, which supports the literature information.

In the present study, geometric analysis of the photograph samples that were taken only from one direction was performed. It was determined that more determinative points can be used in the photographs taken from the front side and it was considered that there can be more variations among the individuals. Also, it was foreseen that the photographs taken from the front side would be more deterministic in gender discrimination. In the present study, the variations between the individuals using the geometric morphometric analysis on horse hip bone were tried to be revealed. The deterministic points were determined by the statistical data obtained between the genders. As there is no comprehensive literature source similar to this study in the field of veterinary anatomy, a comparison with other studies could not be made to a large extent. However, it is thought that such studies would increase further in the future. It is predicted that the parameters such as race, gender, and age can be evaluated in the field of veterinary anatomy via geometric morphometric studies. Also, it is thought that individual studies

may also be present via facial geometric analysis in animals.

References

- Allen MJ, 2013: Biochemical markers of bone metabolism in animals: uses and limitations. *Vet Clin Pathol*, 32 (3), 101-113.
- Álvarez A, Ercoli MD, Prevosti FJ, 2013: Locomotion in some small to medium-sized mammals: a geometric morphometric analysis of the penultimate lumbar vertebra, pelvis and hindlimbs. *Zool*, 116, 356-371.
- Ashdown RR, Done SH, 2001: Color Atlas of Veterinary Anatomy, Volume 2: The Horse, 2nd ed. Mosby Elsevier, Missouri, USA.
- Aytek AI, 2017: Geometrik Morfometri. *MASROP E-Dergi*, 11 (17), 1-7.
- Bahadır A, Yıldız H, 2010: Veteriner Anatomi: Hareket Sistemi ve İç Organlar. 2nd ed. Ezgi Kitapevi, Bursa, Turkey.
- Bernal V, 2007: Size and Shape Analysis of Human Molars: Comparing Traditional and Geometric Morphometric Techniques. *Homo*, 58 (4), 279-296.
- Bignon O, Baylac M, Vigne JD, Eisenmann V, 2005: Geometric morphometrics and the population diversity of Late Glacial horses in Western Europe (*Equus caballus arcelini*): phylogeographic and anthropological implications. *J Archaeol Sci*, 32, 375-391.
- Boonsri B, Pitakarnnop T, Buddhachat K, Changtor P, Nganvongpanit K, 2019: Can Feline (*Felis catus*) Flat and Long Bone Morphometry Predict Sex or Skull Shape. *Anat Sci Int*, 94, 245-256.
- Bytheway JA, Ross AH, 2010: A geometric morphometric approach to sex determination of the human adult os coxa. *J Forensic Sci*, 55 (4), 859-864.
- Cardini A, Thorington Jr RW, 2006: Postnatal ontogeny of marmot (Rodentia, Sciuridae) crania: allometric trajectories and species divergence. *J Mammal*, 87 (2), 201-215.
- Cervantes I, Baumung R, Molina A, Druml T, Gutierrez JP, Sölkner J, Valera M, 2009: Size and shape analysis of morphofunctional traits in the Spanish Arab horse. *Livest Sci*, 125, 43-49.
- Colville TP, Bassert JM, 2015: Clinical anatomy and physiology for veterinary technicians. 3rd ed. Mosby Elsevier, Missouri, USA.
- Danilo L, Remy J, Vianey-Liaud M, Merigeaud S, Lihoreau F, 2015: Intraspecific variation of endocranial structures in extant Equus: a prelude to endocranial studies in fossil equoids. *J Mammal Evol*, 22, 561-582.
- Delguste C, Doucet M, Gabriel A, Guyonnet J, Lepage O, Amory H, 2011: Assessment of a bone biopsy technique for measuring tiludronate in horses: a preliminary study. *Can J Vet Res*, 75 (2), 128-133.
- Drake AG, Klingenberg CP, 2010: Large-scale diversification of skull shape in domestic dogs: disparity and modularity. *Am Nat*, 175 (3), 289-301.
- Dursun N, 2006: Veteriner Anatomi 1. 10th ed., Medisan Yayınevi, Ankara, Turkey.

- Dyce KM, Sack WO, Wensing CJG, 2016: Textbook of Veterinary Anatomy. 3rd ed., Saunders Elsevier, Pennsylvania, USA.
- Finka LR, Luna SP, Brondani JT, Tzimiropoulos Y, McDonagh J, Fanworth MJ, Ruta M, Mills DS, 2019: Geometric Morphometrics for the Study of Facial Expressions in Non-Human Animals, Using the Domestic Cat as an Exemplar. *Sci Rep*, 9 (9883), 1-12.
- Frandsen RD, Wilke WL, Fails AD, 2009: Anatomy and physiology of farm animals. 7th ed., Wiley-Blackwell, Iowa, USA.
- Franklin D, Oxnard CE, O'Higgins P, Dadour I, 2007: Sexual dimorphism in the subadult mandible: quantification using geometric morphometrics. *J Forensic Sci*, 52 (1), 6-10.
- Fureix C, Hausberger M, Seneque E, Morisset S, Baylac S, Cornette R, Biquand V, Deleporte P, 2011: Geometric morphometrics as a tool for improving the comparative study of behavioural postures. *Naturwissenschaften*, 98, 583-592.
- Geiger M, Evin A, Sánchez-Villagra MR, Gascho D, Mainini C, Zollikofer CP, 2017: Neomorphosis and heterochrony of skull shape in dog domestication. *Sci. Rep.*, 7 (1), 1-9.
- Gonzalez NC, RascónPérez J, Chamero B, Cambra-Moo O, Martin AG, 2017: Geometric morphometrics reveals restrictions on the shape of the female os coxae. *J. Anat.*, 230 (1), 66-74.
- Gündemir O, Özkan E, Dayan MO, Aydoğdu S, 2020: Sexual analysis in turkey (Meleagris gallopavo) neurocranium using geometric morphometric methods. *Turk J Vet Anim Sci*, 44(3), 681-687.
- Gürbüz İ, Aytekin AI, Demiraslan Y, Onar V, Özgel Ö, 2020. Geometric Morphometric Analysis of Cranium of Wolf (Canis lupus) and German Shepherd Dog (Canis lupus familiaris). *Kafkas Üniv Vet Fak Derg*, 26(4), 525-532.
- Hammer Ø, Harper DAT, Ryan PD, 2011: PAST: Paleontological Statistics Software Package for Education and Data Analysis. *Palaeontol Electron*, 4 (1), 1-9.
- Kaya A, Gharakhloo MM, Coşkun Y, 2018: Geographic variation in the skull morphology of *Ellobius lutescens* Thomas, 1897 (Mammalia: Rodentia) by geometric morphometrics. *Vertebr. Zool*, 68 (2), 157-164.
- Klingenberg CP, 2011: MorphoJ: An Integrated Software Package for Geometric Morphometrics. *Mol. Ecol. Resour*, 11 (2), 353-357.
- König HE, Liebich HG, 2004: Veterinary anatomy of domestic animals: textbook and color atlas. 6th ed., Schattauer GmbH, Stuttgart, Germany.
- Maass P, Friedling LJ, 2019: Morphometric Analysis of the Neurocranium in an Adult South African Cadaveric Sample. *J. Forensic Sci*, 64 (2), 367-374.
- Misheff MM, Stover SM, Pool RR, 1992: Corticocancellous Bone Biopsy from The 12th Rib of Standing Horses. *Vet Surg*, 21 (2), 133-138.
- Noble J, Cardini A, Flavel A, Franklin D, 2019: Geometric morphometrics on juvenile crania: Exploring age and sex variation in an Australian population. *Forensic Sci. Int.*, 294, 57-68.
- Ozdemir ST, Ercan I, Ozkaya G, Cankurt NS, Erdal YS, 2010: Geometric Morphometric Study and Cluster Analysis of Late Byzantine and Modern Human Crania. *Coll. Antropol*, 34 (2), 493-499.
- Parés-Casanova PM, 2014: Geometric Morphometrics for the Study of Hemicoxae Sexual Dimorphism in a Local Domestic Equine Breed. *J Morphol Sci*, 31 (4), 214-218.
- Rebsamen E, Geyer H, Fürst A, Eser MW, Koch C, Kummer M, 2014: Haematuria in two geldings caused by osteochondroma of the os pubis: Case reports and anatomic study of the os pubis in 41 cadaveric pelvises. *Equine Vet Educ*, 24 (1), 30-37.
- Rohlf FJ, 2015: tpsDig2 Version 2.18., Department of Ecology and Evolution, State University of New York at Stony Brook. New York, USA.
- Savage CJ, Jeffcott LB, Melsen F, Østblom LC, 1991a: Bone biopsy in the horse: 1. Method using the wing of the ilium. *J Vet Med*, 38 (1-10), 776-783.
- Savage CJ, Tidd LC, Østblom LC, Melsen F, Jeffcott LB, 1991b: Bone biopsy in the horse: 3. Normal histomorphometric data according to age and sex. *J Vet Med*, 38 (1-10), 793-797.
- Schutz H, Polly PD, Krieger JD, Guralnick RP, 2009: Differential sexual dimorphism: size and shape in the cranium and pelvis of grey foxes (Urocyon). *Biol J Linn Soc Lond*, 96, 339-353.
- Seetah K, Cucchi T, Dobney K, Barker G. 2014: A geometric morphometric re-evaluation of the use of dental form to explore differences in horse (*Equus caballus*) populations and its potential zooarchaeological application. *J Archaeol Sci*, 41, 904-910.
- Slice DE, 2007: Geometric Morphometrics. *Annu Rev Anthropol*, 36, 261-281.
- Steiger R, Geyer H, Provencher A, Perron-Lepage MF, Von Salis B, Lepage OM, 1999: Equine bone core biopsy: evaluation of collection sites using a new electric drilling machine. *Equine Practice*, 21, 14-21.
- Yalçın H, Kaya MA, Arslan A, 2010: Comparative geometrical morphometrics on the mandibles of anatolian wild sheep (*Ovis gmelini anatolica*) and akkaraman sheep (*Ovis aries*). *Kafkas Üniv Vet Fak Derg*, 16 (1), 55-61.
- Yalçın H, Kaya MA, 2009: Comparative geometrical morphometry on the skull bones of anatolian wild sheep and akkaraman sheep. *Atatürk Üniversitesi Vet Bil Derg*, 4 (2), 105-116.
- Yalçın H, Kayış SA, Arslan A, 2007: A Comparative Macro-Anatomic, Mechanical and Geometric Morphometrics Study on Tree and Ground Squirrel and Rat. *Vet Bil Derg*, 23 (1), 83-95.

*Correspondence: İsmail DEMİRCİOĞLU

Harran University Faculty of Veterinary, Department of Anatomy, Şanlıurfa, Turkey

e-mail: idemircioglu@harran.edu.tr