

## Topographic and Morphometric Study on Mental Foramen in Hemshin Sheep for Local Anesthesia

Semine DALGA<sup>1a\*</sup> Kadir ASLAN<sup>1b</sup>

<sup>1</sup> Kafkas University, Faculty of Veterinary Medicine, Department of Anatomy, Kars-TÜRKİYE

<sup>a</sup><https://orcid.org/0000-0001-7227-2513>; <sup>b</sup><https://orcid.org/0000-0002-7617-0175>

e-mail: [sdalga91@gmail.com](mailto:sdalga91@gmail.com)

### ABSTRACT

The topographic and morphometric anatomy of various foramina provides an easy approach in performing nerve blocks by their proper tracking for regional anesthesia in surgical interventions. In this study, the mandible of Hemshin sheep of both sexes were examined. The topographic and morphometric structure of the mental foramen was examined. In this study, a total of 15 adult Hemshin sheep mandible of both sexes of different age and body weight were used. Materials were obtained from the municipal slaughterhouse of Ardanuç district of Artvin province. Mandible was separated from the head and skin, muscle and ligaments was cleaned and allowed to dry by standard technique. In the light of the literature, various measurements were made from the mandible using an electronic caliper. In Hemshin sheep the shape of mental foramen was round and oval. There was no difference between the bilateral sides of the mandible. The mental foramen was quite deep. The distance of the mental foramen from the ventral edge of the mandible was  $0.69 \pm 0.13$  cm in the sheep. The distance of 1. premolar teeth and mental foramen was  $1.98 \pm 0.21$  cm. The distance between the mental foramen and lateral incisive teeth was  $2.40 \pm 0.37$  cm. the distance between caudal edge of the mandible and mental foramen was measured as  $13.49 \pm 1.35$  cm.

### ARTICLE INFO

#### Research article

Received: 12.10.2020

Accepted: 19.11.2020

#### Keywords:

Hemshin sheep, mental foramen, morphometry.

### INTRODUCTION

Hemshin sheep are widely grown in Eastern Black Sea provinces. Turkey, which has been the homeland of Hemshin sheep adapted to the climate of the region. Hemshin sheep are commonly raised for its meat and milk in the Eastern Black Sea provinces of Artvin and Rize (Akçapınar 2000). In this study the mandible of Hemshin sheep was used. The aim of study was to determine the shape of the mental foramen topographically using morphometric methods. Morphometry, as a method, is a research method that allows the numerical or graphical statistical analysis of the measurements of width, length or angle between two points (Rohlf and Marcus 1993). The development of the mandible is associated with various factors such as growth hormones (Hwang and Cha 2004), growth factors (Delatte et al. 2004), race (Oshikawa et al. 2004) and mechanical stress (Bresin et al. 1999). Experimental studies have shown that the suppression of sex hormones of the animals in growth period inhibits the growth of the mandible in particular (Fujita 2004).

The regional anatomy is one of the major foundations of clinical and surgical practice as it enables the clinician/surgeon to visualize the details of the structures relevant to the case at hand (Dyce et al., 1996). The knowledge of the regional anatomy of the head is crucial as it has to coordinate the body, deglutition, olfaction and defense (Dyce et al., 1996). Numerous investigations have been done on the regional anatomy of the head and mandibular region of the domestic and wild animals including ox, horse, sheep, goat, dog, pig and camel (Dyce et al., 1996; Hall et al., 2000; Onar et al., 2001; Olopade and Onwuka, 2005; İnce and Pazvant, 2010; Yalçın et al., 2010; Akbulut et al., 2014; Gürbüz et al., 2016; Gündemir et al., 2020; Yılmaz and Demircioğlu, 2020; Özkan et al., 2020; Chouldhary et al., 2020). It has been reported previously that the mental nerve pass from the mental foramen, respectively (Getty, 1975; Ghosh, 2012). In an emergency situation that requires surgical intervention, it is very easy to locate this region as a topographical landmark for quick and easy anesthesia to block the mandibular and mental nerves.

## MATERIALS AND METHODS

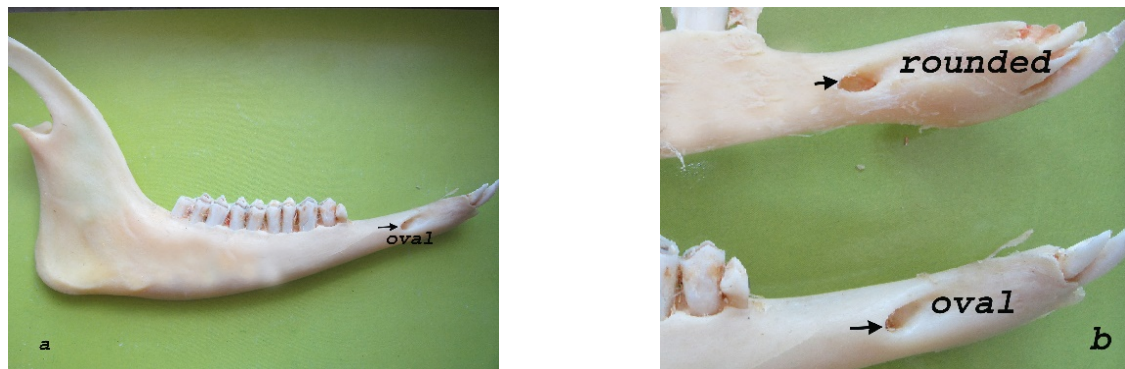This study was conducted with 15 Hemshin sheep mandible of both sexes. Mandible were obtained during animal slaughter in Artvin Ardanuç district. First, mental nerve is dissected than the muscles and ligaments were removed from the mandible. Mandibles were dried by standard bone maceration technique. All the topographic and morphometric studies of the mental foramen and their records were made in the Anatomy Department of the Faculty of Veterinary Medicine of Kafkas University. Then, in accordance with the literature, measurements were made with the electronic caliper at the points indicated below.

1. The mental foramen were identified in various shapes, size and directions at the lateral aspect of the rostral part of each mandible.
2. The distance from the base of the mandible (ventral border of the mandible) to the mental foramen was measured and recorded.
3. The distance from the lateral alveolar border of the first premolar tooth to the mental foramen was measured and recorded.
4. The distance from the lateral extent of the alveolar root of the lower incisor to the mental foramen was measured and recorded.
5. The distance from the caudal border of the mandibular to the mental foramen was measured and recorded.

The mean values of all measurements with standard deviations were evaluated in SPSS Statistics 20.0.

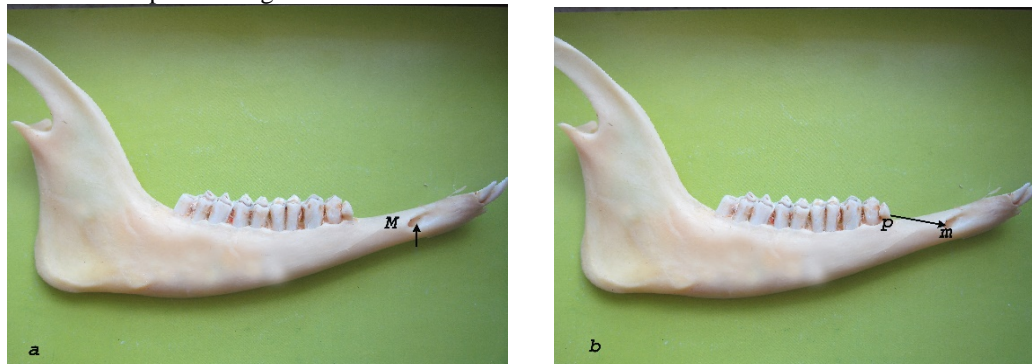
## RESULTS

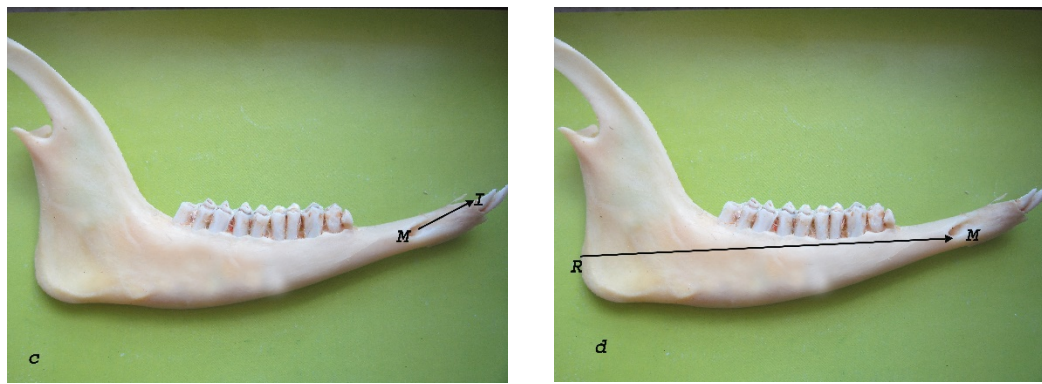
Mental foramen is usually located on the lateral face of the mandible. The shape of mental foramen of Hemshin sheep was only oval and round. There was no difference in shape between the bilateral faces of the same mandible. The mental foramen was quite deep. The mandibles that were examined are in the following picture (Figure 1/a, b).



**Figure 1:** a. Oval shaped mental foramen, b. Round shaped mental foramen.

The topographic and morphometric location of the mental foramen is shown in Figure 2. The mean and standard deviation values of these points are given in Table 1 below.





**Figure 2:** a. Distance between base of body of mandible to mental foramen (BM), b. distance between 1st premolar tooth to mental foramen (PM), c. distance between lateral incisor tooth to mental foramen (IM) and d. distance between caudal border of ramus of mandible to mental foramen (RM).

**Table 1.** Morphometric measurement of mental foramen on mandible of Hemshin sheep.

Parameters	Minimum (cm)	Maximum (cm)	Mean + Std. Deviation (cm)
Distance from base of body of mandible to mental foramen	0.5	0.9	0.69±0.13
Distance from 1 <sup>st</sup> premolar tooth to mental foramen	1.64	2.24	1.98±0.21
Distance from lateral incisor tooth to mental foramen	1.91	2.87	2.40±0.37
Distance from caudal border of ramus of mandible to mental foramen	11.50	15.12	13.49±1.35

**Table 2.** The result were found similar parameters in some animals

Parameters	Distance from base of body of mandible to mental foramen	Distance from 1 <sup>st</sup> premolar tooth to mental foramen	Distance from lateral incisor tooth to mental foramen	Distance from caudal border of ramus of mandible to mental foramen
Black bengal goat (Uddin et al)	-	-	2.11±0.17cm	11,69±0.40cm
Mehreban sheep	-	-	-	13,74±0,18cm
Barbados black belly sheep	0.70±0.18cm	2.25±0.38cm	2.25±0.31cm	15,23±1.46cm
Gwembe Valley dwarf goat	2.35±0.26cm		1.58±0.19	9,26±0.49
Black bengal goat (Poddar et al)	0.77±0.04cm	1.46±0.09cm	2.01±0.05cm	11.81±0.89
West African dwarf goat	-	-	1.56±0.22cm	-
Hemshin sheep	0.69±0.13cm	1.98±0.21cm	2.40±0.37cm	13.49±1.35cm

## DISCUSSION AND CONCLUSION

Figure 1 shows that the mental foramen consist of different shapes and sizes. This is consistent with the information in the literature Monfared et al., (2013), Goodarzi N and Hosseini (2013), Kataba et al., (2014), Poddar et al., (2018).

The distance of the mental foramen to the ventral edge of the mandible was  $0.69 \pm 0.13$  cm in the sheep. This measure is  $0.77 \pm 0.04$  in Black Bengal goat (Poddar, 2018), Mohamed et al., (2016) reported that the rate of  $0.70 \pm 0.18$  cm. Kataba et al., (2014) reported this length as  $2.35 \pm 0.26$  cm.

The distance from 1st premolar tooth to mental foramen was  $1,98 \pm 0,21$ . This measurement was reported to be  $1.46 \pm 0.09$  cm and  $2.25 \pm 0.38$  cm in the literature, respectively. (Poddar et al., 2018; Uddin et al., 2009). As a result of this

finding, it supports that mental foramen can be palpated ventro-laterally at  $1.98 \pm 0.21$  cm distance from the first premolar tooth in Hemshin sheep.

The distance from mental foramen to lateral incisive tooth was found to be  $2.40 \pm 0.37$ . This measurement have been reported  $2.01 \pm 0.05$  cm in Black Bengal Goat (Poddar et al., 2018),  $2.11 \pm 0.17$ , Uddin et al., (2009),  $2.25 \pm 0.31$  cm Mohamed et al., (2016),  $1.56 \pm 0.22$  cm. Olopade and Onwuka (2005),  $1.58 \pm 0.19$  cm Kataba et al., (2014).

The distance from caudal edge of the ramus mandible to mental foramen was measured as  $13.49 \pm 1.35$  cm in this study. This measurement have been reported  $11.8 \pm 0.89$  in Black Bengal Goat (Poddar et al., 2018),  $11.69 \pm 0.4$  cm. Uddin et al., (2009),  $9.26 \pm 0.49$  cm. Kataba et al., (2014). This parameter was found to be more than the values in the study. However, Karimi et al., (2012) was reported  $13.74 \pm 0.18$  cm in Mehreban sheep and  $15.23 \pm 1.46$  cm. Mohamed et al., (2016). All findings and literature data are given in the table 2.

As a result, it can be concluded that the study on mental foramen in Hemshin sheep would be beneficial for the clinicians anesthetic drugs for the nerves of mandibular region and can aid the veterinary practitioners during the injuries Hemshin sheep.

## REFERENCES

- Akçapınar H (2000). Koyun Yetiştiriciliği, İsmat Matbaacılık, 2. Baskı, 109-115. Ankara.
- Akbulut Y, Demiraslan Y, Gürbüz İ, Aslan K (2014). Yeni Zelanda Tavşanı (*Oryctolagus cuniculus* L.)'nda cinsiyet faktörünün mandibula morfometrisine etkisi. 28, 15-18 2014, Fırat Üniv. Sađl. Bil. Vet. Derg.
- Bresin A, Kiliaridis S, Strid KG (1999). Effect of masticatory function on the internal bone structure in the mandible of the growing rat. 107, 35 – 44. Eur. J. Oral Sci.,
- Choudhary OP, Priyanka KPC, Keneisenuo, Konwar B, Doley PJ, Kalita A, Gündemir O (2020). Applied Anatomy of the Maxillofacial and Mandibular Regions of Indian Mithun (*Bos frontalis*) and its Clinical Significance in Regional Anesthesia. Indian Journal of Animal Research.
- Delatte M, Von den Hoff JW, Maltha JC, Kuijpers-Jagtman AM (2004). Growth stimulation of mandibular condyles and femoral heads of newborn rats by IGF-I. 49, 165–175, Arch.Oral Biol.
- Dyce KM, Sack WO, Wensing CJG (1996). Textbook of veterinary anatomy. 2nd edn. Elsevier, Philadelphia, USA.
- Fujita T (2004). Effects of sex hormone disturbances on craniofacial growth in newborn mice. 83, 250–254, J. Dent. Res.
- Getty R (1975). Sisson and Grossman's: The anatomy of the domestic animals, 2nd (edn.), Vol. I, W.B. Saunders Co. Philadelphia, USA.
- Ghosh RK (2012). Primary veterinary anatomy, 5th edn., Current books international, Kolkata, West Bengal, India.
- Goodarzi N, Hoseini TJ (2013). Morphometric Characteristics of the Maxillofacial and Mandibular Regions of Markhoz Goat Breed and its Clinical Value for Regional Anaesthesia in Western Iran. Global Veterinaria 11(1): 107-111.
- Gündemir O, Duro S, Jashari T, Kahveciođlu O, Demirciođlu İ, Mehmeti H (2020). A study on morphology and morphometric parameters on skull of the Bardhoka autochthonous sheep breed in Kosovo. Anat Histol Embryol. 00:1–7. <https://doi.org/10.1111/ah.12538>.
- Gürbüz İ, Demiraslan Y, Gülbaz F, Aslan K (2016). Malakan Atı mandibula' sının cinsiyete göre morfometrik özellikleri. Eurasian J. Vet. Sci, DOI: 10.15312/EurasianJVetSci.2016318390, 32(3): 00-00.
- Hall LW, Clarke KW, Trim CM (2000). Wright's veterinary anesthesia. 10th edn. ELBS and Bailliere Tindall, London, UK.
- Hwang CJ, Cha JY (2004). Orthodontic treatment with growth hormone therapy in a girl of short stature, 126, 118–126, Am. J. Orthod. Dentofac.
- İnce GN, Pazvant G (2010). Morphometry of the Mandible in rats (wistar Albino). 36 (1), 51-56 J. Fac. Vet. Med. İstanbul Univ.
- Karimi I, Hadipour MM, Nikbakht P, Motamedi SH (2012). The Lower Jawbone of Mehraban Sheep: A descriptive morphometric approach. World's Veterinary Journal 2(4): 57-60.
- Kataba A, Mwaanga ES, Simukoko H, Pares CPM (2014). Clinical anatomy of the head Region of Gwembe Valley dwarf goat in Zambia. International Journal of Veterinary Science 3(3): 142-146.
- Mohamed R, Drisco M, Mootoo N (2016). Clinical Anatomy of the skull of the Barbados Black Belly Sheep in Trinidad. International Journal of Current Research in Medical Science 2(8): 8-19.
- Monfared AL, Naji H, Sheibani MT (2013). Applied anatomy of the head region of the Iranian Native goats (*Capra hircus*). Global Veterinaria 10(1): 60-64.
- Olopade JO, Onwuka Sk (2005). An osteometric study of the skull of the West African Dwarf goat from South Eastern Nigeria. II- Mandibular and Maxillofacial features (Short Communication). Nigerian Veterinary Journal 27(2): 66-70.
- Onar V, Özcan S, Pazvant G (2001). Skull typology of adult male Kangal dogs. Anat. Histol. Embryol. 30(1): 41-48.
- Oshikawa M, Sugano N, Ishigaki R, Ito K (2004). Gene expression in the developing rat mandible: a gene array study. 49, 325-329, Arch. Oral Biol.

- Özkan E, Jashari T, Gündemir O, Gezer İN (2020). Morphometric analysis of the mandible of Bardhoka autochthonous sheep in Kosovo. *Anat Histol Embryol.* 00:1–5. <https://doi.org/10.1111/ahe.12568>.
- Poddar S, Faruq AA, Dey T, Kibria ASMG, Uddin MM (2018). Topographic and Morphometric Anatomy of Mental Foramen of Black Bengal goat ( *Capra hircus*) in Bangladesh with its Clinical Implication for Regional Anesthesia. *Int J Zoo Animal Biol*, 1(1):000102.
- Rohlf FJ, Marcus LF (1993). A revolution in morphometrics. *Trendsecol. Evol.*, 8, 129-132,.
- Uddin MM, Ahmed SSU, Islam KN, Islam MM (2009). Clinical anatomy of the head region of the Black Bengal goat in Bangladesh. *International Journal of Morphology* 27(4): 1269-1273.
- Yalçın H, Kaya MA, Arslan A (2010). Comparative Geometrical Morphometries on the Mandibles of Anatolian Wild Sheep (*Ovis gmelini anatolica*) and Akkaraman Sheep (*Ovis aries*). 16 (1) 55-61, Kafkas Uni. Vet. Fak. Derg.
- Yılmaz B, Demircioğlu İ (2020). Morphometric Analysis of the Skull in the Awassi Sheep (*Ovis aries*), *F.Ü.Sağ.Bil.Vet.Derg.* 34 (1): 01 – 06.