

RESEARCH ARTICLE

Radiologic analysis of correlations between sinonasal anatomical variations in patients with nasal septal deviation

Elif Karalı¹, Akif Güneş¹, Emine Dağistan², Zeliha Coşgun², Ahmet Ural¹, Oya Kalaycıoğlu³

¹Department of Otorhinolaryngology, Bolu Abant İzzet Baysal University Medical Faculty, Bolu, Turkey

²Department of Radiology, Bolu Abant İzzet Baysal University Medical Faculty, Bolu, Turkey

³Department of Bioistatistics and Medical Information, Bolu Abant İzzet Baysal University Medical Faculty, Bolu, Turkey

Received: 24 October 2020, Accepted: 04 December 2020, Published online: 31 December 2020

© Ordu University Institute of Health Sciences, Turkey, 2020

Abstract

Objective: This study aims to analyze the sinonasal anatomical variations accompanying the nasal septal deviation, the correlations between these variations, and their relationship with the septal deviation angle.

Methods: In this retrospective study, preoperative paranasal computed tomography (CT) scans of 206 patients who underwent septoplasty between January 2015 and December 2019 were examined. In CT scans, different nasal septal deviation types, Keros classification, optic nerve type, ethmoid air cell variants, nasal concha variants, paranasal sinus pneumatization variants, and the correlation between accessory pneumatization variants and their relationship with the septal deviation angle were analyzed.

Results: In patients with nasal septal deviation, supraorbital ethmoid cell, anterior clinoid process pneumatization and onodi cell were more frequent compared to the literature. Any significant correlation between the nasal septal deviation angle and the presence of sinonasal variants was not detected ($p > 0.05$). Correlations were significant between the presence of Frontal sinus hypoplasia and Haller cell ($\phi = -0.142$, $p = 0.042$), Supraorbital Ethmoid cell ($\phi = -0.173$, $p = 0.013$) and Paradoxal middle concha ($\phi = 0.152$, $p = 0.029$).

Conclusion: Careful examination of paranasal CTs before craniomaxillofacial surgeries is important to determine sinonasal anatomic variants, to determine the appropriate treatment plan and to prevent possible complications preoperatively.

Key words: Nasal septal deviation, Paranasal computerized tomography, Anatomic variation, Supraorbital ethmoid cell, Anterior clinoid process

Suggested Citation: Karalı E, Gunes A, Dagistan E, Cosgun Z, Ural A, Kalaycioglu O. Radiologic analysis of correlations between sinonasal anatomical variations in patients with nasal septal deviation. Middle Black Sea Journal of Health Science, 2020; 6(3):340-351.

Address for correspondence/reprints:

Elif Karalı

Telephone number: +90 (374) 253 46 563355

ORCID-ID 0000-0002-8164-4056

E-mail: elifkarali8181@gmail.com

DOI: 10.19127/mbsjohs.815984

Introduction

Nasal septal deviation (NSD) is one of the major causes of nasal obstruction. Paranasal sinus (PNS) computed tomography (CT) is a widespread method to assess the paranasal anatomy (Wuister et al., 2014). Nasal anatomy and accompanying sinonasal pathologies can be evaluated with preoperative PNS CT in patients undergoing septoplasty (Akoglu et al., 2007). There are many sinonasal variants, and the identification of sinonasal anatomic variants in paranasal CT scans before craniomaxillofacial surgeries are important to prevent complications. The most common sinonasal anatomical variations are Agger nasi cells, infraorbital ethmoidal cells (Haller), sphenoidal cells (Onodi), NSD and concha bullosa (Kantarci et al., 2004; Alkire and Bhattacharyya, 2010). Sinonasal anatomical variants as upper concha bullosa, lower concha bullosa, uncinata bulla, supraorbital ethmoid cell, anterior clinoid process pneumatization (ACPP) are less rarely seen (Fadda et al., 2012).

According to Mladina's classification, NSD was categorized into seven types. Type 1, unilateral vertical crest up to nasal valve; Type 2, unilateral vertical crest reaching to nasal valve; Type 3, unilateral vertical crest at the level of middle nasal concha; Type 4, the combination of Type 1 defined as S type septal deviation or Type 2 combined with Type 3; Type 5, unilateral horizontal crest in touch with the lateral nasal wall; Type 6, bilateral horizontal crest, and Type 7, NSDs with combinations of all these types.

Delano classification was used to determine the relationship of the optic nerve to the sphenoid sinus (SS) (DeLano et al., 1996). According to this classification, there is no recess into the Type 1 SS wall. Type 2 has a recess in the SS wall that does not come into contact with the posterior ethmoid cell. There is a protrusion to the SS wall in Type 3. Type 4 extends into the SS and posterior ethmoid cells.

The olfactory fossa depth was calculated by Keros classification. Accordingly, the length of the vertical line drawn from the horizontal line connecting the infraorbital nerves perpendicularly to the medial point of the ethmoid roof was determined as the height of the medial ethmoid roof. The length of the vertical line drawn from the horizontal line connecting the infraorbital nerves perpendicularly to the lamina cribrosa was determined as the height of the cribriform plate. The difference between the two heights was accepted as the height of the lamina lateralis, and the depths of olfactory fossa ranging between 1-3 mm, 4-7 mm, and 8-16 mm were graded as Keros Types 1, 2, and 3.

The frequency of coexistence of NSD and concha bullosa has been explored many times before (Koo et al., 2017; El-Taher et al., 2019). There are limited number of studies investigating the relationship between NSD and other sinonasal anatomical variations (Koo et al., 2017; Yazici, 2019).

This study aims to analyze the sinonasal anatomical variations accompanying the nasal septal deviation, the correlations between these variations, and their relationship with the septal deviation angle.

Methods

In our study, age, gender, and preoperative PNS CTs of 206 patients who underwent septoplasty between January 2015 and December 2019 were retrospectively analyzed. Patients younger than 18 years old, patients who had undergone septum or paranasal sinus surgery, patients with acute or chronic sinusitis, and patients with sinonasal polyposis or tumor were excluded from the study.

CT scans were obtained in the supine position using routine PNS CT imaging without contrast or sedation. CT examinations were performed by using a 64-channel multidetector CT unit (Revolution CT GE Healthcare, Milwaukee, WI, USA). The imaging parameters were KvP: 100, mAs: 90, a slice thickness 0.625 mm, a reconstruction increment 1.5 mm, a scan field of view of 20 cm, and a matrix of 512×512 with the high-resolution bone algorithm.

CT scans were examined by a single experienced radiologist using PACS (Picture Archiving and Communicating System). Different NSD types, Keros classification, optic nerve type, ethmoid cell variants as Agger nasi cell, Onodi cell, Haller cell, supraorbital ethmoid cell, also nasal concha variants as superior concha bullosa middle concha bullosa, paradoxal middle concha, paranasal sinus pneumatization variants as frontal sinus hypoplasia and maxillary sinus hypoplasia; accessory pneumatization variants, as uncinata bulla in paranasal CTs; prevalence of ACPP and their in-between correlations with NSD angle were evaluated.

In CT scans, two different classifications defined by Elahi et al. and Mladina were used to determine the type of septum deviation of patients (Elahi et al., 1997; Mladina et al., 2008). NSD was classified in 3 types as mild ($< 9^\circ$), medium ($9^\circ - 15^\circ$), advanced ($> 15^\circ$) according to the septal deviation angle (SDA rating system of Elahi et al. (Elahi et al., 1997)

Statistical Analyses

The variables were summarized with median (Interquartile range) and frequency (percentage). Comparative statistical tests between groups were performed using the Kruskal–Wallis, Mann Whitney U, Pearson’s chi-square or Fisher’s exact tests, where appropriate. The ϕ (phi) correlation coefficient was used to estimate the degree of association between the anatomical variations. Statistical significance was set at $p < 0.05$ and the Statistical Package for Social Sciences 25.0 for Windows (SPSS Inc., Chicago, Illinois, USA) was used for conducting the analysis.

Results

A total of 206 patients [62.1 % males and 37.9 % females] between the ages of 18-67, were included in the study. The effects of demographic data of patients, NSD type, Keros classification, prevalence rates of optic nerve type; as ethmoid air cell variants Agger nasi cell, Onoid cell (Figure 1), Haller cell, supraorbital ethmoid cell (figure 2); as nasal concha variants superior concha bullosa, middle concha bullosa (Figure 3), paradoxal middle concha; as paranasal sinus pneumatization variants frontal and maxillary sinus hypoplasia; and accessory pneumatization variants, uncinata bulla (Figure 4), ACPP (Figure 5), and gender on the distribution of these variants are shown in Table 1.

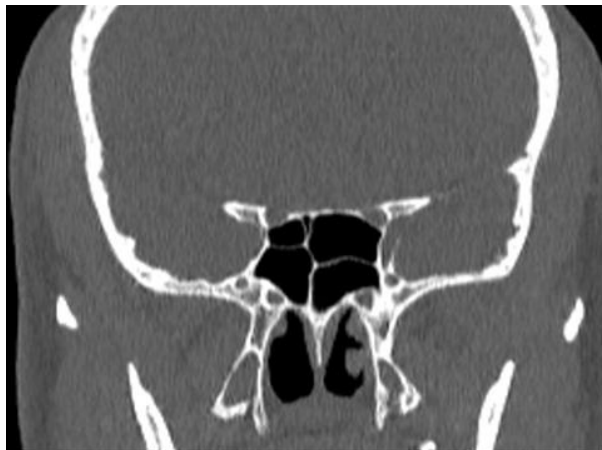


Figure 1. Coronal paranasal CT image of 38-year-old man with bilateral onodi cell (arrows).

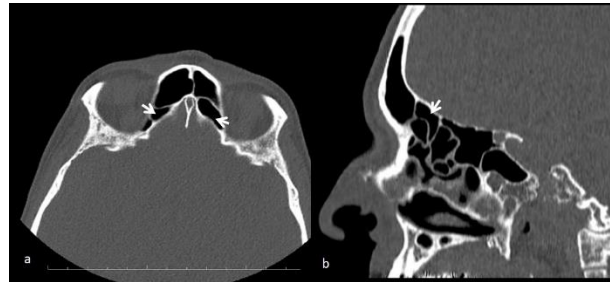


Figure 2. 55-year-old man with bilateral supraorbital ethmoid cell. a, bilateral supraorbital ethmoid cell on paranasal BT (arrows): axial view b, left supraorbital ethmoid cell on paranasal CT (arrow): sagittal view.

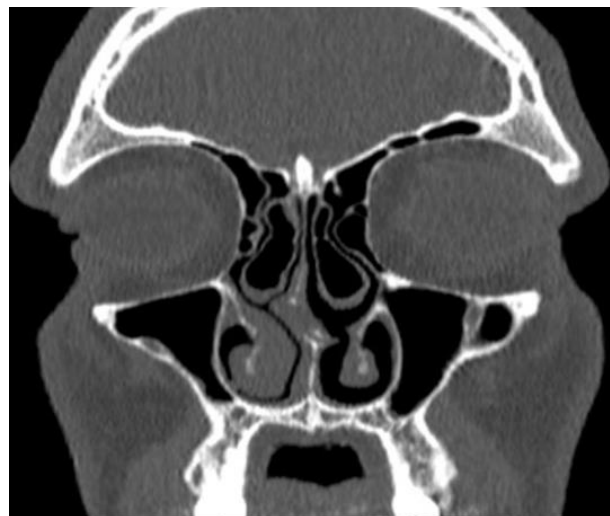

Figure 3. Coronal paranasal CT image of 20-year-old man with mladina type 4 nasal septal deviation and bilateral middle concha bullosa (arrows).

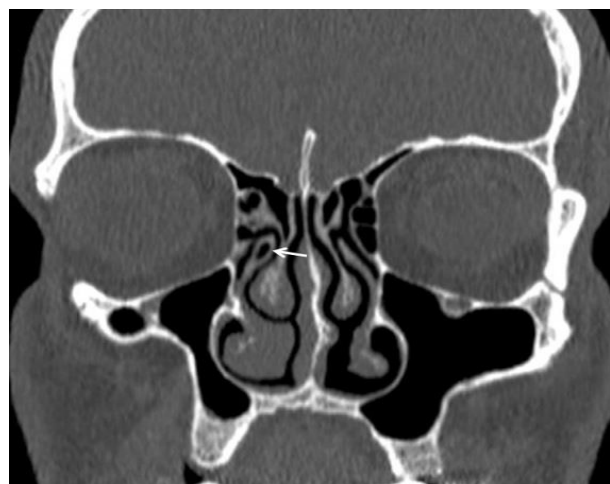


Figure 4. 35-year-old man with right uncinata bulla. The arrow marks the uncinata bulla on paranasal CT: coronal view.

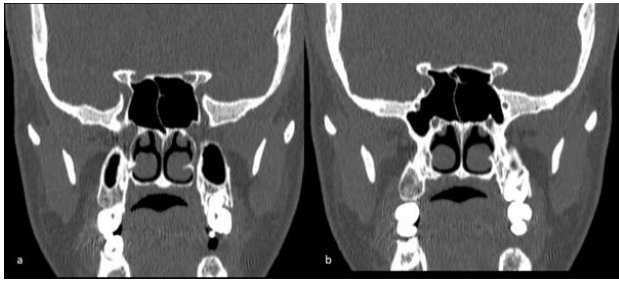

Figure 5. Coronal parasasal CT image of a 30-year-old woman with ACPP. a, Coronal CT section showing DELANO TYPE 2 Optic nerve canal (thick arrow). b, Coronal CT section showing ACPP (thin arrow).

Agger nasi was the most frequently parasasal anatomical variation (56.8%), followed by middle concha bullosa (53.9%) and ACPP (35.0%) (Table 1)

The most frequently Keros type was Type 2 (67%) and the most frequently seen optic nerve type was Type 1 (48.1%), according to Delano classification. When we look at the effect of gender on Keros and Delano classifications, we saw that there was no significant difference between them ($p = 0.349$, $p = 0.077$) (Table 1). The prevalence of NSD types as per Mladina is significant between males and females ($p = 0.036$). Among males, Type 4 is the most common nasal septum deformity (19.5%) (Figure 3), whereas Type 7 has the highest prevalence among female patients (23.1%). The presence of supraorbital ethmoid is significantly higher in males compared to female patients [21.1% vs. 6.4%] ($p = 0.005$) (Table 1).

There is no significant difference was found between NSD types as per angle classification in terms of the sinonasal variation ($p > 0.05$) (Table 2).

The analysis of correlations between the sinonasal anatomical variations accompanying the septum deviation is shown in Table 3. A significant positive correlation between the presence of Haller cell and onodi cells was observed ($\phi = 0.154$, $p = 0.027$). Correlations were also significant between

the presence of Frontal sinus hypoplasia and Haller cell ($\phi = -0.142$, $p = 0.042$), Supraorbital Ethmoid cell ($\phi = -0.173$, $p = 0.013$) and Paradoxal middle concha ($\phi = 0.152$, $p = 0.029$). Supraorbital Ethmoid cell was also positively correlated with Uncinate bulla ($\phi = 0.152$, $p = 0.041$) (Table 3).

Radiologic Analysis of Sinonasal Anatomical Variations

Table 1. Demographic and clinical characteristics of the sample (n=206).

Patient Characteristics	Total	Gender		p
	median (IQR) or n (%)	Males (n=128)	Females (n=78)	
<i>Demographic variables</i>				
Age	27.0 (17.8)	29.0 (18.0)	27.0 (17.8)	0.292 ^a
<i>NSD type as per Mladina's classification</i>				
Type 1	20 (9.7%)	12 (9.4%)	8 (10.3%)	0.036^b
Type 2	22 (10.7%)	14 (10.9%)	8 (10.3%)	
Type 3	30 (14.6%)	13 (10.2%)	17 (21.8%)	
Type 4	30 (14.6%)	25 (19.5%)	5 (6.4%)	
Type 5	32 (15.5%)	22 (17.2%)	10 (12.8%)	
Type 6	36 (17.5%)	24 (18.8%)	12 (15.4%)	
Type 7	36 (17.5%)	18 (14.1%)	18 (23.1%)	
<i>NSD type as per angle classification</i>				
Type 1	35 (17.0%)	18 (14.1%)	17 (21.8%)	0.117 ^b
Type 2	100 (48.5%)	69 (53.9%)	31 (39.7%)	
Type 3	71 (34.5%)	41 (32.0%)	30 (38.5%)	
<i>Variation of ethmoid air cell</i>				
Agger nasi cell	117 (56.8%)	67 (52.3%)	50 (64.1%)	0.098 ^b
Onodi cell	40 (19.4%)	26 (20.3%)	14 (17.9%)	0.677 ^b
Haller cell	63 (30.6%)	44 (34.4%)	19 (24.4%)	0.130 ^b
Supraorbital Ethmoid cell	32 (15.5%)	27 (21.1%)	5 (6.4%)	0.005^b
<i>Variation of nasal turbinate</i>				
Sup. concha bulloza	4 (1.9%)	4 (3.1%)	0 (0.0%)	0.300 ^c
Middle concha bulloza	111 (53.9%)	63 (49.2%)	48 (61.5%)	0.085 ^b
Paradoxal middle concha	38 (18.4%)	26 (20.3%)	12 (15.4%)	0.376 ^b
<i>Paranasal sinus pneumatization variations</i>				
Frontal sinus hypoplasia	48 (23.3%)	30 (23.4%)	18 (23.1%)	0.953 ^b
Maxillary sinus hypoplasia	7 (3.4%)	6 (4.7%)	1 (1.3%)	0.257 ^c
<i>Accessory pneumatization variations</i>				
Uncinate bulla	18 (8.7%)	10 (7.8%)	8 (10.3%)	0.547 ^b
Anterior Clinoid Process pneumatization	72 (35.0%)	49 (38.3%)	23 (29.5%)	0.199 ^b
<i>Delano Classification</i>				
Type 1	99 (48.1%)	53 (41.4%)	46 (59.0%)	0.077 ^b
Type 2	73 (35.4%)	51 (39.8%)	22 (28.2%)	
Type 3	16 (7.8%)	10 (7.8%)	6 (7.7%)	
Type 4	18 (8.7%)	14 (10.9%)	4 (5.1%)	
<i>Keros Classification</i>				
Type 1	39 (18.9%)	27 (21.1%)	12 (15.4%)	0.349 ^b
Type 2	138 (67.0%)	81 (63.3%)	57 (73.1%)	
Type 3	29 (14.1%)	20 (15.6%)	9 (11.5%)	

Data summarized as median (IQR) or frequency (%). ^aMann Whitney U test ^bPearson's chi-square test ^cFisher's exact test. Bold p-values indicate statistical significance at $\alpha=0.05$. IQR: Interquartile range.

Table 2. Comparison of variables between NSD type as per angle classification

	Tip 1 (n=35)	Tip 2 (n=100)	Tip 3 (n=71)	p
Demographic variables				
Age	25.5 (17.3)	30.5 (17.8)	27.0 (18.0)	0.575 ^a
Gender				0.117 ^b
Male	18 (51.4%)	69 (69.0%)	41 (57.7%)	
Female	17 (48.6%)	31 (31.0%)	30 (42.3%)	
Variation of ethmoid air cell				
Agger nasi cell	19 (54.3%)	56 (56.0%)	42 (59.2%)	0.871 ^a
Onodi cell	7 (20.0%)	23 (23.0%)	10 (14.1%)	0.347 ^a
Haller cell	9 (25.7%)	34 (34.0%)	20 (28.2%)	0.567 ^a
Supraorbital Ethmoid cell	8 (22.9%)	15 (15.0%)	9 (12.7%)	0.388 ^a
Variation of nasal turbinate				
Sup. concha bulloza	0 (0.0%)	4 (4.0%)	0 (0.0%)	0.171 ^c
Middle concha bulloza	16 (45.7%)	55 (55.0%)	40 (56.3%)	0.559 ^b
Paradoxal middle concha	5 (14.3%)	14 (14.0%)	19 (26.8%)	0.083 ^b
Paranasal sinus pneumatization variations				
Frontal sinus hypoplasia	8 (22.9%)	20 (20.0%)	20 (28.2%)	0.460 ^b
Maxillary sinus hypoplasia	0 (0.0%)	4 (4.0%)	3 (4.2%)	0.679 ^c
Accessory pneumatization variations				
Uncinate bulla	5 (14.3%)	5 (5.0%)	8 (11.3%)	0.159 ^b
Anterior Clinoid Process pneumatization	15 (42.9)	30 (30.0)	27 (38.0)	0.311 ^b
Delano Classification				
Type 1	14 (40.0%)	52 (52.0%)	33 (46.5%)	0.801 ^b
Type 2	14 (40.0%)	31 (31.0%)	28 (39.4%)	
Type 3	4 (11.4%)	7 (7.0%)	5 (7.0%)	
Type 4	3 (8.6%)	10 (10.0%)	5 (7.0%)	
Keros Classification				
Type 1	4 (11.4%)	14 (14.0%)	21 (29.6%)	0.059 ^b
Type 2	24 (68.6%)	73 (73.0%)	41 (57.7%)	
Type 3	7 (20.0%)	13 (13.0%)	9 (12.7%)	

Data summarized as median (IQR) or frequency (%). ^aKruskal-Wallis test ^bPearson's chi-square test ^cFisher's exact test. Bold p-values indicate statistical significance at $\alpha=0.05$. IQR: Interquartile range.

Table 3. Correlations between anatomic variants

	Agger nasi			Onodi			Haller			Supraorbital Ethmoid		
	Yes	No	p	Yes	No	p	Yes	No	p	Yes	No	p
Agger nasi cell	-	-	-	21 (17.9%)	96 (82.1%)	0.541	38 (32.5)	79 (67.5)	0.498	18 (15.4%)	99 (84.6%)	0.946
				$(\phi=-0.043)$			$(\phi=0.047)$			$(\phi=-0.005)$		
Onodi cell	21 (52.5%)	19 (47.5%)	0.541	-	-	-	18 (45.0%)	22 (55.0%)	0.027	5 (12.5%)	35 (87.5%)	0.555
	$(\phi=0.043)$						$(\phi=0.154)$			$(\phi=-0.041)$		
Haller cell	38 (60.3%)	25 (39.7%)	0.498	18 (28.6%)	45 (71.4%)	0.027	-	-	-	12 (19.0%)	51 (81.0%)	0.355
	$(\phi=0.047)$			$(\phi=0.154)$						$(\phi=0.064)$		
Supraorbital Ethmoid cell	18 (56.3%)	14 (43.7%)	0.946	5 (15.6%)	27 (84.4%)	0.555	12 (37.5%)	20 (62.5%)	0.355	-	-	-
	$(\phi=-0.005)$			$(\phi=-0.041)$			$(\phi=0.064)$					
Sup. concha bullosa	3 (75.0%)	1 (25.0%)	0.635	1 (25.5%)	3 (75.0%)	1	2 (50.0%)	2 (50.0%)	0.587	1 (25.0%)	3 (75.0%)	1
	$(\phi=0.052)$			$(\phi=0.020)$			$(\phi=0.059)$			$(\phi=0.037)$		
Middle concha bullosa	63 (56.8%)	48 (43.2%)	0.99	24 (21.6%)	87 (78.4%)	0.387	33 (29.7%)	78 (70.3%)	0.774	17 (15.3%)	94 (84.7%)	0.925
	$(\phi=-0.001)$			$(\phi=0.060)$			$(\phi=-0.020)$			$(\phi=-0.007)$		
Paradoxal middle concha	25 (65.8%)	13 (34.2%)	0.215	9 (23.7%)	29 (76.3%)	0.462	12 (31.6%)	26 (68.4%)	0.883	4 (10.5%)	34 (89.5%)	0.345
	$(\phi=0.086)$			$(\phi=0.051)$			$(\phi=0.010)$			$(\phi=-0.066)$		
Frontal sinus hypoplasia	33 (68.8%)	15 (31.3%)	0.056	9 (18.8%)	39 (81.3%)	0.894	9 (18.8%)	39 (81.3%)	0.042	2 (4.2%)	46 (95.8%)	0.013
	$(\phi=0.133)$			$(\phi=-0.009)$			$(\phi=-0.142)$			$(\phi=-0.173)$		
Maxillary sinus hypoplasia	3 (42.9%)	4 (57.1%)	0.701	0 (0.0%)	7 (100.0%)	0.35	0 (0.0%)	7 (100.0%)	0.103	1 (14.3%)	6 (85.7%)	1
	$(\phi=-0.053)$			$(\phi=-0.092)$			$(\phi=-0.124)$			$(\phi=-0.006)$		
Uncinate bulla	8 (44.4%)	10 (55.6%)	0.268	3 (16.7%)	15 (83.3%)	1	6 (33.3%)	12 (66.7%)	0.791	6 (33.3%)	12 (66.7%)	0.041
	$(\phi=-0.077)$			$(\phi=-0.022)$			$(\phi=0.018)$			$(\phi=0.152)$		
Anterior Clinoid Process pneumatization	41 (56.9%)	31 (43.1%)	0.975	15 (20.8%)	57 (79.2%)	0.706	24 (33.3%)	48 (66.7%)	0.53	16 (22.2%)	57 (77.8%)	0.052
	$(\phi=0.002)$			$(\phi=0.026)$			$(\phi=0.044)$			$(\phi=0.135)$		

P-values are calculated from Pearson's chi-square or Fisher's exact test. ϕ : Phi correlation coefficient. Bold p-values indicate statistically significant correlation at $\alpha=0.05$.

Radiologic Analysis of Sinonasal Anatomical Variations

Table 3. (cont). Correlations between anatomic variants.

	Sup. Concha bulloza			Middle concha bulloza			Paradoxal middle concha			Frontal sinus hypoplasia		
	Yes	No	p	Yes	No	p	Yes	No	p	Yes	No	p
Agger nasi cell	3 (2.6%)	114 (97.4%)	0.635	63 (53.8%)	54 (46.2%)	0.99	25 (21.4%)	92 (78.6%)	0.215	33 (28.2%)	84 (71.8%)	0.056
	$(\phi=0.052)$			$(\phi=-0.001)$			$(\phi=0.086)$			$(\phi=0.133)$		
Onodi cell	1 (2.5%)	39 (97.5%)	1	24 (60.0%)	16 (40.0%)	0.387	9 (22.5%)	31 (77.5%)	0.462	9 (22.5%)	31 (77.5%)	0.894
	$(\phi=0.020)$			$(\phi=0.060)$			$(\phi=0.051)$			$(\phi=-0.009)$		
Haller cell	2 (3.2%)	61 (96.8%)	0.587	33 (52.4%)	30 (47.6%)	0.774	12 (19.0%)	51 (81.0%)	0.883	9 (14.3%)	54 (85.7%)	0.042
	$(\phi=0.059)$			$(\phi=-0.020)$			$(\phi=0.010)$			$(\phi=-0.142)$		
Supraorbital Ethmoid cell	1 (3.1%)	31 (96.9%)	1	17 (53.1%)	15 (46.9%)	0.925	4 (12.5%)	28 (87.5%)	0.345	2 (6.3%)	30 (93.8%)	0.013
	$(\phi=0.037)$			$(\phi=-0.007)$			$(\phi=-0.066)$			$(\phi=-0.173)$		
Sup. concha bullosa	-	-	-	2 (50.0%)	2 (50.0%)	1	0 (0.0%)	4 (100.0%)	1	1 (25.0%)	3 (75.0%)	1
				$(\phi=-0.011)$			$(\phi=-0.067)$			$(\phi=0.006)$		
Middle concha bulloza	2 (1.8%)	109 (98.2%)	1	-	-	-	23 (20.7%)	88 (79.3%)	0.363	23 (20.7%)	88 (79.3%)	0.344
	$(\phi=-0.011)$						$(\phi=0.063)$			$(\phi=-0.066)$		
Paradoxal middle concha	0 (0.0%)	38 (100.0%)	1	23 (60.5%)	15 (39.5%)	0.363	-	-	-	14 (36.8%)	24 (63.2%)	0.029
	$(\phi=-0.067)$			$(\phi=0.063)$						$(\phi=0.152)$		
Frontal sinus hypoplasia	1 (2.1%)	47 (97.9%)	1	23 (47.9%)	25 (52.1%)	0.344	14 (29.2%)	34 (70.8%)	0.029	-	-	-
	$(\phi=0.006)$			$(\phi=-0.066)$			$(\phi=0.152)$					
Maxillary sinus hypoplasia	0 (0.0%)	7 (100.0%)	1	4 (57.1%)	3 (42.9%)	1	1 (14.3%)	6 (85.7%)	1	2 (28.6%)	5 (71.4%)	0.666
	$(\phi=-0.026)$			$(\phi=0.012)$			$(\phi=-0.020)$			$(\phi=0.023)$		
Uncinate bulla	0 (0.0%)	18 (100.0%)	1	10 (55.6%)	8 (44.4%)	0.882	2 (11.1%)	16 (88.9%)	0.536	3 (16.7%)	15 (83.3%)	0.77
	$(\phi=-0.044)$			$(\phi=0.010)$			$(\phi=-0.059)$			$(\phi=-0.049)$		
Anterior Clinoid Process pneumatization	0 (0.0%)	72 (100.0%)	0.3	36 (50.0%)	36 (50.0%)	0.412	14 (19.4%)	58 (80.6%)	0.787	12 (16.7%)	60 (83.3%)	0.099
	$(\phi=-0.103)$			$(\phi=-0.057)$			$(\phi=0.019)$			$(\phi=-0.115)$		

P-values are calculated from Pearson's chi-square or Fisher's exact test. ϕ : Phi correlation coefficient. Bold p-values indicate statistically significant correlation at $\alpha=0.05$

Table 3 (cont). Correlations between anatomic variants.

	Maxillary sinus hypoplasia			Uncinate bulla			Anterior Clinoid Process		
	Yes	No	p	Yes	No	p	Yes	No	p
Agger nasi cell	3 (2.6%)	114 (97.4%)	0.701	8 (6.8%)	10 (93.2%)	0.268	41 (35.0%)	76 (65.0%)	0.975
	$(\phi=-0.053)$			$(\phi=-0.077)$			$(\phi=0.002)$		
Onodi cell	0 (0.0%)	40 (100.0%)	0.35	3 (7.5%)	37 (92.5%)	1	15 (37.5%)	25 (62.5%)	0.706
	$(\phi=-0.092)$			$(\phi=-0.022)$			$(\phi=0.026)$		
Haller cell	0 (0.0%)	63 (100.0%)	0.103	6 (9.5%)	57 (90.5%)	0.791	24 (38.1%)	39 (61.9%)	0.53
	$(\phi=-0.124)$			$(\phi=0.018)$			$(\phi=0.044)$		
Supraorbital Ethmoid cell	1 (3.1%)	31 (96.9%)	1	6 (18.7%)	26 (81.3%)	0.041	16 (50.0%)	16 (50.0%)	0.052
	$(\phi=-0.006)$			$(\phi=0.152)$			$(\phi=0.135)$		
Sup. concha bulloza cell	0 (0.0%)	4 (100.0%)	1	0 (0.0%)	4 (100.0%)	1	0 (0.0%)	4 (100.0%)	0.3
	$(\phi=-0.026)$			$(\phi=-0.044)$			$(\phi=-0.103)$		
Middle concha bulloza	4 (3.6%)	107 (96.4%)	1	10 (9.0%)	101 (91.0%)	0.882	36 (32.4%)	75 (67.6%)	0.412
	$(\phi=0.012)$			$(\phi=0.010)$			$(\phi=-0.057)$		
Paradoxal middle concha	1 (2.6%)	37 (97.4%)	1	2 (5.3%)	36 (94.7%)	0.536	14 (36.8%)	24 (63.2%)	0.787
	$(\phi=-0.020)$			$(\phi=-0.059)$			$(\phi=0.019)$		
Frontal sinus hypoplasia	2 (4.2%)	46 (95.8%)	0.666	3 (6.3%)	45 (93.8%)	0.77	12 (25.0%)	36 (75.0%)	0.099
	$(\phi=0.023)$			$(\phi=-0.049)$			$(\phi=-0.115)$		
Maxillary sinus hypoplasia	-	-	-	0 (0.0%)	7 (100.0%)	1	1 (14.3%)	6 (85.7%)	0.425
				$(\phi=-0.058)$			$(\phi=-0.081)$		
Uncinate bulla	0 (0.0%)	40 (100.0%)	0.35	3 (7.5%)	37 (92.5%)	1	15 (37.5%)	25 (62.5%)	0.706
	$(\phi=-0.092)$			$(\phi=-0.022)$			$(\phi=0.026)$		
Anterior Clinoid Process pneumatization	0 (0.0%)	63 (100.0%)	0.103	6 (9.5%)	57 (90.5%)	0.791	24 (38.1%)	39 (61.9%)	0.53
	$(\phi=-0.124)$			$(\phi=0.018)$			$(\phi=0.044)$		

P-values are calculated from Pearson’s chi-square or Fisher’s exact test. ϕ : Phi correlation coefficient. Bold p-values indicate statistically significant correlation at $\alpha=0.05$.

There is no significant correlation between the presence of onodi cell and ACPP ($\phi = 0.026$, $p = 0.706$) (Figure 6).

A significant association was observed between Delano classification and presence of ACPP ($p < 0.001$) (Figure 7). While the majority of the patients with ACPP have Type 2 Delano classification ($n = 34$, 47.2 %) (Figure 5), ACPP was present in all patients in the type 3 Delano group (Figure 7).

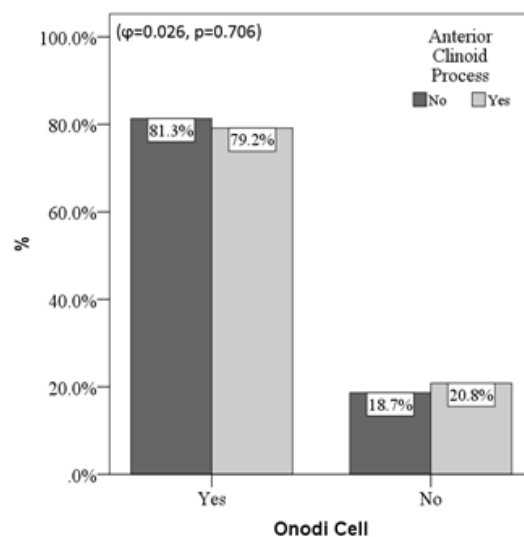


Figure 6. Association between the presence of onodi cell and Anterior Clinoid Process pneumatization

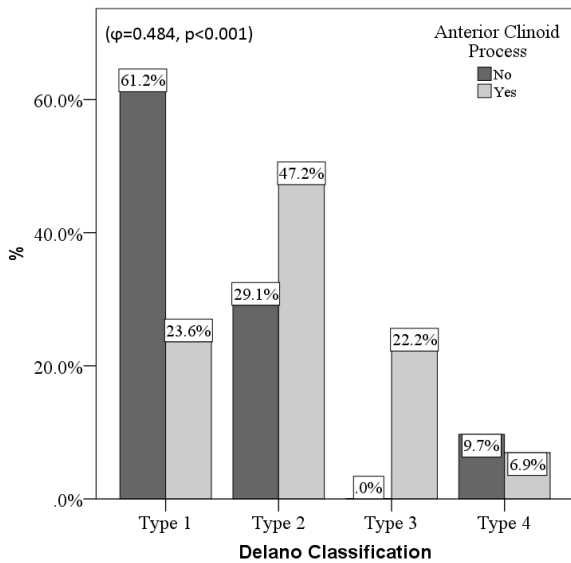


Figure 7. Association between Delano classification and presence of Anterior Clinoid Process Pneumatization.

Discussion

Various classification systems have been defined for typing NSD in the literature. Mladina et al. (Mladina et al., 2008) defined the Mladina classification for NSD typing and reported that the most frequently type was type 3. Haytoglu et al. (Haytoglu et al., 2017) reported that type 2 is the most frequently type in patients with septoplasty. In our study, unlike the literature findings, the most frequently NSD type was type 4 in men and type 7 in women. These differences in the literature may result from differences of geographic regions.

Based on the literature, many studies have investigated the frequency of concurrence of concha bullosa with septum deviation, which is one of the sinonasal anatomical variations (Koo et al., 2017; El-Taher et al., 2019). The various incidence rates of concha bullosa with septal deviation have been reported (Yigit et al, 2010) 45.34 %, Yazici et al. (Yazici, 2019) 45.3 %, Koo et al. (Koo et al., 2017) 52.4 %). In our study, the incidence of concha bullosa was 53.9 % by these studies previous studies showing that the NSD angle is related to the concha bullosa (Uygur et al., 2003; El-Taher et al., 2019). Contrary to these findings, any relationship between the NSD angle, and concha bullosa was not found in our study.

The incidence of paradoxal middle turbinates, which is one of the anatomical variations of turbinates, ranges from 3 to 40 % in the literature (Bolger et al., 1991; Ozcan et al., 2008). In our study, paradoxal middle turbinate incidence was 18.4 % and this rate was compatible with the literature.

The prevalence of the Haller cell, which is one of the ethmoid air cell variants, varies between 2.7 –

45.1 % in the literature (Bolger et al., 1991; Yazici, 2019). Shokri et al. (Shokri et al., 2019) found a correlation between Haller cell and NSD. In our study, the incidence of the Haller cell was 30.6 %. We found a significant correlation between Haller cell and Onodi cell and frontal sinus hypoplasia. The presence of sinonasal anatomical variants and correlations between them are important in order to establish a diagnosis and treatment plan and to prevent possible surgical complications.

The prevalence of supraorbital ethmoid cell, which is important for safe dissection of the frontal ostium, varies in the literature by ethnic origin (Zhang et al., 2007). The incidence of supraorbital ethmoid cell has been reported as 5.3 % and its association with the anterior ethmoid artery has been shown (Zhang et al., 2007). In our study, the incidence of supraorbital ethmoid cells was 15.5 % and it was significantly higher in men compared to women [27 (21.1 %) vs. 5 (6.4 %)]. We also found a significant correlation between supraorbital cell, paradoxal middle turbinate and uncinata bulla. The prevalence of uncinata bulla, which is a rare anatomic variant that can lead to narrowing of the infundibulum, varies between 0.4-13 % in the literature (Fadda et al., 2012; Yazici, 2019). In our study, the incidence of uncinata bulla was 8.7 % and it were in concordance with the literature.

In order to prevent vital complications that may occur during transsphenoidal and skull base surgery, it is essential to identify anatomic variations associated with the SS preoperatively. Removal of the ACPP during skull base surgery carries the risk of cerebrospinal fluid rhinorrhea and associated sepsis (Nandapalan et al., 1996; Sirikci et al., 2000). Prior to skull base surgery, the risk of this complication is reduced by identifying ACPP in paranasal CT and preferring extradural approach (Noguchi et al., 2005). In the literature, the prevalence rates of ACPP, and Onodi cell were reported to range between 13.3 – 16 %, and 0 - 18 %, respectively (17,23,25) (Bolger et al., 1991; Sirikci et al., 2000; Unal et al., 2006). In a study of patients with NSD, Onodi cells, and ACPP were seen in 2 %, and 29.3 % of the patients respectively. In our study, Onodi cells and ACPP were seen in 19.4 %, and 35 % of the patients, respectively which were higher when compared with the literature findings. In NSD patients, changes in the turbulence of airflow through the nasal cavity or genetic mechanisms may be associated with pneumatization anomalies. Pneumatization of the anterior clinoid process may cause the optic nerve to medialize into the SS during the development process. Studies have reported that ACPP is

associated with optic nerve protrusion (Sapci et al., 2004; Itagi et al., 2017). In our study, we identified a positive correlation between ACP and Delano type 2 and 3, where the optic nerve protrudes into the SS. Especially in patients with NSD, the identification of ACP by examining paranasal CTs in detail before transsphenoidal and skull base surgery reduces the risks of complications that may occur.

A limitation of the present study is that it was retrospective and not having a control group of patients without septum deviation. Further studies including large numbers of case-control studies are necessary to evaluate the relationship of septal deviation with sinonasal anatomic variants.

Conclusion

In our study, the incidence of onodi cell, supraorbital ethmoid cell, anterior clinoid process pneumatization were more frequent in patients with nasal septal deviation compared to the literature. However, there is no significant difference was found between NSD types as per angle classification in terms of the presence of sinonasal variation. Careful examination of paranasal CTs before craniomaxillofacial surgeries is important to determine sinonasal anatomic variants, to determine the appropriate treatment plan and to prevent possible complications preoperatively.

Ethics Committee Approval: This retrospective study was performed after approval of the Abant Izzet Baysal University ethics committee in accordance with the Helsinki declaration (07.03. 2019 2019/63).

Peer-review: Externally peer-reviewed.

Author Contributions: Concept -E.K A.G E.D Design E.K E.D Z.C; Audit E.K E.D A.G AU.; Materials – E.K E.D Z.C Data Collection and / or Processing – E.K O.K A.U Analysis and / or Interpretation – E.K O.K A.G Z.C ; Literature review – E.K A.G E.D Z.C.; Text – E.K E.D O.K; Critical Review – E.K A.U O.K

Conflict of Interest: No conflict of interest was declared by the authors.

Financial Disclosure: The authors declared that this study hasn't received no financial support.

References

- Akoglu E, Karazincir S, Balci A, Okuyucu SS, Sumbas H, Dagli AS. Evaluation of the turbinate hypertrophy by computed tomography in patients with deviated nasal septum. *Otolaryngol - Head Neck Surg* 2007;136:380–4. <https://doi.org/10.1016/j.otohns.2006.09.006>.
- Alkire BC, Bhattacharyya N. An assessment of sinonasal anatomic variants potentially associated with recurrent acute rhinosinusitis. *Laryngoscope* 2010;120:631–4. <https://doi.org/10.1002/lary.20804>.
- Bolger WE, Parsons DS, Butzin CA. Paranasal sinus bony anatomic variations and mucosal abnormalities: CT analysis for endoscopic sinus surgery. *Laryngoscope* 1991. <https://doi.org/10.1288/00005537-199101000-00010>.
- Delano MC, Fun FY, Zinreich SJ. Relationship of the optic nerve to the posterior paranasal sinuses: A CT anatomic study. *Am J Neuroradiol* 1996. [https://doi.org/10.1016/s0196-0709\(97\)90018-1](https://doi.org/10.1016/s0196-0709(97)90018-1).
- El-Taher M, AbdelHameed WA, Alam-Eldeen MH, Haridy A. Coincidence of Concha Bullosa with Nasal Septal Deviation; Radiological Study. *Indian J Otolaryngol Head Neck Surg* 2019. <https://doi.org/10.1007/s12070-018-1311-x>.
- Elahi MM, Frenkiel S, Fageeh N. Paraseptal structural changes and chronic sinus disease in relation to the deviated septum. *J Otolaryngol* 1997.
- Fadda GL, Rosso S, Aversa S, Petrelli A, Ondolo C, Succo G. Multiparametric statistical correlations between paranasal sinus anatomic variations and chronic rhinosinusitis. *Acta Otorhinolaryngol Ital* 2012;32:244–51.
- Haytoglu S, Dengiz R, Muluk NB, Kuran G, Arıkan OK. Effects of septoplasty on olfactory function evaluated by the Brief Smell Identification Test: A study of 116 patients. *Ear, Nose Throat J* 2017. <https://doi.org/10.1177/0145561317096010-1123>.
- Itagi RM, Adiga CP, Kalenahalli K, Goolahally L, Gyanchandani M. Optic nerve canal relation to posterior paranasal sinuses in indian ethnics: Review and objective classification. *J Clin Diagnostic Res* 2017. <https://doi.org/10.7860/JCDR/2017/23447.9510>.
- Kantarci M, Karasen RM, Alper F, Onbas O, Okur A, Karaman A. Remarkable anatomic variations in paranasal sinus region and their clinical importance. *Eur J Radiol* 2004;50:296–302. <https://doi.org/10.1016/j.ejrad.2003.08.012>.

- Koo SK, Kim JD, Moon JS, Jung SH, Lee SH. The incidence of concha bullosa, unusual anatomic variation and its relationship to nasal septal deviation: A retrospective radiologic study. *Auris Nasus Larynx* 2017;44:561–70. <https://doi.org/10.1016/j.anl.2017.01.003>.
- Mladina R, Čujčić E, Šbarić M, Vuković K. Nasal septal deformities in ear, nose, and throat patients. An international study. *Am J Otolaryngol - Head Neck Med Surg* 2008. <https://doi.org/10.1016/j.amjoto.2007.02.002>.
- Nandapalan V, Watson ID, Swift AC. Beta-2-transferrin and cerebrospinal fluid rhinorrhoea. *Clin Otolaryngol Allied Sci* 1996. <https://doi.org/10.1111/j.1365-2273.1996.tb01737.x>.
- Noguchi A, Balasingam V, Shiokawa Y, McMenomey SO, Delashaw JB. Extradural anterior clinoidectomy. Technical note. *J Neurosurg* 2005. <https://doi.org/10.3171/jns.2005.102.5.0945>.
- Ozcan KM, Selcuk A, Ozcan I, Akdogan O, Dere H. Anatomical Variations of Nasal Turbinates. *J Craniofac Surg* 2008. <https://doi.org/10.1097/SCS.0b013e318188a29d>.
- Sapci T, Derin E, Almaç S, Cumali R, Saydam B, Karavus M. The relationship between the sphenoid and the posterior ethmoid sinuses and the optic nerves in Turkish patients. *Rhinology* 2004.
- Shokri A, Faradmal MJ, Hekmat B. Correlations between anatomical variations of the nasal cavity and ethmoidal sinuses on cone-beam computed tomography scans. *Imaging Sci Dent* 2019;49:103–13. <https://doi.org/10.5624/isd.2019.49.2.103>.
- Sirikci A, Bayazit YA, Bayram M, Mumbuc S, Gungor K, Kanlikama M. Variations of sphenoid and related structures. *Eur Radiol* 2000. <https://doi.org/10.1007/s003300051016>.
- Unal B, Bademci G, Bilgili YK, Batay F, Avci E. Risky anatomic variations of sphenoid sinus for surgery. *Surg Radiol Anat* 2006. <https://doi.org/10.1007/s00276-005-0073-9>.
- Uygun K, Tuz M, Dogru H. The correlation between septal deviation and concha bullosa. *Otolaryngol - Head Neck Surg* 2003. [https://doi.org/10.1016/S0194-5998\(03\)00479-0](https://doi.org/10.1016/S0194-5998(03)00479-0).
- Wuister AMH, Goto NA, Oostveen EJ, De Jong WU, Van Der Valk ES, Kaper NM, et al. Nasal endoscopy is recommended for diagnosing adults with chronic rhinosinusitis. *Otolaryngol - Head Neck Surg (United States)* 2014;150:359–64. <https://doi.org/10.1177/0194599813514510>.
- Yazici D. The analysis of computed tomography of paranasal sinuses in nasal septal deviation. *J Craniofac Surg* 2019;30:E143–7. <https://doi.org/10.1097/SCS.0000000000005077>.
- Yigit O, Acioglu E, Cakir ZA, Sisman AS, Barut AY. Concha bullosa and septal deviation. *Eur Arch Oto-Rhino-Laryngology* 2010;267:1397–401. <https://doi.org/10.1007/s00405-010-1228-9>.
- Zhang L, Han D, Ge W, Tao J, Wang X, Li Y, et al. Computed tomographic and endoscopic analysis of supraorbital ethmoid cells. *Otolaryngol - Head Neck Surg* 2007. <https://doi.org/10.1016/j.otohns.2007.06.737>.