

Peptik Ülser Perforasyonlarında Nonoperatif Tedavi ve Literatürün Gözden Geçirilmesi

Nonoperative Treatment in Peptic Ulcer Perforations and Review of the Literature

Ahmet BOZDAG¹, Baris GULTURK², Ali AKSU², Nizamettin KUTLUER², Mehmet Bugra BOZAN³,
Tamer GUNDOGDU², Abdullah BOYUK²

¹ Fırat University, Faculty of Medicine, Department of General Surgery, Elazığ, Turkey

² Health Sciences University, Elazığ Health Application and Research Center, General Surgery Department, Elazığ, Turkey

³ Sıtcu Imam University, Faculty of Medicine, Department of General Surgery, Kahramanmaraş, Turkey

ÖZET

Amaç: Peptik ülser perforasyonu acil servislere sık karşılaşılan peptik ülser hastalığının bir komplikasyonudur. Peptik ülser perforasyonlarında non-operatif tedaviden geniş rezeksiyonlara kadar pek çok tedavi seçeneği olmasına rağmen ilk tedavi seçeneği cerrahidir. Bu makalede uygun ve seçilmiş olgularda non-operatif tedavinin uygulanabilirliğini sunmayı amaçladık.

Gereç ve Yöntemler: Kliniğimizde Ocak 2016 – Temmuz 2018 tarihleri arasında perforere peptik ülser hastalığında cerrahi uygulanmayıp medikal tedavi edilen hastaların verileri retrospektif olarak değerlendirilmiştir.

Bulgular: Hastaların üçü erkek biri kadın ve ortalama yaşları 58 (35-79) idi. Hastaların fizik muayenesinde akut karın bulguları yok, sadece sağ üst kadranda ve epigastrik bölgede hassasiyet vardı. Üç hastada ayakta direkt karın grafisinde diyafragma altında serbest hava vardı. Bir hastada ise tanı tomografik bulgularla konuldu. Hiçbir hastada kontrast madde ekstravazasyonu görülmedi. Hastalar uzman bir cerrah tarafından aralıklı muayene edildi ve yatışının 4. günü oral beslenme başlanıp ortalama 7. günde hastalar taburcu edildi.

Sonuç: Peptik ülser perforasyonu halen sık karşılaşılan ve akut karın tablosu gelişmiş ise acil cerrahi gerektiren bir durumdur. Her ne kadar perforasyon sonrası geçen süre mortalite ve morbitideyi etkilese de suda çözünen kontrast madde ile çekilen tomografide ekstravazasyon ve fizik muayenede yaygın peritonit hali yoksa, uygun ve seçilmiş hastalarda sıkı fizik muayene ve laboratuvar takibi altında başarıyla uygulanabilir bir yöntemdir.

Anahtar Kelimeler: Peptik ülser, Peptik ülser perforasyonu, Tedavi

Abstract

Objective: Peptic ulcer perforation is a complication of peptic ulcer disease frequently encountered in the emergency departments. Although there are many treatment options ranging from non-operative treatment to wide resections, surgery is the first treatment option in peptic ulcer perforations. In this article, we aimed to present the feasibility of non-operative treatment in appropriate and selected cases.

Material and Methods: The data of the patients with perforated peptic ulcer who were not operated but provided with medical treatment in our clinic between January 2016 and July 2018 were evaluated retrospectively.

Results: Three of the patients were male, one of them was female, and the mean age was 58 years (range, 35-79). On physical examination, there were no signs of acute abdomen, only tenderness was observed in the right upper quadrant and epigastric region. Standing direct abdominal radiography revealed free air under the diaphragm in three patients. The diagnosis was made with tomographic findings in one patient. No contrast agent extravasation was observed in any patient. The patients were examined intermittently by a specialist surgeon, oral intake was permitted on the 4th day of hospitalization, and they were discharged on the 7th day on average.

Conclusion: Peptic ulcer perforation is a condition, which is still common and requires emergency surgery in case of acute abdomen development. Although the time elapsed after perforation is a factor affecting mortality and morbidity, non-operative treatment is a method that can be successfully applied under strict physical examination and laboratory follow-up in appropriate and selected patients without diffuse peritonitis and extravasation on CT with water-soluble contrast agent.

Keywords: Peptic Ulcer, Peptic Ulcer Perforation, Treatment

Yazışma Adresi: Ahmet BOZDAĞ, Fırat Üniversitesi Tıp Fakültesi Genel Cerrahi ABD, Elazığ, Türkiye

Telefon: +90 533 652 51 63, Mail: abozdag80@hotmail.com

ORCID No (Sırasıyla): 0000-0003-1973-2511, 0000-0003-4511-3693, 0000-0002-9226-1720, 0000-0002-1092-2979, 0000-0001-5573-2645, 0000-0001-6820-9570, 0000-0003-0628-9303

Geliş Tarihi: 09.11.2020

Kabul Tarihi: 15.01.2021

DOI: 10.17517/ksutfd.823603

INTRODUCTION

Although peptic ulcer disease has decreased with the widespread use of proton pump inhibitors, many risk factors that cannot be removed from our lives such as *Helicobacter Pylori* (*H.Pylori*) infection, nonsteroidal anti-inflammatory drugs, corticosteroids, bisphosphonates, smoking, alcohol and stress are found to increase the occurrence of the disease. Peptic ulcer perforation (PUP) still means surgical treatment for many surgeons. Treatment options range from medical therapy to extensive resections.

The idea that PUP could be treated without surgical intervention dates back to the 1840s (1). Wangensteen first proposed a conservative approach to PUP in 1935. However, uncertainty continues about to whom and with which indications non-operative treatment (NOT) will be applied. Although various scoring systems were tried to be established for this purpose, none of them were accepted. Therefore, NOT has been limited to very few patients with radiologically shown closed perforation and without clinical peritonitis (2,4). In this study, we wanted to retrospectively present the patients undergoing NOT and remind the feasibility of NOT to selected and appropriate patients in the light of the literature.

MATERIAL AND METHODS

The patients who were admitted to the general surgery clinic of Elazig Training and Research Hospital between January 2016 and July 2018 with the diagnosis of PUP were scanned through the patient information system. A total of 21 patients were hospitalized with the diagnosis of PUP, 17 patients underwent surgical treatment. Open Graham patch repair was performed in 10 (47.6%) patients, and laparoscopic Graham patch repair was performed in 7 (33.3%) patients according to the surgeon's experience and the general condition of the patient. Comorbid diseases, especially such as chronic obstructive pulmonary disease, were present in five patients undergoing open surgery and postoperative mortality was observed in three of them. Those undergoing surgical treatment were excluded from the study. The data of four patients (19.04%) who were not operated but provided with medical treatment were evaluated retrospectively. For this study, permission was obtained from the Firat University Non-Invasive Research Ethics Committee and informed consent from the patients (12.06.2020 date 2020/09-14 Number). This study was conducted in accordance with the Declaration of Helsinki.

RESULTS

Three of our patients were male, and one of them was female. The mean age was 58 years (range, 35-79). All patients were hospitalized with the complaint of localized abdominal pain in the epigastric region that had been going on for several days. Vital signs were stable on physical examination. Therefore, patients were followed up in a normal room and did not require intensive care. Abdominal examination re-

vealed tenderness in the right upper quadrant and epigastric region. There was no rebound tenderness or rigidity. In the laboratory examination, no significant finding was found except leukocytosis and high C-reactive protein (CRP). On radiological examination, standing direct abdominal radiography revealed free air under the diaphragm in three patients (**Figure 1, 2**).

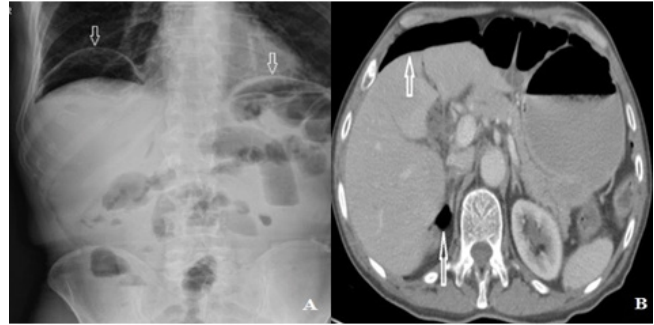


Figure 1. Direct abdominal radiography and tomography images of 35 years female patient. Arrows show free air.

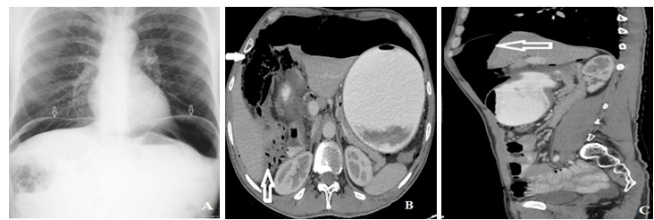


Figure 2. Direct abdominal radiography (A), axial abdominal tomography image (B), sagittal abdominal tomography image (C) 50 years male patient. Arrows show free air in abdominal area and retroperitoneum.

Abdominal ultrasonographies performed were reported as normal. Abdominal computed tomography (CT) revealed free air values in the right subdiaphragmatic area and adrenal lodge and findings compatible with contamination, edema and minimal fluid in fatty tissue of the paraduodenal area (**Figure 1, 2**). No contrast agent extravasation was observed in any patient. No free air was observed in the subdiaphragmatic areas on standing direct abdominal radiography and abdominal CT of a patient, but CT revealed free air values in the paraduodenal area and contamination, edema, and minimal fluid in fatty tissue of the same area (**Table 1**).

Diagnoses were made with clinical and radiological findings. It was concluded that medical treatment could be applied due to the absence of septic shock and diffuse peritonitis signs despite ongoing complaints of all patients for several days. Oral intake was stopped, and intravenous fluid therapy was started in all patients. The nasogastric catheter was inserted and left to free drainage and empirical antibiotic therapy was started. The patients were followed up by performing intermittent physical examinations. On the 4th day of

Table 1. The demographic characteristics, white blood cell counts and imaging findings of the patients.

Patient no.	Age (Year)	Gender	White blood cell count (K/uL)	Direct Radiography (free air)	Sonography (free fluid)	Computed tomography (free air location)
1	35	Female	12000	Yes	No	Free air
2	50	Male	18000	Yes	No	Free air
3	68	Male	14000	No	No	Paraduodenal
4	79	Male	17000	Yes	No	Free air

follow-up, oral intake was started in the patients without any problems during their follow-up. The mean length of hospital stay was 7 days. The patients were discharged with H. Pylori eradication treatment. After about six weeks, peptic ulcer disease was detected in all patients undergoing elective endoscopy.

DISCUSSION

Advances in the medical treatment of peptic ulcer disease have significantly reduced surgical treatment in uncomplicated ulcer patients. However, complications such as bleeding, obstruction and perforation are still frequently encountered (5). PUP is common in the 4th or 5th decades of life, and the male / female ratio is 2.8 / 1. In accordance with the literature, there were one female and three male patients, and one of them were over 60 years of age in our study. PUP is a common emergency condition worldwide, and its mortality rate varies between 6% and 30% (5,6). Late admission to the hospital, large perforation diameter, being over 60 years of age, presence of shock signs, presence of comorbid diseases and perforation in gastric localization are among the poor prognostic factors. Besides, preoperative hemodynamic shock, sepsis and diffuse peritonitis are other important factors affecting morbidity and mortality (4,5). One of our patients had only one of these factors, being over 60 years of age, and no other poor prognostic factors were observed.

The first literature data that led to the formation of the idea of NOT in PUP was obtained in 1843, when Crisp stated that perforation could be closed with adhesions, and continued to be extended in 1935 when Wangenstein reported that he applied NOT to 7 cases, but did not receive much attention (7,8). Then, in 1946, Taylor followed 28 patients with PUP nonoperatively and reported that 24 of these patients recovered without complications, 3 patients died due to non-ulcerative reasons and one patient died due to ulcerative reasons, which popularized NOT (2). Songne et al. reported that they treated 54% of the patients having PUP with a conservative approach without any surgery in their study (9). In another study, 41 patients were reported to be provided with NOT successfully without increasing morbidity in a series of 50 patients (10). The study with the highest number of patients reported the morbidity rate of NOT as 15.9%, the morbidity of surgical treatment as 17.2%, the rate of overall mortality as 5.4% and that NOT did not extend the length of

hospital stay and did not increase hospital cost for appropriate patients (10). Recent publications have reported that the morbidity and mortality rates of conservative treatment are between 0-8%, and the mortality rates of emergency surgical treatment are between 3-9% (4,10,11). The reason for the low morbidity and mortality rates in the patients undergoing NOT is that this group of patients consisted of selected cases without diffuse peritonitis. No complication or mortality was observed in our four patients.

The guideline published by the World Society of Emergency Surgery states that the presence of a gastroduodenal perforation can be detected with a plain chest radiograph, as well as free air in the abdomen with an ultrasound examined by an experienced radiologist (12). CT findings cover many appearances such as unexplained intraperitoneal fluid, pneumoperitoneum, bowel wall thickening, mesenteric fat line and presence of extraluminal water-soluble contrast. Indeed, CT imaging is more sensitive in detecting free air. In addition, it is an increasingly applied imaging method in the diagnosis of perforation due to its ability to determine the size of the perforation with the perforation area and to exclude other possible causes (13, 14, 15). Abdominal free air is an indication of PUP. However, it may be indicative of other intraabdominal luminal organ perforation. The definitive diagnosis can be made if there is no contrast extravasation in tomography or by laparotomy. The presence of paraduodenal fluid may be helpful in the differential diagnosis. In all of our cases, there was fluid around the duodenum on tomography. Therefore, they were evaluated in favor of PUP. Other causes of pneumoperitoneum should be investigated in non-fluid cases. In the radiological evaluation of our patients, free air was found on direct abdominal radiography in three patients. Sonographic examinations of all patients were normal. On CT of our three patients, we detected free air in the paraduodenal area or subdiaphragmatic area. Contrast material extravasation was not observed in any patient.

There are many treatment options ranging from NOT to wide resections in PUP. The choice of treatment depends on the general condition of the patients and the type of perforations. Two types of PUP have been described. The first and the most common is the type, where duodenal content flows into the abdominal cavity and causes the formation of peritonitis, requiring surgical treatment. The second is the type where

leakage is prevented by the omentum or surrounding tissues sticking to the perforation area despite PUP formation also observed during surgery. Peritonitis signs are not observed in this group of patients. These patients are the candidates for NOT. Clinical pictures of our patients and publications in the literature have suggested a conservative approach to those with closed perforation. It can be radiologically shown that there is no intraabdominal leakage by sonography or tomography with water-soluble contrast agent (17). NOT is indicated in cases where closed perforation is radiologically shown and there is no clinical peritonitis. Peritonitis signs can be evaluated by physical examination, vital signs and biochemical parameters, whether the patient has septic manifestations or various scoring systems in the literature (Boey score, ASA and PULP score) (12). Our patients had local tenderness in the epigastric region and right upper quadrant, but there was no acute abdomen. Standing direct abdominal radiography revealed free air under the diaphragm in three patients. However, CT revealed an appearance compatible with closed PUP. NOT was decided in these patients without diffuse peritonitis and acute abdominal signs, considering closed PUP.

Early diagnosis and correct treatment significantly reduce the risk of morbidity and mortality. One of the biggest concerns about the conservative method is to cause misdiagnosis or delay of treatment. However, with a regular physical examination and patient monitoring, misdiagnosis can be quickly identified, and conservative treatment can be ended (2). We managed the treatment under strict physical examination and laboratory follow-up in these selected cases thought to be the candidates for NOT. The most important limitations of this study are the small number of patients and retrospective design. However, very few prospective randomized studies are available in the literature.

Although PUP is the second most common complication of peptic ulcer disease, it has recently been a more common indication for operation. It appears with serious mortality and morbidity. Although the time elapsed after perforation is a factor affecting mortality and morbidity, we think that non-operative treatment is a method that can be applied under strict physical examination and laboratory follow-up in appropriate and selected patients without septic shock, diffuse peritonitis and extravasation on CT with water-soluble contrast agent.

Conflict of Interest and Financial Status: Our study has not been financed by an institution and institution. In this study, there is no conflict of interest among the authors on any subject.

Author Contribution: All authors contributed equally to the article.

REFERENCES

- Vijayakumar A, Mallikarjuna MN, Vijayraj P, Ajitha N, Shivaswamy BS. Non operative management of perforated peptic ulcer an algorithm approach. *Int J Biomed Adv Res* 2013; 4: 67–72.
- Taylor H. Peptic ulcer perforation treated without operation. *Lancet*.1946; 2(6422) : 441-44.
- Crofts TJ, Park KG, Steele RJ, Chung SS, Li AK. A randomized trial of nonoperative treatment for perforated peptic ulcer. *N Engl J Med*. 1989; 320: 970-73.
- Cao F, Li J, Li A, Fang Y, Wang Y, Li F. Nonoperative management for perforated peptic ulcer: Who can benefit? *Asian Journal of Surgery*. 2014; 37: 148-53.
- Taş İ, Ülger BV, Önder A, Kapan M, Bozdağ Z. Risk factors influencing morbidity and mortality in perforated peptic ulcer disease. *Ulusal Cer Derg* 2015; 31: 20-5.
- Kim JM, Jeong SH, Lee YJ, Park ST, Choi SK, Hong SC, et al. Analysis of risk factors for postoperative morbidity in perforated peptic ulcer. *J Gastric Cancer* 2012; 12: 26-35.
- Crisp E. Cases of perforation of the stomach with deductions therefrom relative to the character and treatment of that lesion. *Lancet*. 1843; 2639.
- Wangensteen OH. Nonoperative treatment of localized perforations of the duodenum. *Minn Med*. 1935; 18: 477-80.
- Songne B, Jean F, Foulatier O, Khalil H, Scotte M. Nonoperative treatment for perforated peptic ulcer: results of a prospective study. *AnnChir*2004; 129: 578-82.
- Hanumanthappa M.B, Gopinathan S, Guruprasad Rai D, NeilDsouza. A Non-operative Treatment of Perforated Peptic Ulcer: A Prospective Study with 50 Cases, *Journal of Clinical and Diagnostic Research*. 2012; 6(4): 696-99.
- Nusree R. Conservative Management of Perforated Peptic Ulcer. *The Thai Journal of Surgery* 2005; 26:5-8.
- Tarasconi, A, Coccolini, F, Biffl, W.L., Tomasoni M, Ansaloni L, Picetti E. et al. Perforated and bleeding peptic ulcer: WSES guidelines. *World J Emerg Surg*. 2020; 15: 3.
- Thorsen K, Glomsaker TB, von Meer A, Soreide K, Soreide JA. Trends in diagnosis and surgical management of patients with perforated peptic ulcer. *Gastrointest Surg*. 2011; 15: 1329–35.
- Grassi R, Romano S, Pinto A, Romano L. Gastro-duodenal perforations: conventional plain film, US and CT findings in 166 consecutive patients. *Eur J Radiol*. 2004; 50: 30–6.
- Yeung K-W, Chang M-S, Hsiao C-P, Huang J-F. CT evaluation of gastrointestinal tract perforation. *Clinical Imaging*. 2004; 28: 329–33.
- Malhotra AK, Fabian TC, Katsis SB, Gavant ML, Croce MA. Blunt Bowel and Mesenteric Injuries: The Role of Screening Computed Tomography. *J Trauma*. 2000; 48: 991–1000.
- Fujii Y, Asato M, Taniguchi N, Shigeta K, Omoto K, Itoh K. et al. Sonographic Diagnosis and Successful Nonoperative Management of Sealed Perforated Duodenal Ulcer. *J Clin Ultrasound* 2003; 31:1.