

# Is There a Correlation Between Benign Paroxysmal Positional Vertigo and Indirect Sinus Lifting?

Onur Atal<sup>1</sup> , Gühan Dergin<sup>1</sup> , Murat Sari<sup>2</sup> 

<sup>1</sup> Marmara University, Faculty of Dentistry, Department of Oral and Maxillofacial Surgery, Istanbul, Türkiye.

<sup>2</sup> Private Practice, Istanbul, Türkiye.

**Correspondence Author:** Onur Atal

**E-mail:** atalionur@gmail.com

**Received:** 17.11.2020

**Accepted:** 03.11.2021

## ABSTRACT

**Objective:** The aim of this study is to inform surgeons regarding benign paroxysmal positional vertigo (BPPV) after indirect sinus lifting procedures and to assess its relationship with age, gender, residual alveolar bone height (RAB), and cortical thickness of the sinus floor.

**Methods:** This study included 138 patients presenting for evaluation and management of BPPV after indirect sinus lifting. Patients with RAB lengths of 5–8 mm had been taken for indirect sinus lifting. Preoperative RAB length and cortical thickness of the sinus floor had been determined by cone beam computed tomography (CBCT) in each patient. The patients diagnosed with BPPV were promptly treated by an otolaryngologist. Data were assessed by descriptive statistical methods (mean  $\pm$  standard deviation). Results were evaluated at the  $p < 0.05$  significance level, in 95% confidence interval (95% CI).

**Results:** Totally 4 out of 138 of the patients showed BPPV. There was no statistically significant difference between the mean ages and gender ratio between the patients with BPPV [BPPV(+)] and without BPPV [BPPV(-)] groups. It was found that BPPV is 2.48 times more prevalent in patients with RAB criterion values  $< 5.9$  mm than in patients with criterion values  $> 5.9$  mm. BPPV is 4.54 times more prevalent in patients with a criterion cortical thickness value  $> 0.8$  mm than in patients with a criterion value  $< 0.8$  mm.

**Conclusion:** Based on the results of this study, patients with cortical thickness values  $> 0.8$  mm should be informed before undergoing surgery, and patients exhibiting postoperative symptoms associated with vertigo should be treated promptly.

**Keywords:** Benign paroxysmal positional vertigo, maxillary sinus, osteotomy, Schneiderian membrane

## 1. INTRODUCTION

Pneumatization of the maxillary sinus occurs after tooth loss. In cases with 5–8 mm residual alveolar bone (RAB) height, indirect sinus floor elevation should be performed for prosthetic rehabilitation [1-3]. However, there are many complications associated with the closed sinus lifting procedure [4,5]. A complication that is not well known, but is not uncommon, is osteotomy-related benign paroxysmal positional vertigo (BPPV). It is a common vestibular and organ disorder characterized by short-lived recurrent episodes of vertigo associated with rapid changes in head position. BPPV is sometimes masked by postoperative complaints such as pain, swelling, and inadequate liquid consumption [6-9]. Some patients do not consider the vertigo to be related to the implant surgery, and thus, do not inform their clinicians of this symptom.

The purpose of this study is to inform patients and surgeons about vertigo after indirect sinus lifting procedures performed with osteotomes. The authors hypothesized that postoperative BPPV is related to indirect sinus lifting trauma.

As such, the aim of this study was to assess the complication of BPPV as a complication of indirect sinus lifting procedure using age, gender, RAB height, and cortical thickness of the sinus floor as predictor variables.

## 2. METHODS

### 2.1 Study Design / Sample

The study was approved by İstanbul Medipol University University Clinical Ethics Committee with the protocol number of 194140909. The study population was composed of all patients presenting for evaluation and management of BPPV after indirect sinus lifting between September 2014 and April 2015. Patients who needed dental implant therapy in one quadrant (right or left) were included in the study sample. Patients were excluded as study subjects if they had previous vertigo attacks, acute or chronic sinusitis, viral

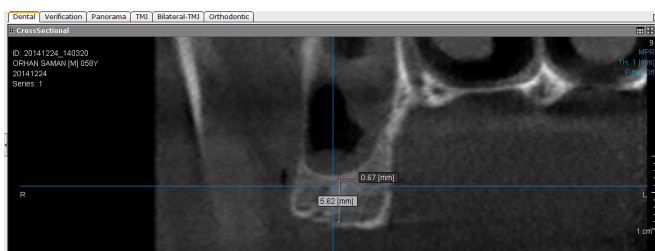
infections, or any history disease that might lead to vertigo (e.g., Ménière's disease).

## 2.2 Variables

In this cohort study, the predictor variables were age, gender, preoperative RAB height, and cortical thickness of the sinus floor determined by cone beam computed tomography (CBCT); the outcome variable was presence of postoperative BPPV. All variables were obtained from the patients' case histories.

## 2.3 Data Collection Methods

The CBCT examinations were performed using a ProMax 3D Mid machine (Planmeca Oy, Helsinki, Finland). CBCT scan assessments were performed directly on a 23" 1920x1080 pixel Acer Monitor and an HP Reconstruction PC. A Planmeca Romexis Viewer (Roselle, IL, USA) was used to measure the distance between the sinus floor membrane and the alveolar crest (RAB height) and the cortical thickness of the sinus floor. All measurements were performed by the same specialist (Figure 1).



**Figure 1.** An example of the measurement from a radiologic image

The data of the patients with BPPV included the duration times of the vertigo episodes. These patients had been referred to an otolaryngologist for diagnosis and treatment, in keeping with the department's protocols; the Dix–Hallpike test was used to diagnose BPPV. After a diagnosis of BPPV was made, the Epley maneuver was performed immediately for recovery [6].

The BPPV patients had been re-called after one week and one, three, and six months to control for recurrence. The archives were scanned for any neurovegetative symptoms associated with the autonomic nervous system, such as nausea and vomiting, and the data were recorded.

To achieve standardization, the same osteotome set (2.0, 2.5, 3.0, and 3.5 mm diameters) had been used in all of the operations. According to the literature, patients with RAB heights of 5–8 mm had been taken for indirect sinus lifting [1,2].

## 2.4 Data Analyses

Statistical analyses were performed using NCSS 2007 software (Number Cruncher Statistical System/ Kaysville, UT, USA). Data were assessed by descriptive statistical methods (mean  $\pm$  standard deviation). An independent samples t test was used for paired group comparisons, and Fisher's exact test was used for qualitative analysis. Logistic regression analysis was used as the statistical method for determining the factors affecting the presence of BPPV. Results were evaluated at the  $p < 0.05$  significance level, in 95% confidence interval (95% CI).

## 3. RESULTS

The study included 138 healthy patients (79 women and 59 men) with an average age of 47.2 years (range, 35–68 years). Four of the 138 patients (2.89%) were diagnosed with BPPV, using the Dix–Hallpike test. Severe vertigo associated with neurovegetative symptoms, such as nausea, occurred in one of the 138 patients. This patient, who was diagnosed six weeks later, was a 72-year-old female with a RAB height of 5.6 mm and a cortical thickness of 1.2 mm. This delay in the diagnosis prolonged the duration of the complication. The other three BPPV patients were diagnosed promptly with the Dix–Hallpike test and treated with the Epley repositioning maneuver by the same otolaryngologist. Three additional patients experienced dizziness the day after the operation, and BPPV two days later: a 39-year-old female with a RAB height of 5.9 mm and cortical thickness of 1 mm, a 57-year-old man with a RAB height of 5.2 mm and cortical thickness of 1 mm, and a 40-year-old female with a RAB height of 5.3 mm and cortical thickness of 1.1 mm). The second patient who had BPPV (39-year-old female) was diagnosed in the first postoperative week. The third patient (57-year-old man) presented to the clinic five days after the operation and was diagnosed promptly with BPPV. The fourth patient (40-year-old female) had not informed the clinicians of any complications at the first week, but presented at the clinic in the second week with the complication of nystagmus, which was diagnosed as BPPV. None of the 134 remaining patients experienced any neurovegetative symptoms associated with BPPV.

In the statistical analysis, the patients with BPPV were designated as BPPV(+) and the patients without BPPV were designated as BPPV(-). There was no statistically significant difference between the mean ages of the BPPV(-) and BPPV(+) groups ( $p = 0.279$ ). There was no statistically significant difference in gender ratio between the BPPV(-) and BPPV(+) groups ( $p = 0.466$ ). The average RAB value of the BPPV(+) group was found to be statistically lower than that of the BPPV(-) group ( $p = 0.019$ ). The average cortical thickness value of the BPPV(+) group was found to be statistically higher than that of the BPPV(-) group ( $p = 0.0001$ ) (Table 1).

In the logistic regression analysis, while cortical thickness was determined to be the main factor, RAB height variable lost value ( $p = 0.011$ ) (Table 2). Calculations of the areas

under the receiver operating characteristic (ROC) curve were performed for RAB and cortical thickness parameters for the diagnosis of BPPV. The area under the ROC curve was found to be 0.743 (0.662–0.814) for RAB and 0.988 (0.952–0.998) for cortical thickness. The aim of this calculation is to define which parameter is the determining factor for presence of vertigo (Table 3). The area for cortical thickness was found to be statistically higher than that of RAB height ( $p=0.022$ ), suggesting that cortical thickness is a better diagnosis parameter than RAB height for predicting BPPV (Table 4).

For the RAB parameter, the sensitivity, specificity, positive predictive value (PPV), negative predictive value (NPV), likelihood ratio (+LR), and cutoff value (criterion) were found to be 99.50, 59.70, 16.9, 99.54, 2.48, and 5.9, respectively. These results indicate that BPPV is 2.48 times more prevalent in patients with criterion values  $<5.9$  than in patients with criterion values  $>5.9$ .

For the cortical thickness parameter, the sensitivity, specificity, PPV, NPV, +LR, and criterion values were found to be 99.87, 77.97, 23.5, 99.92, 4.54, and 0.8, respectively. These results indicate that BPPV is 4.54 times more prevalent in patients with criterion values  $>0.8$  than in patients with criterion values  $<0.8$  (Table 5).

**Table 1.** Correlation of age, gender, RAB and cortical thickness parameters with BPPV (-) and BPPV (+) group

	BPPV (-) n:134		BPPV (+) n:4		p
Age	58.83±12.29		52±15.68		0.279
Gender	Man	58	43,30%	1	25.00%
	Woman	76	56.70%	3	75.00%
RAB	6.14±0.74		5.5±0.32		<b>0.019</b>
Cortical Thickness	0.56±0.2		1.08±0.1		<b>0.0001</b>

BPPV (+): patients with benign paroxysmal positional vertigo

BPPV (-): patients without benign paroxysmal positional vertigo

**Table 2.** Logistic regression analysis of RAB and cortical thickness parameters

	B	S.E.	p	Exp(B)	95% CI	
					Lower Limit	Upper Limit
RAB	-2.20	2.12	0.301	0.11	0.00	7.12
Cortical Thickness	5.69	4.16	<b>0.011</b>	72.45	17.47	113.90

**Table 3.** Area under ROC curve (AUC), standard error (SE) and 95% confidence interval of RAB and cortical thickness parameters

	AUC	SE	95% CI
RAB	0.743	0.102	0.662 – 0.814
Cortical Thickness	0.988	0.039	0.952 – 0.998

AUC: area under ROC curve

SE: standard error

CI: confidence interval

**Table 4.** Pairwise comparison of ROC curves of RAB and cortical thickness parameters

Pairwise comparison of ROC curves	p
RAB / CorticalThickness	0.022

**Table 5.** Criterion (cut off point), sensitivity, specificity, positive predictive value (PPV), negative predictive value (NPV), likelihood ratio (+LR) in the analysis

	Criterion	Sensitivity	Specificity	PPV	NPV	+LR
RAB	$<5.9$	99.50	59.70	16.9	99.54	2.48
Cortical Thickness	$>0.8$	99.87	77.97	23.5	99.92	4.54

#### 4. DISCUSSION

In the cases of increased pneumatization of the maxillary sinuses, the rehabilitation of the region is very challenging [10]. The uncommon complication of BPPV is very difficult for surgeons to describe to patients after these operations.

As such, the purpose of this study was to inform patients and surgeons about vertigo that occurs after indirect sinus lifting procedures performed with osteotomes. It was hypothesized that postoperative BPPV is related to indirect sinus lifting trauma. The aim of the study was to assess the complication of BPPV by means of age, gender, RAB height, and cortical thickness of the sinus floor. Only four patients in this retrospective study had experienced BPPV. In the statistical analysis, while cortical thickness was determined as the main factor, the RAB height variable lost value. BPPV is seen 4.54 times more often in patients with a cortical thickness criterion  $>0.8$  mm than in patients with a criterion value  $<0.8$  mm. According to the statistical analysis of the present study, if cortical bone thickness is  $>0.8$  mm, there is a risk potential for BPPV formation. In the indirect sinus lifting procedure, surgeons should apply more force to lift the sinus floor if cortical bone is dense and thick.

In cases with 5–8 mm of RAB height for indirect sinus lifting, only 0.8–1 mm of total alveolar height is formed by the cortical plate, which means that RAB thickness is mainly formed by spongy bone in indirect sinus lifting cases. Cortical bone is more resistant than spongy bone, and it accumulates and transmits more vibratory forces. On the other hand, spongy bone, which has more plastic deformation, absorbs vibratory forces [11]. The results of this retrospective study reflect those characteristics.

There are several reports of BPPV after sinus floor elevation with osteotomes [6–9, 12–14]. A previous study reported that four of 146 patients who underwent osteotome sinus floor elevation developed BPPV one or two days after the surgical procedure, which was promptly resolved with the Epley repositioning maneuver [6]. In a randomized clinical trial, it was found that three of 98 patients who underwent sinus floor elevation with osteotome and gentle tapping of a mallet developed BPPV while none of 98 patients who underwent sinus floor elevation with a screwable osteotome (without tapping with a mallet) developed BPPV. The researchers

surmised that the percussive forces of the osteotome and mallet are capable of detaching otoliths [9]. Furthermore, the patient's head position (hyperextended and tilted to one side) favors the entry of these free-floating particles into the semicircular canal [12]. Our results regarding BPPV complication triggered by closed sinus floor elevation procedure (2.89%) were similar to case series evaluations that reported percentages of 2.43% (6) and 3.06% (9). All patients presenting with BPPV in our sample were treated with the Epley repositioning maneuver, which has proven to be very effective in treating the disorder [15,16].

According to the previous studies, the factors that act simultaneously in triggering positional vertigo following this surgical procedure are the percussive forces exerted on the upper maxilla by the osteotomes, the vibratory forced exerted by the implant drill, and the hyperextended head position [6,8,17,18]. In our clinic, all operations involving the maxilla are performed while the patients' heads are hyperextended. For this reason, we think one of the reasons we encountered vertigo is the positioning of the head during the operation. The other factor that provokes BPPV is the percussive forces, which are capable of detaching the otoliths. When performing dental implants, both the osteotomes tapped on with mallets and drilling procedures might create percussive forces.

There is only knowledge about the incidence of idiopathic BPPV in patients 50–70 years of age, although the condition is found in all age groups. The incidence of idiopathic BPPV ranges from 11 to 64 per 100,000 per year [19], and it increases by approximately 38% per decade of life [16]. BPPV was not found to be related to age in the present study.

In the literature, vertigo after closed sinus floor elevation with osteotomes is seen more often in women than in men (1:1.5) [16]. In some studies, sex distribution is nearly equal for post-traumatic and post-vestibular neuritis [20,21]. In our study, there was no statistical difference between genders. Our findings showed that cortical thickness seems to be a better diagnosis parameter than RAB height for predicting BPPV. The posterior maxillary alveolar ridge consists of mostly spongy bone, and it can deform easily while absorbing the osteotomy strokes. On the other hand, a thick cortical sinus floor transmits most of the osteotomy forces to the posterior semicircular canal via cranial buttresses, thus inducing BPPV. Many studies have shown the relationship between BPPV and closed sinus lifting procedure but there is no study showing a relationship between the presence of vertigo and cortical thickness of the sinus floor [6,7,8,9]. The authors in the present study state that the findings should help the clinicians determine about possible complications which may occur postoperatively.

Studies regarding this complication have been performed mainly by otolaryngologists. In the present study, the authors are mainly oral and maxillofacial surgeons who had performed the surgical operations and estimated this complication. In addition, the presence of BPPV was assessed by means of the parameters of age, gender, RAB height, and

cortical bone thickness, which is unique in the literature. However, there were only four cases of BPPV in the present study; therefore, more case follow-ups are needed in order to obtain dependable statistical data. Other factors that require attention in order to produce more accurate results are cortical bone density, which varies among patients, and determination of the forces exerted by the osteotomes used in these procedures.

## 5. CONCLUSION

Our results indicate that although BPPV has been considered to be a rare complication following indirect sinus lift procedures, it is highly disruptive to patients if not diagnosed correctly and treated properly. The phenomenon of BPPV was found to be mainly associated with the parameter of preoperative cortical thickness value. We suggest that in particular, patients with cortical thickness values  $>0.8$  mm should be informed before undergoing surgery and referred to otolaryngologists when faced with any neurovegetative symptom associated with vertigo. We also recommend that implant surgeons add this complication to their informed consent forms for sinus lifting procedures.

In future studies, we recommend testing a broader sample and including the operation duration, cortical bone density, number of osteotomy strokes, measurement of stroke force for each blow, and force variances among different sized implants to evaluate other possible factors that may cause BPPV.

## REFERENCES

- [1] Peleg M, Garg AK, Misch CM, Mazor Z. Maxillary sinus and ridge augmentations using a surface-derived autogenous bone graft. *J Oral Maxillofac Surg* 2014; 62(12):1535-1544.
- [2] Pal US, Sharma NK, Singh RK, et al. Direct vs. indirect sinus lift procedure: A comparison. *Natl J Maxillofac Surg* 2012; 3(1):31-37.
- [3] Sforza NM, Marzadori M, Zucchelli G. Simplified osteotome sinus augmentation technique with simultaneous implant placement: a clinical study. *International J Periodontics & Restorative Dent* 2008; 28(3):291-299.
- [4] Alkan A, Celebi N, Bas B. Acute maxillary sinusitis associated with internal sinus lifting: report of a case. *Eur J Dent* 2008; 2(1):69-72.
- [5] Becker ST, Terheyden H, Steinriede A, Behrens E, Springer I, Wiltfang J. Prospective observation of 41 perforations of the Schneiderian membrane during sinus floor elevation. *Clin Oral Implants Res* 2008; 19(12):1285-1289.
- [6] Di Girolamo M, Napolitano B, Arullani CA, Bruno E, Di Girolamo S. Paroxysmal positional vertigo as a complication of osteotome sinus floor elevation. *Eur Arch Otorhinolaryngol* 2005; 262(8):631-633.
- [7] Penarrocha M, Garcia A. Benign paroxysmal positional vertigo as a complication of interventions with osteotome and mallet. *J Oral Maxillofac Surg* 2006; 64(8):1324.

- [8] Saker M, Ogle O. Benign paroxysmal positional vertigo subsequent to sinus lift via closed technique. *J Oral Maxillofac Surg* 2005; 63(9):1385-1357.
- [9] Sammartino G, Mariniello M, Scaravilli MS. Benign paroxysmal positional vertigo following closed sinus floor elevation procedure: mallet osteotomes vs. screwable osteotomes. A triple blind randomized controlled trial. *Clin Oral Implants Res* 2011; 22(6):669-672.
- [10] Balaji SM. Direct v/s Indirect sinus lift in maxillary dental implants. *Ann Maxillofac Surg* 2013; 3(2):148-153.
- [11] Yan X, Zhang X, Chi W, Ai H, Wu L. Comparing the influence of crestal cortical bone and sinus floor cortical bone in posterior maxilla bi-cortical dental implantation: a three-dimensional finite element analysis. *Acta Odontologica Scandinavica* 2015; 73(4):312-320.
- [12] Vernamonte S, Mauro V, Vernamonte S, Messina AM. An unusual complication of osteotome sinus floor elevation: benign paroxysmal positional vertigo. *Int J Oral Maxillofac Surg* 2011; 40(2):216-218
- [13] Kim MS, Lee JK, Chang BS, Um HS. Benign paroxysmal positional vertigo as a complication of sinus floor elevation. *J Periodontal & Implant Sci* 2010; 40(2):86-89.
- [14] Su GN, Tai PW, Su PT, Chien HH. Protracted benign paroxysmal positional vertigo following osteotome sinus floor elevation: a case report. *Int J Oral Maxillofac Implants* 2008; 23(5):955-999.
- [15] Bruintjes TD, Companjen J, van der Zaag-Loonen HJ, van Benthem PP. A randomised sham-controlled trial to assess the long-term effect of the Epley manoeuvre for treatment of posterior canal benign paroxysmal positional vertigo. *Clin Otolaryngol* 2014; 39(1):39-44.
- [16] Hilton MP, Pinder DK. The Epley (canalith repositioning) manoeuvre for benign paroxysmal positional vertigo. *Cochrane Database Syst Rev* 2014; 12:CD003162.
- [17] Pjetursson BE, Ignjatovic D, Matuliene G, Bragger U, Schmidlin K, Lang NP. Transalveolar maxillary sinus floor elevation using osteotomes with or without grafting material. Part II: Radiographic tissue remodeling. *Clin Oral Implants Res* 2009; 20(7):677-683.
- [18] Penarrocha M, Perez H, Garcia A, Guarinos J. Benign paroxysmal positional vertigo as a complication of osteotome expansion of the maxillary alveolar ridge. *J Oral Maxillofac Surg* 2001; 59(1):106-107.
- [19] Froehling DA, Silverstein MD, Mohr DN, Beatty CW, Offord KP, Ballard DJ. Benign positional vertigo: incidence and prognosis in a population-based study in Olmsted County, Minnesota. *Mayo Clin Proc* 1991; 66(6):596-601.
- [20] Baloh RW, Honrubia V, Jacobson K. Benign positional vertigo: clinical and oculographic features in 240 cases. *Neurology* 1987; 37(3):371-378.
- [21] Katsarkas A, Kirkham TH. Paroxysmal positional vertigo—a study of 255 cases. *J Otolaryngol* 1978; 7(4):320-330.

**How to cite this article:** Atalı O, Dergin G, Sarı M. Is There a Correlation Between Benign Paroxysmal Positional Vertigo and Indirect Sinus Lifting?. *Clin Exp Health Sci* 2022; 12: 102-106. DOI: 10.33808/clinexphealthsci.827104