



OLGU SUNUMU / CASE REPORT

Two distinct case reports with foamy cell and differential diagnosis: Xanthomatous meningioma and review of literature

Köpüksü hücreli iki farklı olgu sunumu ve ayırıcı tanı: Ksantomatöz menenjiom ve literatürün gözden geçirilmesi

İsmail Saygın¹, Emel Çakır¹, İlker Eyüpoğlu²

¹Karadeniz Teknik Üniversitesi Tıp Fakültesi, Tıbbi Patoloji Anabilim Dalı, ²Radyoloji Anabilim Dalı, Trabzon, Turkey

Cukurova Medical Journal 2021;46(2):834-839

Abstract

Meningiomas are the most common primary intracranial tumor thought to derived from arachnoidal cap cells in the meningeal coverings of the spinal cord and brain. The current WHO classification, published in 2016, includes nine different subtypes of grade 1 meningiomas, three different subtypes of grade 2 meningiomas, and three different subtypes of grade 3 meningiomas. Metaplastic meningioma is a rare variant which shows focal or diffuse mesenchymal tissue component. Xanthomatous meningioma which has foamy cell changes is a quite rare variant of metaplastic meningioma. Two patients, 54 and 59 years old, who applied to our clinic with similar symptoms, were operated for meningioma. Histopathological examination of their biopsy showed that neoplastic cells had oval-round nuclei and eosinophilic cytoplasm. In xanthomatous meningioma, some neoplastic cells had clear vacuolated cytoplasm (foamy cells). In microscopic examination of resection material in one of these patients, cells in some areas of the tumor had clear vacuolated cytoplasm (foamy cells). These neoplastic cells were scattered among other meningotheial cells and they were positive for EMA. To the best of our knowledge, until today there have been only 14 reported xanthomatous meningioma cases in English literature. Here, we aimed to discuss the pathogenesis and differential diagnosis of xanthomatous meningioma in two different cases.

Keywords: Foamy cell, xanthomatous, metaplastic, histiocytic, meningioma

Öz

Meningiömlar, omurilik ve beyin meningeal kılıflarındaki araknoidal kap hücrelerinden türediđi düşünölen en yaygın primer intrakranyal tümördür. 2016 yılında yayınlanan son WHO sınıflaması, dokuz farklı evre I menenjiom alt tipi, üç farklı evre II menenjiom alt tipi ve üç farklı evre III menenjiom alt tipi içermektedir. Metaplastik menenjioma, fokal veya diffüz mezenkimal doku bileşeni içeren nadir bir varyanttır. Köpüksü hücre deđişiklikleri içeren ksantomatöz menenjiom ise oldukça nadir görölen bir metaplastik menenjiom varyantıdır. Kliniđimize benzer şikayetlerle gelen 54 ve 59 yaşlarında iki hasta menenjiom tanısıyla opere edildi. Biyopsilerinin histopatolojik incelemesinde oval-yuvarlak nükleuslu ve eozinofilik sitoplazmalı hücrelerden oluşun neoplazm göröldü. Bu hastalardan birinin rezeksiyon materyalinin mikroskopik incelemesinde, tümörün bazı bölgelerindeki hücreler berrak vakuollü sitoplazmaya (köpüksü hücreler) sahipti. Köpüksü görünüme sahip bu neoplastik hücreler diđer menenjiotelyal hücreler arasında dađılmıştı ve EMA ile pozitif reaksiyon verdi. Bildiđimiz kadarıyla, bugüne kadar literatürde sadece 14 ksantomatöz menenjiom vakası bildirilmiştir. Burada ksantomatöz menenjiomun patogenezi ve ayırıcı tanısını iki farklı vakada tartışmayı amaçladık.

Anahtar kelimeler: Köpüksü hücre, ksantomatoz, metaplastik, histiositik, menenjiom

Yazışma Adresi/Address for Correspondence: Dr. İsmail Saygın, Karadeniz Teknik Üniversitesi Tıp Fakültesi, Tıbbi Patoloji Anabilim Dalı, Trabzon, Turkey E- mail: ismailsaygin@ktu.edu.tr

Geliş tarihi/Received: 14.12.2020 Kabul tarihi/Accepted: 13.04.2021 Çevrimiçi yayın/Published online: 20.05.2021

INTRODUCTION

Meningiomas are the most frequent primary tumors of the central nervous system (CNS) which are thought to derive from arachnoid cap cells located on the surface of the arachnoid membrane¹. Although they are mostly seen intracranial, intraspinal and orbital locations can also be observed. In the intracranial region, meningiomas are often seen on

the cerebral convexities, parasagittal areas, and olfactor grooves. Spinal meningiomas frequently seen in the thoracic region. The incidence of meningiomas increase with age, especially after age 65, affecting women more than men. There are 15 different variants of meningiomas according to the World Health Organization (WHO) classification of CNS tumors (Table 1).

Table 1. WHO classification of meningiomas.

WHO grade I	WHO grade II	WHO grade III
Meningothelial	Chordoid	Papillary
Fibrous	Clear cell	Rhabdoid
Transitional	Atypical	Anaplastic (malignant)
Psammomatous		
Angiomatous		
Microcystic		
Secretory		
Lymphoplasmacyte-rich		
Metaplastic		

The most common histomorphological subtypes are meningothelial, fibrous, and transitional meningiomas. Xanthomatous meningiomas, listed under the metaplastic meningioma category, are quite rare and to the best of our knowledge, this is the 15th case report in the current literature. Metaplastic meningioma is an unusual variant that contains focal or diffuse mesenchymal tissue component¹. Mesenchymal component is characterized by single or combined presence of mesenchymal tissue such as osseous, cartilaginous, myxoid, xanthomatous (histiocytic) or lipomatous tissues. Metaplastic meningioma showing xanthomatous changes is a very confusing subtype.

It is important to distinguish xanthomatous meningioma from other lesions included in the differential diagnosis. The most important of these lesions is grade 2 clear cell meningioma. Due to the possibility of recurrence in grade 2 tumors, follow-up is important and there are differences in their treatment. In addition, the mechanism of xanthomatous changes is discussed with the two cases presented here. The distinction between true histiocytic cells and xanthomatous metaplasia in meningioma is one of the important discussion topics in this type of meningioma in the literature. Here, we aimed to discuss the pathogenesis and differential diagnosis of xanthomatous meningioma in two different cases.

CASES

Case 1

A 59-year-old male patient had a history of seizures. Due to the clinical history, the patient was operated 11 years ago for an intracranial mass in the frontal region at the external hospital. Postoperative radiotherapy was applied. Second operation was performed 4 years ago in our hospital due to recurrence of the mass. At his last apply, the patient had no complaints.

Macroscopically, there was a 3x2,5 cm solid tumor and no necrosis-hemorrhage. MR findings of the patient are given in Figure 1A. Histopathological examination showed that neoplastic cells were oval-round shaped nuclei and eosinophilic cytoplasm. The whorl formation was scattered (Figure 2A-B). Some neoplastic cells had clear vacuolated cytoplasm and centrally located bland round nuclei (foamy cells). This foamy cells were scattered among other meningothelial cells (Figure 2C-D). There was no necrosis or mitosis. Immunohistochemical studies were performed with the Ventana automated system. Meningothelial cells were positive for EMA (Epithelial Membrane Antigen), SSTR2 (Somatostatin Receptor 2), PR (Progesterone receptor), and vimentin. Ki 67 proliferation index was 3%. The foamy cells were also positive for EMA

(Figure 3A-B), CD 68, CD 163, Adipophilin, Lysozyme (Figure 3C-F) and negative for S 100.

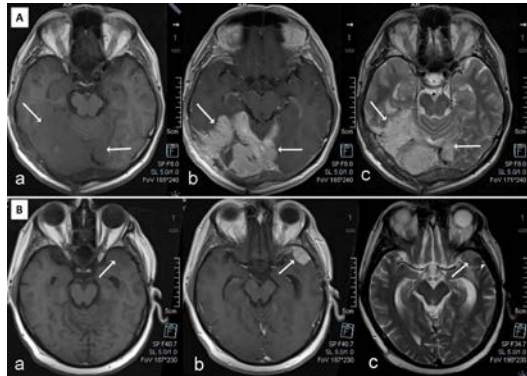


Figure 1. A: Axial T1-weighted MR image of Case 1

(a) demonstrates a large extra-axial mass that is isointense to grey matter and is located within the right temporo-occipital convexity. Lesion shows heterogeneous enhancement on post-contrast axial T1-weighted MR image (b) and is slightly hyperintense to grey matter on T2-weighted MR image (c).

Figure 1 B: Axial T1-weighted MR image of Case 2

(a) shows an extra-axial mass that is isointense to grey matter and is located within the left temporal convexity. Lesion demonstrates a homogeneously enhancing with a broad dural attachment (b). Axial T2-weighted MR image (c) reveals a focal hemorrhage (arrowhead) within the mass.

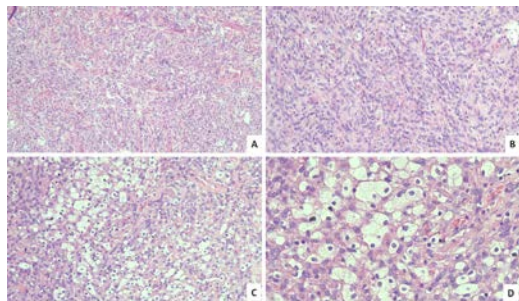


Figure 2. Histopathological examination of Case 1

A: HE x 100 : Neoplastic cells are arranged in fascicular structure and sparse whorl formation B: HE x 200 : Neoplastic cells have oval-round shaped nuclei and eosinophilic cytoplasm C: HE x 200 : Some neoplastic cells have clear vacuolated cytoplasm and centrally located bland round nuclei (foamy cells). D: HE x 400 : Foamy cells are scattered among other meningothelial cells.

Case 2

A 54-year-old male patient applied to our hospital with a history of seizure and headache. The patient was operated for meningioma about 7 years ago. At his last apply, the patient had no complaints. Macroscopically, there was a 6x4 cm solid tumor, no

necrosis but hemorrhage. MR findings of the patient are given in Figure 1B.

Histopathological examination was same with the first case. Unlike the first case some areas included hemorrhage. In some areas there were also foamy cells between neoplastic islands (Figure 4A). Neoplastic islands and foamy cells were separated by a sharp margin (Figure 4B). There was no necrosis or mitosis. Brain and bone invasion were also seen. Unlike the first case, immunohistochemical studies showed that although meningothelial cells were positive, foamy cells were negative for EMA (Figure 4C-D).

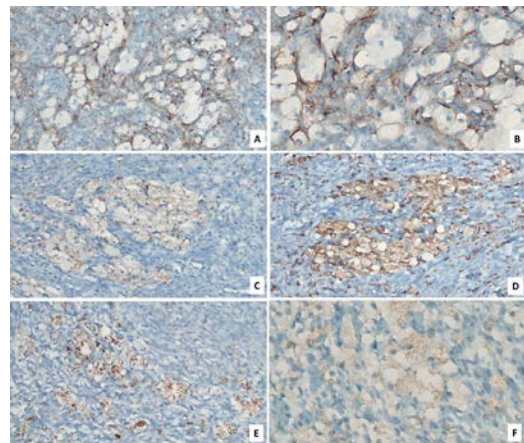


Figure 3. Immunohistochemical findings of Case 1

A: EMA X 200 B: EMA X 400 C: CD 68 X 200 D: CD 163 X 200 E: Adipophilin X 200 F: Lysozyme X 200.

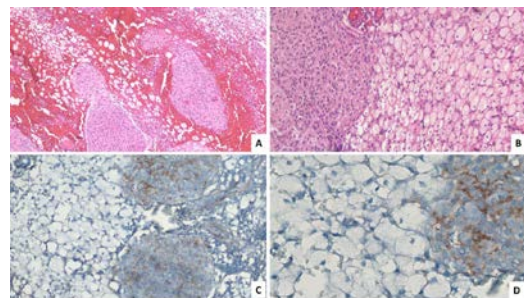


Figure 4. Histopathological examination of Case 2

A: HE x 100: Some hemorrhagic areas, foamy cells between neoplastic islands. B: HE x 200: Neoplastic islands and foamy cells are separated by a sharp boundary C: EMA x 200: Meningothelial cells are positive for EMA, foamy cells are negative for EMA. D: EMA x 400 : Meningothelial cells are positive for EMA, foamy cells are negative for EMA.

DISCUSSION

Xanthomatous meningioma was first described in 1981 by Yamashita J. et al.². They have distinguished two different cellular components as meningothelial and foamy cells in histochemical (Sudan black stain) study. Since that time, xanthomatous features have been reported in a total of 14 cases in English literature (Table 2).

The biological origin of foamy cells is not clear. There are two major hypotheses on the development of

foamy cells in the literature. The first one is that the foamy cells represent a metaplastic change. Immunohistochemical studies shows that these foamy cells express EMA and have same ultrastructural features similar to the meningothelial cells³. According to this hypothesis, the histiocytic changes are secondary to the metabolic abnormality of the neoplastic meningothelial cells, which results in cellular degeneration. Trauma may be another causative factor for the foamy changes⁴.

Table 2. The list of xanthomatous meningiomas reported in English literature.

Case	Author and Reference no	Age	Sex	Location	Diameter (cm)	Immunohistochemistry and histochemistry	Year
1	Yamashita J. et al. ²	51	M	Frontal	-	Sudan black stain	1981
2	Fujii Y. et al. ⁸	74	F	Frontal	-	-	1988
3	Machara T. et al. ⁹	48	F	Temporal	4	-	1990
4	Katayama Y. et al. ¹⁰	37	F	Frontal	-	-	1993
5	Kepes J.J. et al. ³	-	-	-	-	HAM-56, Vimentin	1994
6	Germano A. et al. ¹¹	2	F	Posterior fossa	-	-	1997
7	Ijiri R. et al. ¹²	8	M	Frontal	2	CD 68, HAM-56, Vimentin, GFAP, EMA, CAM 5.2, p53, Ki 67, MIB 1	2000
8	Uematsu Y. et al. ¹³	infant		-	-	Vimentin, CD 68, EMA, CD1a, Ki 67	2002
9	Sato S. et al. ¹⁴	57	M	Occipital	-	-	2003
10	Ikota H. et al. ⁶	61	F	Occipital-parietal	7	EMA, Vimentin, CD68, Ki-M1p, MAC387, Lysozyme, Alpha 1-antitrypsin, Alpha 1-antichymotrypsin	2008
11	Ishida M. et al. ⁷	76	M	Parasagittal-frontal	-	EMA, Vimentin, CD68, MAC387, Lysozyme, Adipophilin, Ki-67	2013
12	Liu L. et al. ⁴	55	F	frontoparietal	4	EMA, CD4, CD68, S-100, Ki-67	2014
13	Chougule M. et al. ¹⁵	24	F	Temporoparieto-occipital	7.2	PAS, EMA, Ki-67	2015
14	Ersöz S. et al. ¹⁶	32	M	Frontal	7.4	EMA, Adipophilin, CD68, progesterone, CEA, Vimentin, GFAP, S-100, Ki-67	2017
15	Present case (case 1 in this paper)	59	M	Frontal		EMA, Vimentin, CD68, SSTR2, Lysozyme, Adipophilin, Ki-67, Progesterone, CD 163, Adipophilin, S 100	2018

The second hypothesis is that the foamy cells originate from monocytic lineage. In "A dura-based

xanthogranuloma" case of Husain S. et al., the histiocytes expressed monocytic/histiocytic

biomarkers CD68 and S100, but not meningotheial biomarker EMA⁵. Further more in some cases, some of the foamy cells expressed EMA, while some of them were only positive for the histiocytic biomarkers. Ikota H. and Nakazato Y. reported that xanthomatous tumor cells were positive with EMA, vimentin, fatty acid synthase and histiocytic markers. They also pointed out the presence of patchy accumulation of macrophages which were EMA negative. Thus, they concluded that xanthomatous tumor cells and foamy macrophages coexist in the same lesion⁶.

In our first case, the foamy cells and meningotheial cells are both positive for EMA which supporting meningotheial origin of the neoplastic cells. In the second case, meningotheial cells are positive for EMA while foamy cells are negative. Also both cell types are positive for CD68 and CD163 which support the histiocytic differentiation. But meningotheial cells show focal and low positivity for CD68 and CD163. On the other hand, only foamy cells are positive for lysozyme that supports histiocytic differentiation. Therefore, the diagnosis of the first case is xanthomatous changes or xanthomatous meningioma while the diagnosis of the second case is foamy macrophages accumulation.

Adipophilin expression in xanthomatous meningioma was first shown by Ishida et al. in both xanthomatous and classical areas⁷. In our cases, only foamy cells showed positivity for Adipophilin but negative for S-100.

Differential diagnosis of xanthomatous meningioma mainly comprises lipomatous meningioma, clear cell meningioma, microcystic meningioma, hemangioblastoma and other intracranial histiocytic disorders such as xanthoma and Rosai-Dorfman disease (RDD)¹.

Lipomatous meningioma is characterized by the presence of adipose tissue. These adipocytic cells stains with S-100. In our case, xanthomatous areas were S-100 negative. Clear cell meningioma which is mostly diagnosed during childhood does not contain classical meningioma areas and tends to be localized in the cauda equina and cerebellopontine angle. Clear cell areas have abundant cytoplasmic glycogen and are periodic acid schiff (PAS) positive, diastase resistance PAS negative. Microcystic meningiomas are characterized by a lacey and vacuolated appearance due to both clear cytoplasm and extracellular fluid filled spaces. The neoplastic cells

are reactive for EMA but not for CD68. Hemangioblastomas are composed of vascular and stromal components. Stromal cells of hemangioblastoma express inhibin and brachyury. EMA is not expressed in hemangioblastomas. RDD is characterized by a polymorphic infiltration of histiocytes, lymphocytes and plasma cells. Emperipolesis is the hallmark sign. The histiocytes in RDD only express histiocytic biomarkers, but not epithelial markers.

In conclusion the xanthomatous changes that can be seen in meningiomas are quite rare. It is important to differentiate xanthomatous change occurring in a meningioma from the macrophages indicating inflammatory reaction. True identification of xanthomatous changes is also very important to distinguish from other metaplastic changes or neoplastic conditions such as clear cell meningioma and metastasis. Neoplastic meningotheial cells exhibit xanthomatous changes as a result of undetermined metabolic abnormalities, trauma or monocytic lineage origin. Each new case will contribute to understand the pathogenesis of xanthomatous changes. For this reason, we found it worth while to present two cases of meningiomas with foamy cells.

Yazar Katkıları: Çalışma konsepti/Tasarımı: İS; Veri toplama: -; Veri analizi ve yorumlama: İS, EÇ; Yazı taslağı: İS; İçerigin eleştirel incelenmesi: EÇ, İE; Son onay ve sorumluluk: İS, EÇ, İE; Teknik ve malzeme desteği: -; Süpervizyon: EÇ; Fon sağlama (mevcut ise): yok.

Etik Onay: Bu çalışma olgu sunumu olması nedeniyle etik onay gerekmemektedir. Bu olgu sunumu için hastalardan bilgilendirilmiş onam alınmıştır.

Hakem Değerlendirmesi: Dış bağımsız.

Çıkar Çatışması: Yazarlar çıkar çatışması beyan etmemişlerdir.

Finansal Destek: Yazarların finansal destek beyan etmemişlerdir.

Yazarın Notu: Detaylarının ve figürlerinin yayınlanması için bize yazılı onay veren hastalara minnettanız.

Author Contributions: Concept/Design : İS; Data acquisition: -; Data analysis and interpretation: İS, EÇ; Drafting manuscript: İS; Critical revision of manuscript: EÇ, İE; Final approval and accountability: İS, EÇ, İE; Technical or material support: -; Supervision: EÇ; Securing funding (if available): n/a.

Ethical Approval: Ethical approval is not required since this study is a case report. Informed consent has been received from the patients for this case report.

Peer-review: Externally peer-reviewed.

Conflict of Interest: Authors declared no conflict of interest.

Financial Disclosure: Authors declared no financial support

Acknowledgement: We are very grateful to the patients who gave us written consent for publication of his details and figures.

REFERENCES

1. Louis DN, Ohgaki H, Wiestler OD, Cavenee WK, Ellison DW, Figarella-Branger D et al.. WHO Classification of Tumours of the Central Nervous System. (IARC WHO Classification of Tumours) Revised 4th Edition. Geneva, WHO, 2016.

2. Yamashita J, Handa H, Morimoto M, Oda Y, Nakashima Y. Xanthomatous meningioma. *J Comput Assist Tomogr.* 1981;5:272-3.
3. Kepes JJ. Lipidized meningotheial tumor cells in "xanthomatous" meningioma express macrophage antigen. *J Neuropathol Exp Neurol.* 1994;53:384-8.
4. Liu L, Stone J, Hoffpauir JT, Xiong .: Histiocytic meningioma: A distinctive subtype of meningioma? *Intractable Rare Dis Res.* 2014;3:57-9.
5. Husain S, Alkhalidi HM, Raddaoui E. A 38-year-old woman with a dural based lesion. *Brain Pathol.* 2012;22:433-7.
6. Ikota H, Nakazato Y. A case of metaplastic meningioma with extensive xanthomatous change. *Neuropathol.* 2008;28:422-6.
7. Ishida M, Fukami T, Nitta N, Iwai M, Yoshida K, Kagotani A et al. Xanthomatous meningioma: A case report with review of the literature. *Int J Clin Exp Pathol.* 2013;6:2242-6.
8. Fujii Y, Toyama M, Watanabe M, Taniguchi Y, Kaneko H. A case of a hypodense meningioma. *CT Kenkyu.* 1988;10:337-42.
9. Machara T, Katsumata Y, Noda M, Shirouzu I. Low-density meningioma on CT. *Am J Neuroradiol.* 1990;11:1265.
10. Katayama Y, Tsubokawa T, Tanaka A, Koshinaga M, Nemoto N. Magnetic resonance imaging of xanthomatous meningioma. *Neuroradiol.* 1993;35:187-9.
11. Germano A, Galatioto S, La Rosa G, Caffo M, Cardia E. Xanthomatous posterior pyramid meningioma in a 2-year-old girl. *Childs Nerv Syst.* 1997;13:406-11.
12. Ijiri R, Tanaka Y, Hara M, Sekido K. Radiation-associated xanthomatous meningioma in a child. *Childs Nerv Syst.* 2000;16:304-8.
13. Uematsu Y, Takayama M, Oiwa Y, Itakura T. A case report and review of xanthomatous meningioma. *Progress in Oncology.* 2002;12:31-6.
14. Sato S, Nabeshima K, Ohno A, Hinoura Y, Yokogami K, Miyahara D. A case of xanthomatous meningioma-Usefulness of cytologic preparations in intraoperative diagnosis. *J Jpn Soc Clin Cytol.* 2003;42:107-11.
15. Chougule M, Pawar V, Chivate SD, Sunil VJ. Xanthomatous meningioma: a rare case report. *Int J Health Sci Res.* 2015;5:445-8.
16. Ersoz S, Sagnak YZ, Eyuboglu I, Yazar U. Xanthomatous meningioma: a case report. *Turk Neurosurg.* 2019;29:141-4.