

# Pleomorphic Adenoma: Report of Two Cases with an Unusual Presentation

Muruvvet Akcay Celik<sup>1</sup>

<sup>1</sup>Department of Pathology, Faculty of Medicine, Ordu University, Ordu, Turkey

Copyright@Author(s) - Available online at <https://dergipark.org.tr/en/pub/mbsjohs>  
Content of this journal is licensed under a Creative Commons Attribution-NonCommercial 4.0 International License,



Received: 23 December 2020, Accepted: 31 March 2021, Published online: 30 April 2021  
© Ordu University Institute of Health Sciences, Turkey, 2021

## Abstract

Pleomorphic adenoma is the most common salivary gland tumor. Pleomorphic adenoma is also known as benign mixed tumor. Most commonly affected site is the parotid gland. It may also occur in other major salivary glands (submandibular and sublingual glands), lacrimal glands and minor salivary glands. Pleomorphic adenoma arises as a painless, firm swelling, slowly growing in the oral cavity. Pleomorphic adenoma is a benign triphasic salivary gland tumor that occurs in epithelial, myoepithelial, and chondromyxoid stroma. Complete surgical resection with negative margins is the main treatment method in pleomorphic adenoma, insufficient resection for treatment causes local recurrence. It is an entity that should be considered in oral cavity lesions. Here, cases of pleomorphic adenoma with maxillary localization are mentioned.

**Keywords:** pleomorphic adenoma, salivary gland tumor, oral cavity

**Suggested Citation:** Akcay Celik M. Pleomorphic adenoma: report of two cases with an unusual presentation..Mid Blac Sea Journal of Health Sci, 2021; 7(1):147-149.

---

## Address for correspondence/reprints:

Muruvvet Akcay Celik

**Telephone number:** +90 (505) 561 3601

**E-mail:** drmakcaycelik@gmail.com

### Introduction

Pleomorphic adenoma (PA), also known as a benign mixed tumor, is the most common salivary gland tumor in both children and adults. It is most frequent in women in the fourth decade of life, but it can be seen in patients of all ages and genders. Benign triphasic salivary gland neoplasm is composed of epithelial cells, myoepithelial cells and chondromyxoid stroma (1). Most commonly affected site of pleomorphic adenoma (PA) is the parotid gland. It may also occur in other major salivary glands (submandibular and sublingual glands), lacrimal glands and minor salivary glands.

Clinically, they are observed as a slow growing, painless, well circumscribed mass that involves the salivary gland. Radiological findings may be useful in clinical diagnosis (1). Definitive diagnosis is made histopathologically.

Here, cases of PA with maxillary localization, where is a rarely reported region, are presented.

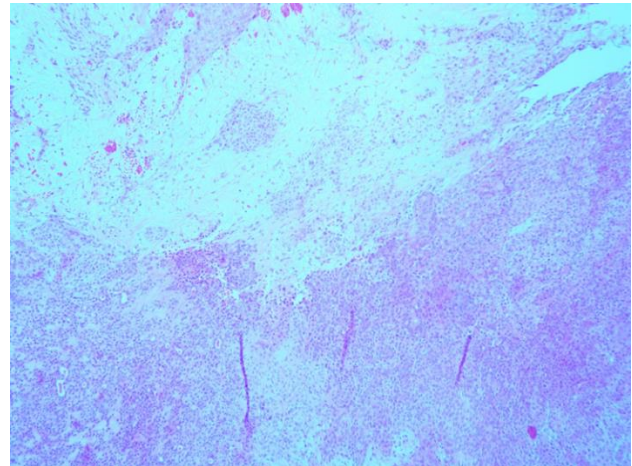
#### Case 1

In the examination of a 56-year-old female patient who applied to the dental clinic, a solid mass of 3 cm in diameter was detected in the right maxillary premolar region. The lesion was observed close to the buccal mucosa, with the appearance of expanding in the vestibular sulcus. The lesion that could not be clearly evaluated radiographically was considered as a lipoma and an excisional biopsy was taken.

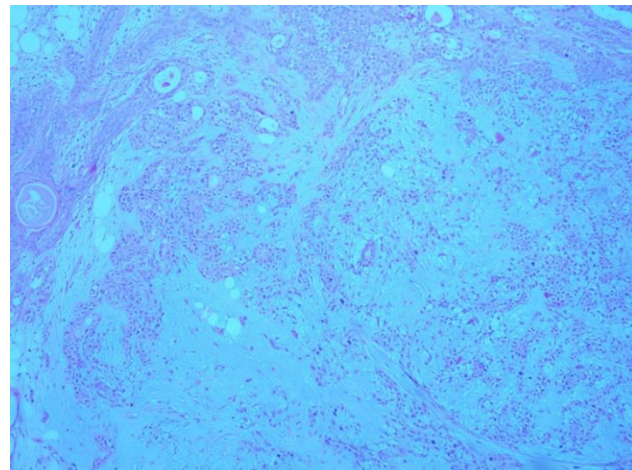
#### Case 2

In the examination of a 74-year-old female patient who applied to the dental clinic, a solid mass of 2,5 cm in diameter was detected in the foramen pallatinum in the right posterior maxilla. The mass was observed as elevated from the surface and caused bone resorption radiologically. An excisional biopsy was taken considering peripheral giant cell granuloma.

Histopathologic findings of the two cases were similar. In the microscopic examination of both cases, epithelial and mesenchymal cells were observed in the chondromyxoid stroma. Therefore both cases were diagnosed as PA in our pathology department (Figure 1-2).



**Figure 1.** PA (Case 1), HEX100, on the lower side cellular area is seen, on the upper side chondroid stroma is seen.



**Figure 2.** PA (Case 2), HEX100, chondromyxoid stroma is seen.

### Discussion

Pleomorphic adenoma is the most common neoplasm of the large salivary glands and mostly affects the parotid gland, less often the accessory salivary glands. It takes its name from the architectural pleomorphism seen under the light microscope (2).

The palate corresponding to the small glands is the most common site for a mixed tumor.

Another area frequently affected by this tumor is the lips. A small minority of tumors are also found in the oral cavity, neck and nasal cavity (3). Both of our cases were located in the maxillary region. Clinically, it is seen as a slow-growing, painless, well-circumscribed mass that involves the salivary gland.

The most important feature of a pleomorphic adenoma of the minor salivary glands is the absence of a capsule, if present is only very thin (4). The differential diagnosis of PA includes palatal abscess,

odontogenic and nonodontogenic cysts, soft tissue tumors and salivary gland tumors (5).

Approximately 6% of these tumors turn into carcinoma ex pleomorphic adenoma (6).

In our two cases, PA was not considered clinically, and radiological findings did not help.

Diagnosis was made histopathologically in our pathology department. Thus, both cases were diagnosed as PA with light microscope examination.

Complete surgical resection with negative margins is the main treatment method in PA. An incisional biopsy must be performed first to determine the proper treatment approach. Insufficient resection for treatment causes local recurrence. Radiation therapy may be considered in symptomatic recurrent PA cases not suitable for surgical treatment (7).

For patient with gross residual disease, close or positive margins, multifocal recurrence, or with perineural invasion, postoperative radiotherapy can provide long-term local control (8).

Surgical margins in both cases were evaluated as intact. In patients diagnosed with PA, long-term follow-up should be performed after surgical treatment due to risk of recurrence and malignant transformation (9).

### Conclusion

PA should be considered in oral cavity lesions. Radiology may be useful in clinical diagnosis but definitive diagnosis can be rendered on preoperative cytology or biopsy. Definitive diagnosis is made histopathologically. It is very important to know the histopathological features and locations of PAS for correct diagnosis. Correct diagnosis of PA is very helpful to direct its treatment. The main treatment method in PA is complete surgical resection with negative margins.

---

### *Patient Approval*

*Approval was received for this study from the patient.*

**Peer-review:** Externally peer-reviewed.

**Author Contributions:** *Concept, Design, Literature search, Data Collection and Processing, Analysis or Interpretation, Writing:* M.A.C.

**Conflict of Interest:** No conflict of interest was declared by the author.

**Financial Disclosure:** The author declared that this study hasn't received no financial support.

---

### References

1. Sharma Y, Maria A, Chhabria A: Pleomorphic adenoma of the palate. *Natl J Maxillofac Surg.* 2011; 2:169-171.
2. Byakodi S, Charanthimath S, Hiremath S, Kashalikar JJ. Pleomorphic adenoma of palate: a case report. *Int J Dent Case Rep.* 2011;1:36–40.
3. Shrestha A, Reddy NS, Ganguly SN. Pleomorphic adenoma of the upper lip: a case report. *J Coll Med Sci (Nepal).*2010;6:51–53
4. De Paula Vernetta C, Garcia Callejo FJ, Ramirez Sabio JB, Orts Alborch MH, Morant Ventura A, Marco Algarra J. Giant pleomorphic adenoma of minor salivary gland. Transoral resection. *Rev Esp Cir Oral Maxillofac.* 2008;30:201–204.
5. Rahnama M, Orzęda-Koszel U, Czupkałło L, Łobacz M. Pleomorphic adenoma of the palate: a case report and review of the literature. *Wspolczesna Onkol* 2013; 17: 103-106.
6. Chooback N, Shen Y, Jones M, Kasaian K, Martin M, Ng T, et al. Carcinoma ex pleomorphic adenoma: case report and options for systemic therapy. *Curr Oncol [Internet]. Multimed Inc.;* 2017 Jun [cited 2018 Jun 21];24(3): e251–254.
7. Ganly I, Patel SG, Coleman M, Ghossein R, Carlson D, Shah JP. Malignant minor salivary gland tumors of the larynx. *Arch Otolaryngol Head Neck Surg.* 2006; 132: 767-770.
8. S Patel, WF Mourad, C Wang, B Dhanireddy, Dhanireddy B, Concert C, Ryniak M et al. Postoperative radiation therapy for parotid pleomorphic adenoma with close or positive margins: treatment outcomes and toxicities. *Anticancer Research* Aug 2014, 34 (8) 4247-4251
9. Adisen MA, Misirlioglu M, Atil F. Pleomorphic adenoma arising from hard palate: case report. *Turk J Clin Lab.* 2017; 7(3): 86-88.