

A step by step laboratory guide for end to side anastomosis: chicken wing model

End to side anastomoz için adım adım laboratuvar kılavuzu: tavuk kanadı modeli

Emrah Egemen, Fatih Yakar

Gönderilme tarihi:21.12.2020

Kabul tarihi:18.01.2021

Abstract

Purpose: In vitro specimens are suitable models for the introduction of bypass surgery training of inexperienced neurosurgeons and residents. This paper aims to provide a guide for the applications of end to side anastomosis in the laboratory.

Materials and methods: The chicken wings were purchased from a local supermarket and used to perform end to side anastomosis. The microscissors, knotting forceps and 10/0 sutures were used, and all stages of the procedure were performed under a desktop microscope.

Results: The experience required for bypass surgery, which is a skillful field in neurosurgery practice, can be obtained in the chicken wing model, which is a cheap and easily accessible method.

Conclusion: The chicken wing model is a practical and feasible method in training the end to side anastomosis in a microsurgery laboratory.

Key words: Laboratory, anastomosis, bypass, microneurosurgery, chicken wing.

Egemen E, Yakar F. A step by step laboratory guide for end to side anastomosis: chicken wing model. Pam Med J 2021;14:396-400.

Özet

Amaç: In vitro örnekler, deneyimsiz beyin cerrahları ve asistanların baypas cerrahisi eğitimine giriş için uygun modellerdir. Bu makale, laboratuvarında end to side anastomoz uygulamaları için bir rehber sağlamayı amaçlamaktadır.

Gereç ve yöntem: Tavuk kanatları yerel bir süpermarketten satın alındı ve 'end to side' anastomoz yapmak için kullanıldı. Mikroskaslar, düğümlenme pensleri ve 10/0 sütürler kullanıldı ve prosedürün tüm aşamaları bir masaüstü mikroskobu ile gerçekleştirildi.

Bulgular: Nöroşirürji pratiğinde ustalık gerektiren bir alan olan baypas cerrahisi için gerekli deneyim, ucuz ve kolay ulaşılabilir bir yöntem olan tavuk kanadı modelinde elde edilebilir.

Sonuç: Tavuk kanadı modeli, bir mikrocerrahi laboratuvarında 'end to side' anastomoz eğitiminde pratik ve uygulanabilir bir yöntemdir.

Anahtar kelimeler: Laboratuvar, anastomoz, bypass, mikronöroşirürji, tavuk kanadı.

Egemen E, Yakar F. End to side anastomoz için adım adım laboratuvar kılavuzu: tavuk kanadı modeli. Pam Tıp Derg 2021;14:396-400.

Introduction

Donaghy and Yasargil first described extra-intra cranial bypass surgery in 1967 [1]. The main indications are occlusive diseases (Moyamoya disease), complex vascular lesions (fusiform or dolichoectatic giant aneurysms), and skull base tumours [2].

Laboratory studies should be considered as the first and most important step for training inexperienced neurosurgeons and residents. For bypass surgery training, anaesthetized rats

[3] (in vivo) and porcine [4], chicken [5] and turkey wings [6] (in vitro), gauze and silicon tube [7, 8] and polyvinyl alcohol hydrogel models [9] (artificial materials) have been described in the literature. The use of chicken wings was first described by Hino [5] in 2003 for bypass surgery. This method was accepted worldwide and imitated by many authors [6, 10, 11].

This study aims to provide a guide of the chicken wing model, which is a simple and easy method to apply for neurosurgeons who want to gain experience in the end to side anastomosis.

Materials and methods

The chicken wings can be purchased from any local supermarket. The various size of microscissors and knotting forceps, 26G intravenous (IV) cannula, monoprolen 10/0

suture (Boz Medical, Ankara, Turkey), 30° straight stainless steel knife, and needle holder were also provided (Fig 1A). All procedures were performed under a desktop microscope (Leica M80 stereo Microscope, Wetzlar, Germany) (Fig 1B).

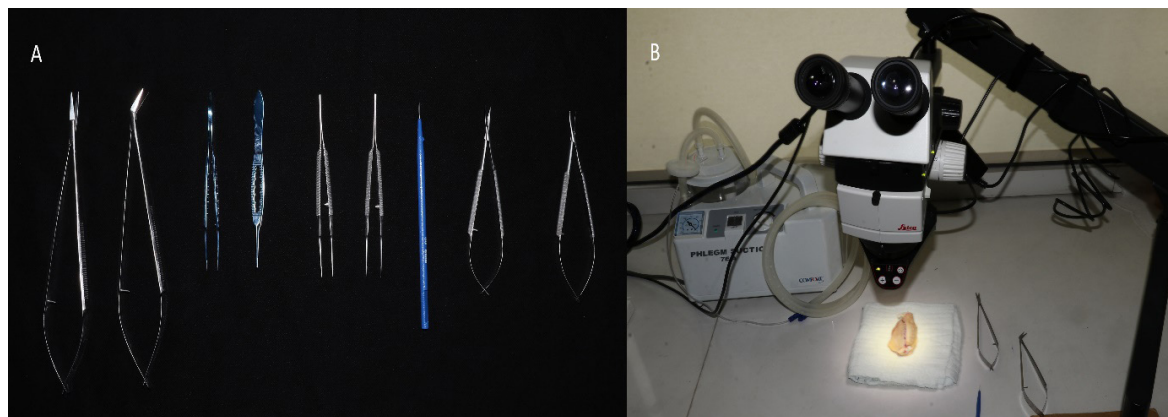


Figure 1 A. The laboratory instruments: microscissors, knotting forceps, 30° straight stainless steel knife, and needle holder. **B.** Desktop microscope was available during all stages of the procedure

The brachial artery was defined and indicated by dashed lines (Fig 2A, B). The skin was cut by micro scissors and knotting forceps. The proximal and distal end of the brachial artery was revealed (Fig 2C, 2D). All skin was dissected (Fig 2E), and a closer image was captured (Fig 2F).

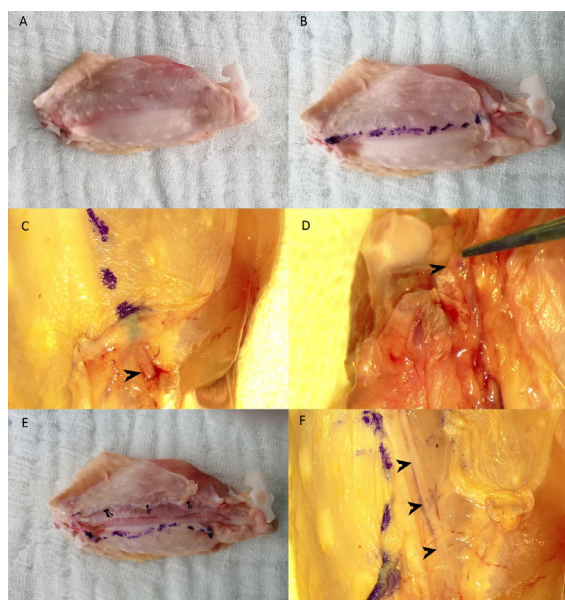


Figure 2 A, B. The chicken wing was prepared, and dashed lines indicated the brachial artery. **C, D.** Proximal and distal end of the brachial artery were dissected. **E.** The skin was dissected throughout, and the brachial artery was marked with nails. **F.** A closer image was captured, and the brachial artery was marked with arrows.

The layer over the artery and vein was dissected by sharp dissection (Fig 3A). The artery and vein were revealed and separated (Fig 3B, 3C). A coloured rectangular rubber dam was placed under the vessel to make the background uniform (Fig 3D). A 26G IV cannula was inserted into the artery, and the blood material was cleared from the lumen with saline infusion (Fig 3E). The recipient artery was 1 mm in size (Fig 3F).

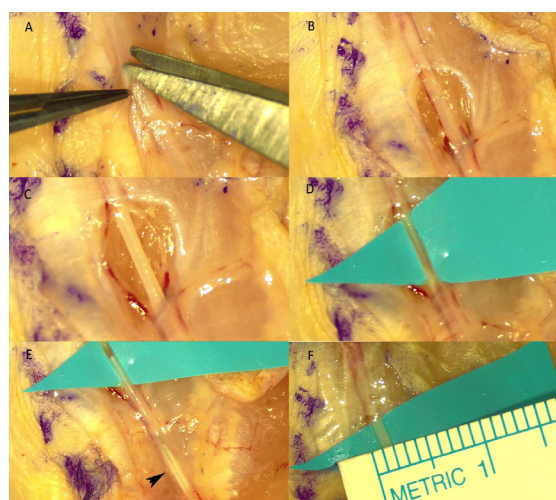


Figure 3 A, B. The layer over the recipient artery was sharply dissected. **C.** The brachial vein and all periadventitial tissue were dissected. **D.** A coloured rectangular rubber dam was placed under the brachial artery. **E.** The cannula was inserted into the artery, and the blood material was cleared with saline infusion. **F.** The diameter of the recipient artery was 1 mm.

The donor brachial artery was prepared for bypass (Fig 4A). The artery was painted with a surgical pen and cut in fish-mouth fashion, and the 2mm size was gained (Fig 4B, 4C).

The recipient artery was painted, and a 2mm arteriotomy was performed with a 30° knife and micro scissors (Fig 4D-4F).

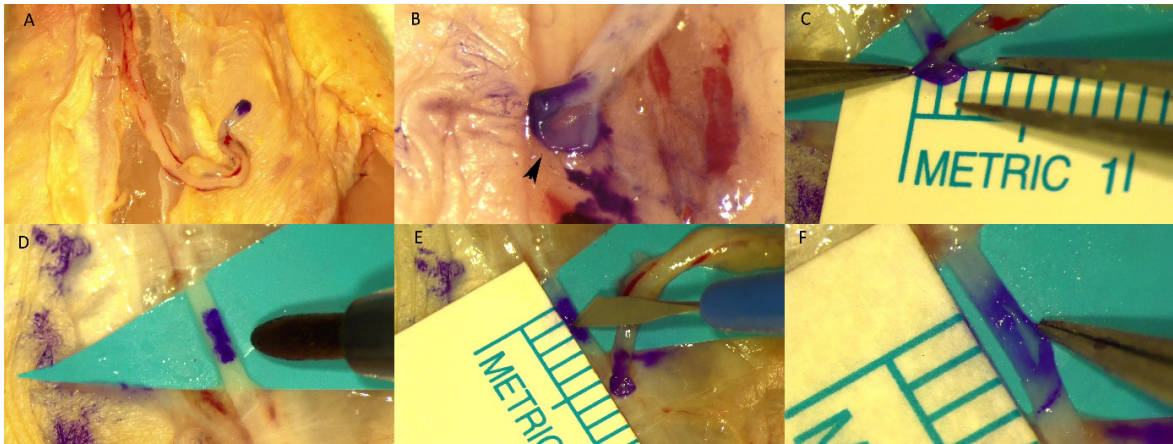


Figure 4 **A.** The donor artery was dissected in another chicken wing and painted with a surgical pen. **B.** The artery was cut in fish mouth fashion, and the arrow shows the toe of the donor artery. **C.** The size of the donor artery after fish mouth fashion cut was 2 mm. **D.** The recipient artery was painted with a surgical pen. **E.** The arteriotomy was done with a 30° knife and micro scissors. **F.** The size of the arteriotomy was 2 mm in size.

The first and second stitches were placed through the toe and heel, respectively using 10/0 monoprofen suture (Fig 5A). The anastomosis was performed as interrupted ties (Fig 5B, 5C).

At the end of the procedure, saline was injected through an IV cannula, and the water tightness of the anastomosis was checked (Fig 5D).

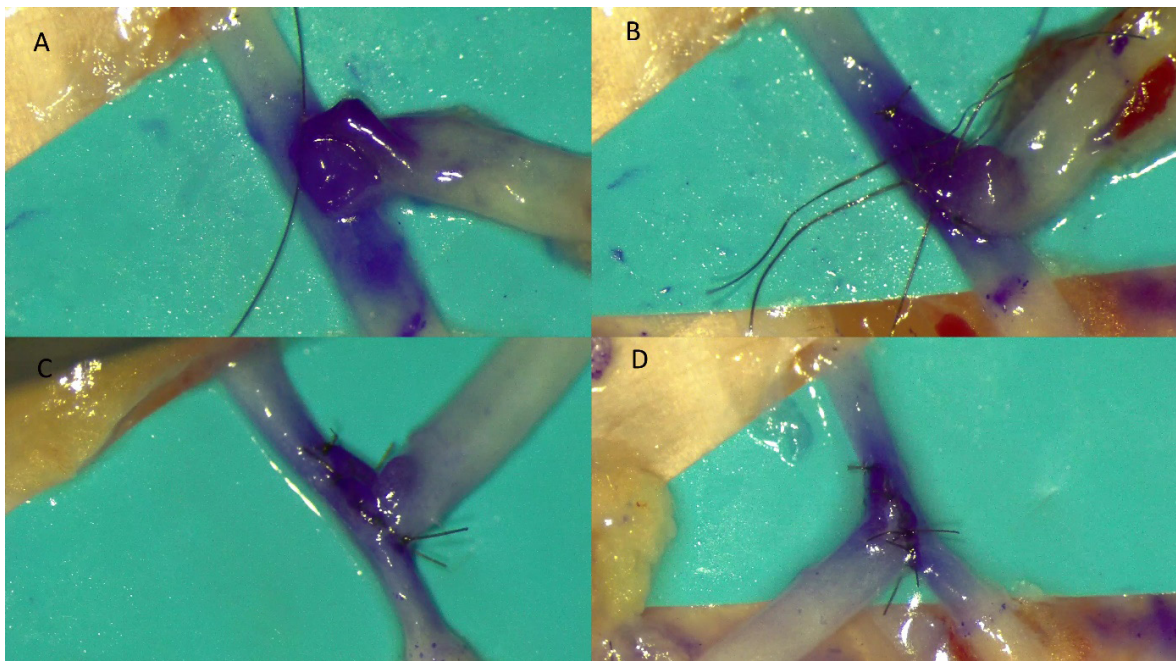


Figure 5 **A.** The first and second stitches were placed through the toe and heel, respectively using 10/0 monoprofen suture. **B, C.** The anastomosis was performed as interrupted ties at both sides of the arteriotomy. **D.** The cannula was inserted, and the water tightness of the anastomosis was checked with saline infusion

Results

Use of the chicken wing model is an effective method for the end to side anastomosis training. This technique provides experience in dissection, using 10/0 sutures and working with narrow diameter vessels. One of the main advantages is that the use of the material does not require ethics committee approval, and it is also cheap and readily available.

Discussion

Due to the widening of indications for bypass surgery, neurosurgeons should pay attention to their training on this subject. On the other hand, repairing injured vessel during surgery needs sophisticated skill and experience which could be gained in advance. In terms of achieving the required level of mastery for anastomosis techniques, it is paramount to apply these techniques in the laboratory at the first stage. This study is a useful guide for inexperienced surgeons and residents who will work in this field.

Many materials for anastomosis training have been described: in vivo, artificial, and in vitro models [9, 12]. Trials in living organisms (anaesthetized experimental animals) are the optimal method for training [3, 13]. However, this method is not easy to apply due to the approval of the ethics committee, the need for an animal experiment certificate, the requirement of a veterinarian, and increased expenditure. Artificial modelling is also a good option for training, but the most critical drawback is that the sense of tissue cannot be perceived while working with these materials. Besides, these materials cannot be considered as low cost [3, 9]. In vitro models stand out in anastomosis training because they do not require ethics committee approval and cost is low. Also, the surgeon can perceive the tissue sensation during the procedure.

The diameter of the cortical branch of MCA is often <1 mm in Moyamoya disease [14]. In normal superficial temporal artery (STA) – middle cerebral artery (MCA) bypass surgery, the recipient vessel should be at least 1mm in size [15]. The required diameter can be easily provided in chicken wings. (Fig 3F) It is predicted that young surgeons need to perform 10,000 stitches before performing the STA – MCA bypass [7]. The stitch exercises are

possible in the chicken wing model because it is easy to prepare and feasible in daily life. More periadventitial tissue dissection is required to reveal the vascular structures in the chicken wing than intracranial vessels. However, this procedure will increase the experience of the surgeon both in dissection and preparing STA for anastomosis [6].

Abla et al. [6] compared the turkey and chicken wings' brachial artery models. The turkey wing brachial artery was superior in diameter, length, and there was less variability in the vessel diameter. In the survey of the participants in this study, living rat models were evaluated as the most appropriate method for anastomosis training. However, they also concluded that turkey wings were superior to chicken wings and silicone tubes. Nevertheless, it is known that obtaining chicken wings from local supermarkets is more comfortable and cheaper than turkey wings.

One of the features of the models in anastomosis training should be the monetary burden [16]. The desktop microscope was used in previous studies instead of an operating microscope, and no problem was reported [14]. We used a desktop microscope that belongs to medical school. There are lots of online stores that surgeons can purchase surgical instruments at low cost. The cost of surgical instruments used in this study (Fig 1A) was under one hundred United States dollars. Unlike their counterparts used in the operating room, these instruments can be used for a more extended period as they will not be exposed to abrasion of the sterilization processes.

Limitations

The inability to replicate thrombotic phenomena and the absence of pumping are the main limitations for chicken wing model. The storage period of the chicken wings in the refrigerator is less than a week, and the resistance of the tissue decreases day by day and reduces the success of the application.

In conclusion, the low cost and easily accessible models should be considered as the cornerstone of anastomosis training for inexperienced neurosurgeons and residents. The surgeon's experience in dissection and suturing with using in vitro specimens will increase the success of bypass surgery.

Conflict of interest: The authors declare no conflict of interest.

References

1. Yasargil MG, Yonekawa Y. Results of microsurgical extracranial arterial bypass in the treatment of cerebral ischemia. *Neurosurgery* 1977;1:22-24. <https://doi.org/10.1227/00006123-197707000-00005>
2. Wessels L, Hecht N, Vajkoczy P. Bypass in neurosurgery-indications and techniques. *Neurosurg Rev* 2019;42:389-393. <https://doi.org/10.1007/s10143-018-0966-9>
3. Hwang G, Oh CW, Park SQ, Sheen SH, Bang JS, Kang HS. Comparison of different microanastomosis training models: Model accuracy and practicality. *J Korean Neurosurg Soc* 2010;47:287-290. <https://doi.org/10.3340/jkns.2010.47.4.287>
4. Nam SM, Shin HS, Kim YB, Park ES, Choi CY. Microsurgical training with porcine thigh infusion model. *J Reconstr Microsurg* 2013;29:303-306. <https://doi.org/10.1055/s-0033-1333623>
5. Hino A. Training in microvascular surgery using a chicken wing artery. *Neurosurgery* 2003;52:1495-1497. <https://doi.org/10.1227/01.neu.0000065174.83840.62>
6. Abila AA, Uschold T, Preul MC, Zabramski JM. Comparative use of turkey and chicken wing brachial artery models for microvascular anastomosis training. *J Neurosurg* 2011;115:1231-1235. <https://doi.org/10.3171/2011.7.JNS102013>
7. Inoue T, Tsutsumi K, Adachi S, Tanaka S, Saito K, Kunii N. Effectiveness of suturing training with 10-0 nylon under fixed and maximum magnification (x 20) using desk type microscope. *Surg Neurol* 2006;66:183-187. <https://doi.org/10.1016/j.surneu.2005.11.064>
8. Matsumura N, Hayashi N, Hamada H, Shibata T, Horie Y, Endo S. A newly designed training tool for microvascular anastomosis techniques: Microvascular Practice Card. *Surg Neurol* 2009;71:616-620. <https://doi.org/10.1016/j.surneu.2007.12.024>
9. Mutoh T, Ishikawa T, Ono H, Yasui N. A new polyvinyl alcohol hydrogel vascular model (KEZLEX) for microvascular anastomosis training. *Surg Neurol Int* 2010;23;1:74. <https://doi.org/10.4103/2152-7806.72626>
10. Creighton FX, Feng AL, Goyal N, Emerick K, Deschler D. Chicken thigh microvascular training model improves resident surgical skills. *Laryngoscope Invest Otolaryngol* 2017;2:471-474. <https://doi.org/10.1002/lio2.94>
11. Schoeff S, Hernandez B, Robinson DJ, Jameson MJ, Shonka DC Jr. Microvascular anastomosis simulation using a chicken thigh model: Interval versus massed training. *Laryngoscope* 2017;127:2490-2494. <https://doi.org/10.1002/lary.26586>
12. Higurashi M, Qian Y, Zecca M, Park YK, Umezu M, Morgan MK. Surgical training technology for cerebrovascular anastomosis. *J Clin Neurosci* 2014;21:554-558. <https://doi.org/10.1016/j.jocn.2013.07.029>
13. Couceiro J, Castro R, Tien H, Ozyurekolu T. Step by step: microsurgical training method combining two nonliving animal models. *J Vis Exp* 2015;99:e52625. <https://doi.org/10.3791/52625>
14. Kim BJ, Kim ST, Jeong YG, Lee WH, Lee KS, Paeng SH. An efficient microvascular anastomosis training model based on chicken wings and simple instruments. *J Cerebrovasc Endovasc Neurosurg* 2013;15:20-25. <https://doi.org/10.7461/jcen.2013.15.1.20>
15. Vazkocy P, Horn P, Schmiedek P. Standard superficial temporal artery-middle cerebral artery bypass surgery in hemodynamic cerebral ischemia: indication and technique. *Operative Techniques in Neurosurgery* 1999;2:106-115. [https://doi.org/10.1016/S1092-440X\(99\)80002-4](https://doi.org/10.1016/S1092-440X(99)80002-4)
16. Tamrakar K. Learning microvascular anastomosis in low socioeconomic vascular models during residency. *Cureus* 2017;9:e1199. <https://doi.org/10.7759/cureus.1199>

Ethics committee approval: Ethics committee approval is not required for this type of study.

Contributions of authors

E.E. conceptualized and designed the article, and wrote the article. F.Y. performed the dissections and reviewed the literature. All authors approved the final manuscript as submitted and agree to be accountable for all aspects of the work.