



Uncommon Presentation of an Atrial Myxoma in an Adolescent Patient: A Case Report

Adolesan Bir Hastada Atriyal Miksomanın Nadir Bir Prezantasyonu:
Bir Olgu Sunumu

Emine Akkuzu¹, Sahin Sincar¹, Semiha Tokgoz², Gokhan Kalkan¹

¹Gazi University, Department of Pediatrics, Division of Pediatric Critical Care, Ankara, Turkey

²Gazi University, Department of Pediatrics, Division of Pediatric Cardiology, Ankara, Turkey

ABSTRACT

Cardiac myxomas are rare benign tumors in childhood. They most commonly occur in the left atrium. Atrial myxomas' irregular surface is associated with a high risk of embolic events. The majority of cardiac myxoma patients are diagnosed with cardiac symptoms. A limited number of case reports on neurological symptoms in childhood in the literature are diagnosed with cardiac myxoma after a detailed examination. We present a 16-year-old female patient with left atrial myxoma who presented with neurologic symptoms like diplopia and ataxia mimicking demyelinating neurological diseases.

Keywords: Ataxia, atrial myxomas, demyelinating diseases, stroke

ÖZ

Kardiyak miksomalar çocukluk çağının nadir görülen iyi huylu tümörleridir. Genellikle sol atriyumdan kaynaklanırlar ve düzensiz yüzeyleri nedeniyle embolik olaylar açısından yüksek risk taşırlar. Erişkinlerde kalp yetmezliği, pulmoner ödem gibi kardiyak bulgularla başvuru siktir, bunlar olmadan nörolojik semptomlarla başvuru az görülür. Literatürde, çocukluk çağında nörolojik semptomlar hakkında ayrıntılı bir incelemeden sonra kardiyak miksoma tanısı alan sınırlı sayıda vaka bildirimi bulunmaktadır. Burada, diplopi ve ataksi gibi demiyelinizan nörolojik hastalıkları taklit eden semptomlarla başvuran ve ayrıntılı nörolojik değerlendirme sonrası sol atriyal miksoma tanısı koyulan 16 yaşında kız hasta sunulmaktadır.

Anahtar Kelimeler: Ataksi, atriyal miksoma, demiyelinizan hastalıklar, inme

INTRODUCTION

Cardiac myxomas are rare benign tumors in childhood (1). They generally occur in the left atrium originating from the interatrial septum and fossa ovalis. Published case series in the literature usually involve the adult population. More than 50% of adult patients with left atrial myxoma present with symptoms of mitral valve stenosis or obstruction, and only a few of them present with neurologic findings (1). As myxoma in children is much less common, there are few case-based publications (2-5). Here, we present a 16-year-old female patient with cardiac myxoma who presented with

neurologic symptoms like diplopia and ataxia mimicking demyelinating neurological diseases.

CASE REPORT

A 16-year-old previously healthy female patient presented to another hospital emergency room with four days history of double vision, nausea, vomiting, and dizziness. The patient had not any underlying medical disorders and medication history. There was no positive family history of thromboembolic disease. The routine

Corresponding Author: Emine Akkuzu

Address: Gazi University, Department of Pediatrics, Division of Pediatric Critical Care, Ankara, Turkey

E-mail: eminencek@hotmail.com

Başvuru Tarihi/Received: 09.01.2021

Kabul Tarihi/Accepted: 31.03.2021



examination was normal at the time of admission in the other center except for inadequate introversion in the left eye and ataxia. Brain magnetic resonance imaging (MRI) of the patient showed three hyperintense white matter lesions of 2-3 mm in dimensions in the T2 series with an impression of demyelinating plaques in the context of the clinical picture (**Figure 1A**). The examinations of cerebrospinal fluid obtained from lumbar puncture for differential diagnosis were within normal limits. After evaluating pediatric neurology, they started a pulse steroid treatment course with a diagnosis of multiple sclerosis (MS). On the third day of the patient's hospitalization, the symptoms improved, but the diffusion MRI revealed multifocal areas of diffusion restriction in the cerebellum and thalamus consistent with acute ischemia. Transthoracic echocardiography (echo) was performed to evaluate the etiology of acute ischemic stroke, which demonstrated a left atrial mass. We took the patient over to our pediatric intensive care unit for further management.

On admission, the patient's general condition was stable, and her vital signs were within normal limits. On physical examination, she was conscious. Her Glasgow Coma Scale 15 (E:4, V:5, M:6), speech, pupils and eye movements, facial symmetry, muscle tone and strength, sensory examination, coordination, balance, gait, and reflexes were normal. Heart sounds were rhythmic with regular S1 and S2 without any murmur. Her respiratory sounds were normal, and there was no organomegaly. Her laboratory findings and coagulation values were completely normal. The patient's echo revealed a left atrium filled with a mass protruding to the mitral valve suggestive of myxoma (**Figure 1B**). Thorax angiographic computed tomography demonstrated a hypodense

mass of 33x26 mm in dimensions protruding to the lumen at the left atrial fossa ovalis. The patient had an operation to remove the mass lesion on the second day of her admission (**Figure 2**). The procedure was performed under cardiopulmonary bypass, and the interatrial septum was resected and repaired in surgery besides the mass. Histopathological diagnosis confirmed the diagnosis of myxoma. The patient had an uneventful course and was transferred from the intensive care unit to the wards on her fourth day of admission. She was discharged after ten days of hospitalization. One month after the patient was discharged, she came to the outpatient clinic control, and her general condition was very good, her physical and neurological examination was completely normal. We continue to follow-up her for risk of recurrence.

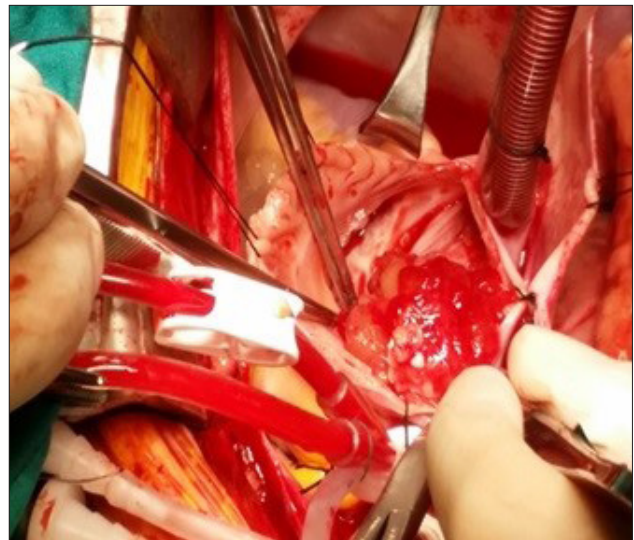


Figure 2. The appearance of intraoperative mass

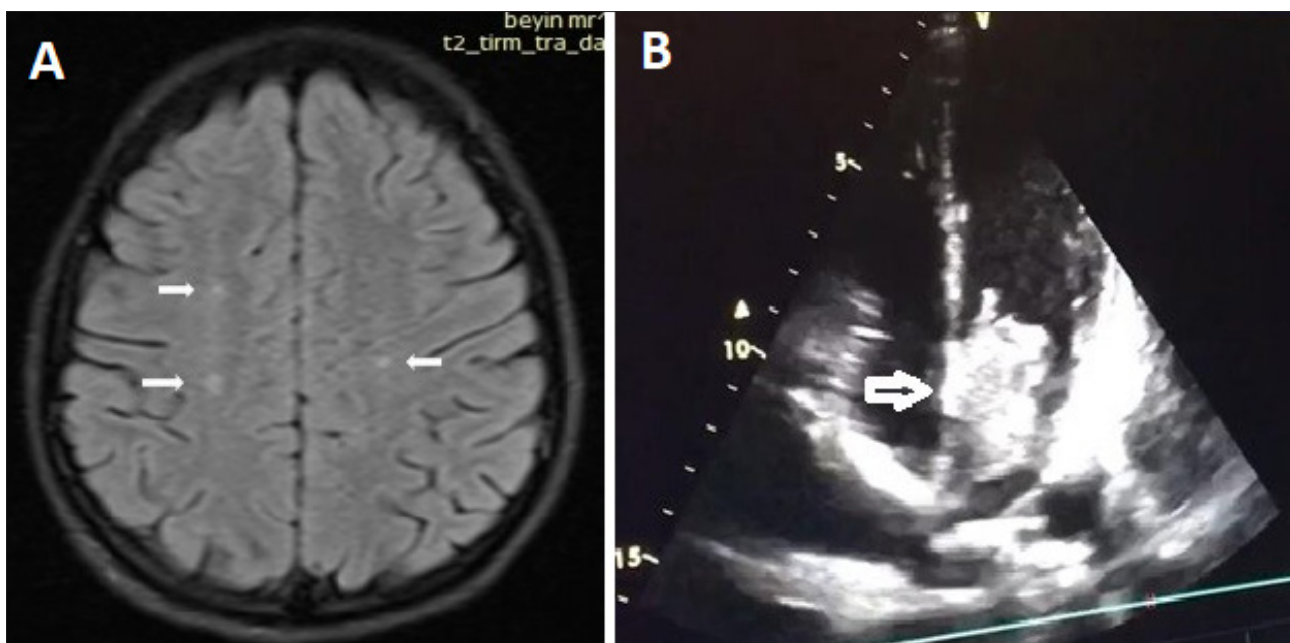


Figure 1. A) Hyper intense white matter lesions in T2 series of cranial MRI (Arrows). **B)** The mass that fills the left atrium almost completely (Arrow)



DISCUSSION

Cardiac myxomas are the most common benign tumors of the left atrium, and they are rarely observed in children. Macroscopically, myxomas have a gelatinous structure with an attachment to the atrium wall through a short, broad base peduncle (1). The mean age at diagnosis in children is 9-10 years. The primary diagnosis tool is often transthoracic echo with the typical appearance of mobile mass from fossa ovalis.

Although myxomas usually present with signs of heart failure in adulthood and infancy, rare strokes might be the main presentation. The myxoma's fragile structure may cause primary central or peripheral nervous system embolization resulting in ischemic stroke with a mortality and morbidity rate of 20% and 50-80%, respectively (6).

There are only 18 pediatric patients in the literature with the initial neurologic manifestations of central nervous system embolization preceding the diagnosis of cardiac myxoma (7). These patients were mostly adolescents and commonly had middle cerebral artery involvement leading to hemiparesis or hemiplegia. Contrary to the literature, our patient had a unique neurologic presentation with diplopia and ataxia, suggesting demyelinating diseases. This case report is the first in the literature to describe an initial presentation with acute cerebellar artery ischemia.

Unfortunately, cardiac myxoma patients with neurologic manifestations have delays in diagnosing their cardiac pathologies (8). Our patient had a similar course with an in-depth investigation of neurologic disease. Diplopia, ataxia, and vomiting, instead of significant motor neurological deficits, complicated the picture more to resemble a clinical syndrome as MS. Despite this, our patient had her final diagnosis without any further complications.

Based on reports in the literature, nonspecific findings such as fever, fatigue, loss of appetite, and rash may present some cardiac myxoma patients (9). We discovered that the patient has complained of fatigue and appetite loss for the last six months without seeking any medical attention.

In cardiac myxomas, treatment is performed as early as possible after the diagnosis. The removal of the mass with endocardium reduces the risk of recurrence as it originates mostly from the interatrial septum (10). The risk of recurrence in patients after surgery is reported to be 5-7% (9), which requires long-term follow-up of young patients. Our patient had the operation on the following day of the diagnosis. She had a mass removal with the interatrial septum.

CONCLUSION

Cardiac myxomas in childhood are very rare benign tumors. However, they can cause fatal complications, such as stroke or heart failure. Therefore, patients presenting with neurological manifestations should undergo a prompt cardiac evaluation to exclude myxoma.

ETHICAL DECLARATIONS

Informed Consent: Written informed consent was obtained from all participants who participated in this study.

Referee Evaluation Process: Externally peer-reviewed.

Conflict of Interest Statement: The authors have no conflicts of interest to declare.

Financial Disclosure: The authors declared that this study has received no financial support.

Author Contributions: All of the authors declare that they have all participated in the design, execution, and analysis of the paper, and that they have approved the final version.

Acknowledgments: We thank our patient, her families, and the faculty and staff of the Divisions of Child Neurology, Radiology, and Pediatric Cardiovascular Surgery.

REFERENCES

1. Careddu L, Oppido G, Petridis FD, et al. Primary cardiac tumours in the paediatric population. *Multimedia Manual of Cardiothoracic Surgery: MMCTS*. 2013 ;2013:mmt013. DOI: 10.1093/mmcts/mmt013.
2. Ise H, Ishikawa N, Nakanishi S, Kamiya H. Giant left atrial myxoma causing acute ischemic stroke in a child. *Surg Case Rep* 2018;4(1):6.
3. Aldajani AA, Mudhry MA, Mir A, Albaradie RS. Cardioembolic Stroke from an Atrial Myxoma in a Pediatric Patient: A Case Report and Review of the Literature. *J Heart Valve Dis* 2017;26:646-50.
4. Juaneda I, Peirone A, Contreras A, et al. A Rare Cause of Pediatric Stroke. *World J Pediatr Congenit Heart Surg* 2017;8:220-23.
5. Akin A, Karagöz T, Şahin M, Özkutlu S. Cerebral Embolism from Left Atrial Myxoma in a Child: Case Report. *Türkiye Klinikleri J Cardiovasc Sci*. 2012;24(2):177-80.
6. Roach ES, Golomb MR, Adams R, et al. management of stroke in infants and children: a scientific statement from a Special Writing Group of the American Heart Association Stroke Council and the Council on Cardiovascular Disease in the Young. *Stroke* 2008;39:2644-691.
7. Macias E, Nieman E, Yomogida K, et al. Rare presentation of an atrial myxoma in an adolescent patient: a case report and literature review. *BMC Pediatr* 2018;18:373.
8. Xu J, Gao Y, Li Y, et al. Left atrial myxoma presenting as headache in the pediatric patient. *J Emerg Med* 2015;48:161-64.
9. Uzun O, Wilson DG, Vujanic GM, et al. Cardiac tumours in children. *Orphanet J Rare Dis* 2007;2:11.
10. Sernich S, Chauhan A, Singh D, et al. Left atrial myxoma in a child: a challenging diagnosis of a rare lesion. *World J Pediatr Congenit Heart Surg* 2013;4:220-22.