

The effectiveness of antioxidant drugs such as N-acetylcysteine and Ozone on the stasis zone

N-asetilsistein ve ozon gibi antioksidan ilaçların staz zonu üzerindeki etkinliği

Mustafa Atabey, Muhammed Raşid Aykota, Meriç Emre Bostancı, Ayça Taş

Gönderilme tarihi:14.01.2021

Kabul tarihi: 23.03.2021

Abstract

Purpose: Stasis zone, the zone around the coagulation zone, is important for the prevention necrosis in burns. Various drugs were studied in literature to prevent necrosis in stasis zone. The previous researches have shown the effectiveness of Nacetylcysteine treatment on both remote organs and local side in thermal injury. Demonstration of the effectiveness of N acetylcysteine and Ozone on stasis zone prevention in thermal injury was the goal of this study.

Methods: For this purpose, 24 4-month-old Wistar albino type female rats weighing 200±20 g were used in the study. Compound burning model was made in these rats. Next, the compound was applied to the combustion model to compare the effectiveness of N-acetylcysteine and Ozone. To identify histopathological destruction severity a scoring method was applied. Malondialdehyde (MDA), Glutathione Peroxidase (GPx), Superoksid dismutase (SOD), and catalase (CAT) levels were analyzed in serum samples of the rats to find out the alterations in the balance between oxidatitaion and antioxidation system.

Results: While the highest MDA levels were observed in group I, the decrease was significant in group II and III ($p=0.03$ and $p<0.02$). SOD levels were significantly higher in group III compared to group II ($p<0.05$). CAT levels were higher in group II and III than group I ($p<0.001$, $p<0.001$). GPx levels were higher in group II ($p<0.001$), and group III ($p<0.001$). Histopathological scores were lower in group III than group I ($p=0.001$).

Conclusion: This study showed that both Ozone and N-acetylcysteine are effective agents in rescuing the stasis site. It was also concluded that Ozone might be more beneficial than N-acetylcysteine.

Key words: Burn, zone of stasis, antioksidan, ozon, oxidant.

Atabey M, Aykota MR, Bostancı ME, Tas A. The effectiveness of antioxidant drugs such as N-acetylcysteine and Ozone on the stasis zone. Pam Med J 2021;14:474-480.

Öz

Amaç: Pıhtılaşma bölgesi etrafındaki bölge olan durağanlık bölgesi, yanıklarda nekrozun önlenmesi için önemlidir. Literatürde staz bölgesinde nekrozu önlemek için çeşitli ilaçlar çalışılmıştır. Önceki araştırmalar, termal yaralanmada N-asetilsistein tedavisinin hem uzak organlarda hem de lokal tarafta etkinliğini göstermiştir. Buna bağlı olarak, N-asetilsistein ve Ozonun termal yaralanma durağan bölgesi önleme etkinliğinde gösterilmesi amaçlanmıştır.

Gereç ve yöntem: Bu amaçla çalışmada, ağırlıkları 200±20 g olan 24 adet 4 aylık Wistar albino tipi dişi sıçan kullanıldı. Bu sıçanlarda bileşik yanma modeli yapıldı. Sonra N-asetilsistein ve Ozonun etkililiğini karşılaştırmak için bileşik yanma modeline uygulandı. Histopatolojik yıkım şiddetini belirlemek için bir skorlama yöntemi uygulandı. Oksidasyon ve antioksidasyon sistemi arasındaki dengede meydana gelen değişiklikleri saptamak için sıçanların serum örneklerinde Malondialdehid (MDA), Glutasyon Perpxidaz (GPx), Superoksid dismutaz (SOD) ve katalaz (CAT) seviyeleri analiz edildi.

Bulgular: Grup I'de en yüksek MDA düzeyleri gözlenirken, grup II ve III'te azalma anlamlıydı ($p=0.03$ and $p<0.02$). SOD düzeyleri grup III'te grup II'ye göre anlamlı olarak yüksekti ($p<0,05$). CAT seviyeleri grup II ve III'te grup I'den daha yüksekti ($p<0,001$, $p<0,001$). GPx düzeyleri grup II ($p<0,001$) ve grup III ($p<0,001$)'de daha yüksekti. Histopatolojik skorlar Grup III'de grup I'den daha düşüktü ($p=0,001$).

Sonuç: Bu çalışmada, hem Ozon hem de N-asetilsisteinin, staz bölgesinin kurtarılmasında etkili ajanlar olduğunu göstermiştir. Ayrıca Ozon, N-asetilsisteinden daha faydalı olabileceği sonucuna varılmıştır.

Anahtar kelimeler: Yanık, staz bölgesi, antioksidan, ozon, oksidan.

Atabey M, Aykota MR, Bostancı ME, Taş A. N-asetilsistein ve ozon gibi antioksidan ilaçların staz zonu üzerindeki etkinliği. Pam Tıp Derg 2021;14:474-480.

Mustafa Atabey, Ass. Prof. Biruni University, Faculty of Medicine, Department of General Surgery, Istanbul, Turkey, e-mail: atabey21@gmail.com (https://orcid.org/0000-0002-9226-4358)

Muhammed Raşid Aykota, Ass. Prof. Pamukkale University, Faculty of Medicine, Department of General Surgery, Denizli, Turkey, e-mail: maykota@pau.edu.tr (https://orcid.org/0000-0003-1862-6186)

Meriç Emre Bostancı, MD. Sivas Cumhuriyet University, Faculty of Medicine, Department of Surgical Oncology, Sivas, Turkey, e-mail: drmericembostanci@gmail.com (https://orcid.org/0000-0002-0429-9834)

Ayça Taş, Ass. Prof. Sivas Cumhuriyet University, Faculty of Health Science, Department of Nutrition and Diet, Sivas, Turkey, e-mail: aycatas@cumhuriyet.edu.tr (https://orcid.org/0000-0002-7132-1325) (Corresponding Author)

Introduction

Severe thermal damage causes destruction of tissues and local infection, whereas excessive inflammation may cause remote organ injury [1]. Severe thermal injury causes three different types of destruction on the burned side. The zone around the coagulation is known as the stasis zone. Absolute loss of tissues is seen in this zone [2]. Oxidative stress is the leading cause of ischemia-induced necrobiosis. Thermally injured tissues release mediators continuously that promotes ongoing destruction in stasis zone following the first 24 hours of initial trauma [3, 4]. Protection of this stasis zone from running on damage is a challenging problem and is still in the area of active research [5-7]. A variety of different treatment modalities for stasis zone in addition to sufficient electrolyte and fluid replacement can found in the literature [8, 9]. N-acetylcysteine (NAC) not only as a direct scavenger but also as a well-known precursor of glutathione peroxidase (GPx) was the subject of many previous studies. Former studies demonstrated that a strong antioxidant NAC administration diminishes the release of the cytokine on the zone of stasis [10-12]. Ozone was originally applied in medicine in an empirical and rather imprecise manner for the last about 200 years since the first report for sterilization in 1826; and the mechanisms of Ozone's action are omnifarious involved in direct antimicrobial effect, immunoregulation, antioxidant defenses, epigenetic modification, even more, other potent properties such as biosynthetic, analgesic and vasodilative effects [13, 14].

Lipid peroxidation causes the formation of MDA. The severity of necrobiosis due to oxidative stress may be monitored by analyzing the level of MDA. The enzymatic activities antioxidants as if SOD, CAT, GPx in thermal injury-induced damaged tissues may decrease the density of oxidative stress [15, 16]. In this study, our goal was to show and compare the beneficial effects of drugs known as Ozone and N acetylcysteine on the stasis zone in a rat mode.

Materials and methods

Animal material

Female Sprague-Dawley rats (n=24), weighing 200±20 gr were used in the study

(Sivas Cumhuriyet University, Animal Ethics Committee. The rats were accommodated in cages in an environment of 22°C with a cycle of half daylight and dark. Animals were feed and watered in a standard manner. Three equal groups consisting of eight animals in each were formed. Intraperitoneal ketamine 30 mg/kg, and 0.005 kg/kg xylazine was administered as anesthetic agents during burning procedure. Morphine (1 mg/kg) was used intramuscularly manner before the contact of the coombs device.

Stasis zone model

As established by Regas and Ehrlich [17] in their previous study the thermal wound formatted by brass comb. The brass comb has four prongs (0.5 cm x 2cm) separated by three 5-mm notches to create four distinctive burn areas divided by three interspaces (1 cm x 2 cm) of unburned skin. The interspaces represent the zones of stasis, and the burned areas represent the coagulation zones (Figures 1 and 2). Ringer Lactate 10 ml/kg intraperitoneally was used for liquid resuscitation following the thermal injury. No treatment was administered in group I (control group). Group II underwent NAC therapy intraperitoneal (100 mg/kg/day) 10 days long, whereas group III underwent Ozon therapy intraperitoneal (10 µg/mL/day) for the same period. A general anesthetic, thiopental sodium, 50 mg/kg was used for scarificatio of rats on the 10th day.



Figure 1. The probe that was used in the experiment

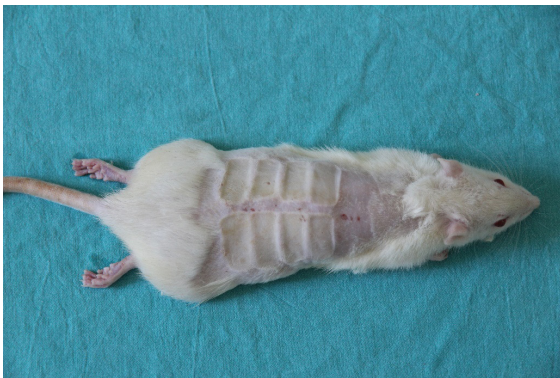

Figure 2. The “comb burn” model was applied to the dorsum of the rat to perform the burn injury

Collection of blood samples

No anticoagulant was administered for the collection of serum samples. Approximately half an hour waited for clotting at 25°C. At 4°C samples of serums centrifuged at 2000xg for a quarter-hour. Without disturbing the white buffy layers, serum layers were pipetted off. Afterward, samples were frozen at minus 80°C and serums stored on the cubes of ice.

Biochemical analysis

Serum samples from animals were taken into tubes for biochemical analysis. Biopsies of skins were performed. Levels of MDA, SOD, and activities of CAT, GPx were measured in serums in each group.

Malondialdehyde (MDA) pmol/ml assay

MDA levels were made according to the Yagi K. method. Solutions of 0,084 M sulfuric acid, 10% phosphotungstic acid and thiobarbituric acid were prepared [18].

Superoxide dismutase (SOD) nmol/min/ml assay

The serum samples that were taken were prepared according to the method of McCords and Fridowich. Pipetting was performed according to the following table. The cuvettes were again compared, reading the initial absorbance (A1) at 505 nm and 37°C after a 30 s of delay phase, and reading the final absorbance after 3 min (A2) [19].

Catalase nmol/min/ml assay

Catalase activity was calculated using Aebi's method. A 50 mM of pH 7.0 phosphate buffer was prepared. A 30 mM hydrogen peroxide solution was also prepared, and the solutions were prepared at the ratios given in table. The sample was diluted 50-fold. As soon as hydrogen peroxide was added, the absorbance values were read kinetically at 240 nm [20].

Glutathione peroxidase (GPx) nmol/min/ml assay

This was prepared according to the method of Goldberg and Spooner. The catalytic activity was determined by following the reduction kinetically at 340 nm due to the oxidation of the absorbance of NADPH [21].

Histopathological analysis

A histopathological scoring method is a tool by which semi-quantitative data can be obtained from tissues. Histopathological evaluation was performed on basis of a scoring system (Table 1). Tissue samples in the form of a ribbon were taken from the burn line of the rats. The samples were nestled in 10% formaldehyde, and paraffin blocks were prepared by passing the coagulation zone and ischemia (stasis) zone through routine tissue monitoring procedures. Sections with a thickness of 6 μ taken from the prepared paraffin blocks were stained with hematoxylin and eosin for histopathological examination. Based on the intensity of histopathological lesions, healing of the burn wound was scored as 0= none, 1= mild, 2= moderate, and 3= dense 4= extremely dense (Table 1) by checking the amount of edema, hyperemia, epithelial degeneration necrosis, MNH infiltration, polymorphonuclear neutrophil leukocytes (PMNL) infiltration, and fibroblast-fibrocyte on microscopic examinations.

Table 1. Inflammation and destruction scores

Pathologic lesion	Score
Edema	2
Hyperemia	2
Epithelial degeneration	3
Necrosis	4
Polymorph nuclear infiltration	2
Mononuclear infiltration	4
Connective tissue growth	4
Total	20

Statistical analysis

The data were obtained with the measurement since the parametric test assumptions were met (Kolmogorov-Smirnov) in the evaluation of the data by uploading the data to the SPSS 22.0 software (IBM Corp., Armonk, NY, USA) program. Chi-square test and Fisher's exact tests were performed for the statistical evaluation of histopathological findings. Mean±standard deviation (SD) was denoted for values. In addition, independent Student's t test was applied when the parametric test assumptions were met. Data were expressed as number as mean±standard deviation values. When comparing two independent samples in terms of a variable, the significance test of the difference between the two means was used, and the error level was taken as 0.05. Value of $p < 0.05$ was considered statistically significant.

Results

No mortality detected in animals in the time elapsed between the burn trauma and scarification.

Serum oxidative and antioxidative marker levels, MDA, SOD, CAT, and GPx level can be seen Table 2. The highest MDA levels was in group I, and the decrease was significant in group II and III ($p=0.03$ and $p<0.02$). Furthermore, MDA was lower in group III than in group II ($p<0.05$). SOD levels were detected significantly high in group II and III than group I ($p=0.037$, $p=0.018$). In addition, SOD levels were significantly higher in group III compared to group II ($p<0.05$). CAT levels were higher in group II and III than group I ($p<0.001$, $p<0.001$) compared to group I. GPx levels were higher in group II ($p<0.001$), and group III ($p<0.001$) than group I. In addition, GPx levels were higher in group III ($p=0.002$) when compared to group II. Figure 3 demonstrated the scores of histopathology in specimens. Histopathological scores were denoted statistically lower in group II than in group I ($p=0.015$). Also, scores were lower in group III than group I ($p=0.001$). The histopathological scores were lower in group III compared to group II ($p=0.013$).

Table 2. MDA, SOD, CAT and GPx levels in serum

Parameters	Group I (n=8)	Group II (n=8)	Group III (n=8)
		(mean ±SD*)	
MDA (pmol/ml)	12.29±3.02	6.25±1.56 ^a	3.00±0.67 ^{a,b}
SOD (nmol/min/ml)	13.84±6.73	26.12±5.42 ^a	39.29±6.74 ^{a,b}
CAT (nmol/min/ml)	3.51±1.47	20.45±6.08 ^a	34.54±15.08 ^{a,b}
GPx (nmol/min/ml)	16.74±12.21	56.15±26.18 ^a	128.10±90.95 ^{a,b}

^a $p < 0.001$.vs group I (Mann–Whitney U test), ^b $p < 0.05$ vs. group II (Mann–Whitney U test), * SD: standard deviation

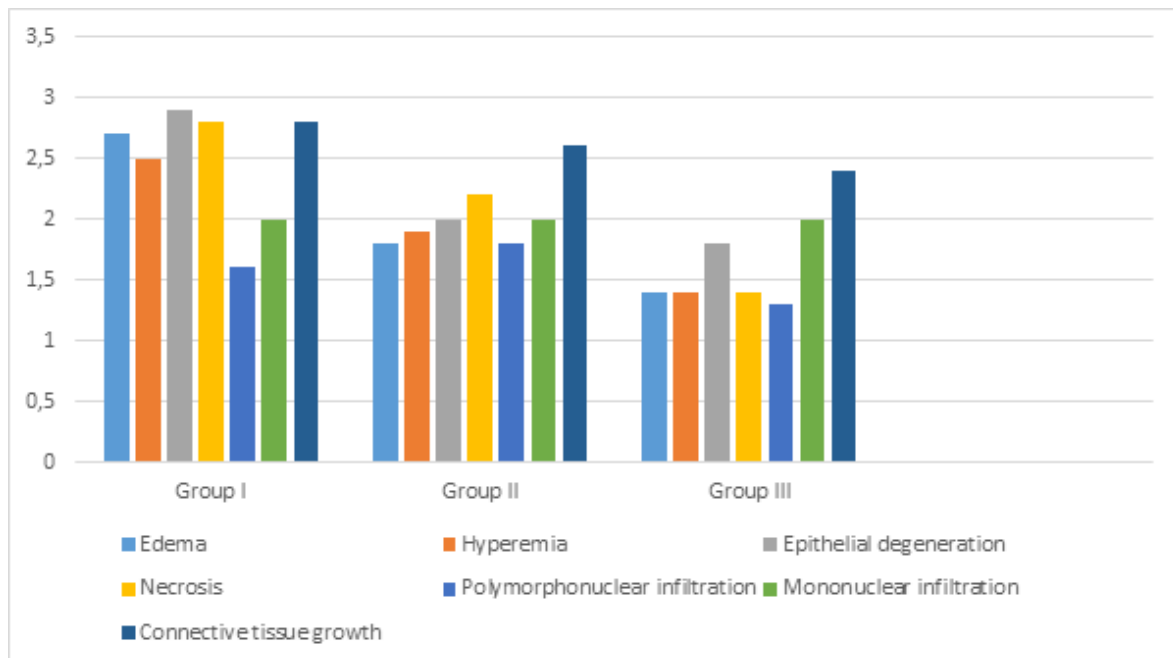


Figure 3. Scoring of burn wound healing according to the intensity of histopathological lesions

Discussion

Severe thermal injuries can cause to start many mechanisms and biochemical pathways, which are prone to cell death, and difficult for the host to balance and respond appropriately. Necrobiosis in the zone of stasis due to swelling and apoptosis was shown in a previous study [22]. Time depended on three different types of apoptosis as immediate (first 30 min), intermediate (30 min-4 h), and delayed (after 4 h) were named by Godar [23]. Immediate one occurs due to the direct hit of burn injury whereas delayed one may be considered as a result of the combined effect of both primary and secondary hit of burn trauma. Secondary trauma triggers the infiltration of inflammatory cells, alteration in microcirculation, and release of oxygen-derived free radicals (ROS) [12, 16]. ROS has a key role in the zone of stasis in terms of oxidative stress [8, 9].

Notable ROS are superoxide radical (O_2^-), hydrogen peroxide (H_2O_2), and hydroxyl radical (OH). Thermal energy, increased activity of xanthine oxidase and phagocyte-related NADPH oxidase are the causes of oxidative stress after burn [24]. Normally, a cell has defense mechanisms against damaging oxidants and there is a balance between generating and clearing of oxidants. The increase in the account of oxidants causes damage in DNA,

lipids and proteins leading to cell death directly and indirectly. Antioxidants prevent the potential cellular damage resulting from ROS [1]. Cellular redox homeostasis is carefully maintained by an elaborate endogenous antioxidant defense system, which includes endogenous antioxidant enzymes such as SOD, CAT, GPx, glutathione (GSH), proteins, and low molecular-weight scavengers, like uric acid, coenzymeQ, and lipoic acid [25]. The promotion of the activities of SOD, GPx, and CAT may oppose oxidative injury-induced cell death in burn-related trauma [15, 16, 26]. In the present study, a significant increase was noted in SOD, CAT and GPx levels in the ozone-treated groups. CAT and GPx levels were increased in the groups given NAC. Ozone exerts its beneficial effects by decreasing the levels of free oxygen radicals, induction of the local migration of polymorphonuclear leukocytes and promotion of oxygen supply to tissues exposed to injury [27]. Therefore, we can say that ozone exerts this effect by antioxidant defense system enzymes. Sulfhydryl groups in NAC are capable of detoxifying free oxygen radicals and enhancing natural antioxidant capacity by increasing intracellular reduced glutathione concentration. Attributed to the effects of thiol group and nitric oxide, NAC may diminish the formation of nitrite and peroxyxynitrite [28, 29]. Also, MDA formates at the end of the lipid peroxidation and known as an acceptable

marker of oxidative injury-induced cell death [17]. In this study, a significant decrease was observed in MDA levels in the NAC and ozone groups. Therefore, it can be said that these agents are effective in saving the stasis area.

Our study demonstrated that the necrosis of the zone of stasis was saved by NAC and Ozone in group II and group III following the sacrificing the animals on the 10th day. These beneficial effects of NAC and Ozone can be due to the mechanism of NAC which is known to act against kidney, liver, lung failures in septic shock which may be caused by a burn or the drugs [12] whereas Ozone's role in the immunoregulation by increasing the number of leukocytes, enhances the phagocytic capacity of granulocytes, facilitates the formation of monocytes and activates T cells. Moreover, Ozone boosts the release of cytokines such as interferon and interleukin triggering antibody-dependent cellular cytotoxicity [14]. The superiority of Ozone over NAC may be due to this immunoregulatory effect.

In conclusion, the decrease in thermal injury width with using NAC and Ozone were shown in the current experimental animal study. Ozone therapy seems as if it's superior to NAC. These findings may suggest that NAC and Ozone treatment will be acceptable alternatives for other studies.

Conflict of interest: The authors declare no competing interests.

References

- Parihar A, Parihar MS, Milner S, Bhat S. Oxidative stress and anti-oxidative mobilization in burn injury. *Burns* 2008;34:6-17. <https://doi.org/10.1016/j.burns.2007.04.009>
- Jackson DM. The diagnosis of the depth of burning. *Br J Surg* 1953;40:588-596. <https://doi.org/10.1002/bjs.18004016413>
- Tunali T, Sener G, Yarat A, Emekli N. Melatonin reduces oxidative damage to skin and normalizes blood coagulation in a rat model of thermal injury. *Life Sci* 2005;76:1259-1265. <https://doi.org/10.1016/j.lfs.2004.08.024>
- Vorauer Uhl K, Fürnschliel E, Wagner A, Ferko B, Katinger H. Reepithelialization of experimental scalds effected by topically applied superoxide dismutase: controlled animal studies. *Wound Repair Regen* 2002;10:366-371. <https://doi.org/10.1046/j.1524-475X.2002.t01-1-10605.x>
- Kaufman T, Neuman RA, Weinberg A. Is post burn dermal ischemia enhanced by oxygen free radicals? *Burns* 1989;15:291-294. [https://doi.org/10.1016/0305-4179\(89\)90004-1](https://doi.org/10.1016/0305-4179(89)90004-1)
- Choi M, Ehrlich HP. U75412E, a lazaroid, prevents progressive burn ischemia in a rat burn model. *Am J Pathol* 1993;142:519-528. Available at: <https://www.ncbi.nlm.nih.gov/pmc/articles/PMC1886741/pdf/amjpathol00074-0169.pdf?tool=EBI>. Accessed Feb 01, 1993
- Işık S, Şahin Ü, İlğan S, Güler M, Günalp B, Selmanpakoğlu N. Saving the zone of stasis in burns with recombinant tissue-type plasminogen activator (r-tPA): an experimental study in rats. *Burns* 1998;24:217-223. [https://doi.org/10.1016/S0305-4179\(97\)00116-2](https://doi.org/10.1016/S0305-4179(97)00116-2)
- Deniz M, Borman H, Seyhan T, Haberal M. An effective antioxidant drug on prevention of the necrosis of zone of stasis: N-acetylcysteine. *Burns* 2013;39:320-325. <https://doi.org/10.1016/j.burns.2012.06.015>
- Nguyen TT, Cox CS, Traber DL, et al. Free radical activity and loss of plasma antioxidants, vitamin E, and sulfhydryl groups in patients with burns: the 1993 Moyer Award. *J Burn Care Rehabil* 1993;14:602-609. <https://doi.org/10.1097/00004630-199311000-00004>
- Ozturk O, Eroglu HA, Ustebay S, Kuzucu M, Adali Y. An experimental study on the preventive effects of N-acetyl cysteine and ozone treatment against contrast-induced nephropathy. *Acta Cir Bras* 2018;33:508-517. <http://dx.doi.org/10.1590/s0102-865020180060000005>
- Ritter C, Andrades ME, Reinke A, Menna Barreto S, Moreira JCF, Dal Pizzol F. Treatment with N-acetylcysteine plus deferoxamine protects rats against oxidative stress and improves survival in sepsis. *Critl Care Med* 2004;32:342-349. <https://doi.org/10.1097/01.CCM.0000109454.13145.CA>
- Gürer A, Ozdoğan M, Gökakin AK, et al. Tissue oxidative stress level and remote organ injury in two-hit trauma model of sequential burn injury and peritoneal sepsis are attenuated with N-acetylcysteine treatment in rats. *Turk J Trau Emerg Surg TJTES* 2009;15:1-6. Available at: <https://europepmc.org/article/med/19130331>. Accessed Jan 01, 2009
- Travagli V, Zanardi I, Valacchi G, Bocci V. Ozone and ozonated oils in skin diseases: a review. *Mediators Inflamm* 2010;2010:1-9. <https://doi.org/10.1155/2010/610418>
- Zeng J, Lu J. Mechanisms of action involved in ozone-therapy in skin diseases. *Int Immunopharmacol* 2018;56:235-241. <https://doi.org/10.1016/j.intimp.2018.01.040>
- Thérond P, Bonnefont Rousselot D, Davit Spraul A, Conti M, Legrand A. Biomarkers of oxidative stress: an analytical approach. *Curr Opin Clin Nutr Metab Care* 2000;3:373-384. <https://doi.org/10.1097/00075197-200009000-00009>

16. Gökakın AK, Atabey M, Devenci K, et al. The effects of sildenafil in liver and kidney injury in a rat model of severe scald burn: a biochemical and histopathological study. *Ulus Travma Acil Cerrahi Derg* 2014;20:319-327. <https://doi.org/10.5505/tjtes.2014.39586>
17. Regas FC, Ehrlich HP. Elucidating the vascular response to burns with a new rat model. *J Trauma* 1992;32:557-563. <https://doi.org/10.1097/00005373-199205000-00004>
18. Stevenson JM, Gamelli RL, Shankar R. A mouse model of burn wounding and sepsis. *Methods Mol Med* 2003;78:95-105. <https://doi.org/10.1385/1-59259-332-1:95>
19. Nishikimi M, Rao NA, Yagi K. The occurrence of superoxide anion in the reaction of reduced phenazine methosulfate and molecular oxygen. *Biochem Biophys Res Commun* 1972;46:849-854. [https://doi.org/10.1016/s0006-291x\(72\)80218-3](https://doi.org/10.1016/s0006-291x(72)80218-3)
20. Aebi H. Catalase in vitro. *Meth Enzymol* 1984;105:121-126. [https://doi.org/10.1016/S0076-6879\(84\)05016-3](https://doi.org/10.1016/S0076-6879(84)05016-3)
21. Paglia DE, Valentine WN. Studies on the quantitative and qualitative characterization of erythrocyte glutathione peroxidase. *J Lab Clin Med* 1967;70:158-169. <https://doi.org/10.5555/uri:pii:0022214367900765>
22. Singer AJ, McClain SA, Taira BR, Guerriero JL, Zong W. Apoptosis and necrosis in the ischemic zone adjacent to third degree burns. *Acad Emerg Med* 2008;15:549-554. <https://doi.org/10.1111/j.1553-2712.2008.00115.x>
23. Godar DE. Preprogrammed and programmed cell death mechanisms of apoptosis: UV-induced immediate and delayed apoptosis. *Photochem Photobiol* 1996;63:825-830. <https://doi.org/10.1111/j.1751-1097.1996.tb09638.x>
24. Shupp JW, Nasabzadeh TJ, Rosenthal DS, Jordan MH, Fidler P, Jeng JC. A review of the local pathophysiologic bases of burn wound progression. *J Burn Care Res* 2010;31:849-873. <https://doi.org/10.1097/BCR.0b013e3181f93571>
25. Halliwell, B. Free radicals and antioxidants—quod vadis? *Trends Pharmacol Sci* 2011;32:125-130. <https://doi.org/10.1016/j.tips.2010.12.002>
26. Lubos E, Loscalzo J, Handy DE. Glutathione peroxidase-1 in health and disease: from molecular mechanisms to therapeutic opportunities. *Antioxid Redox Signal* 2011;15:1957-1997. <https://doi.org/10.1089/ars.2010.3586>
27. Chen H, Xing B, Liu X, et al. Ozone oxidative preconditioning inhibits inflammation and apoptosis in a rat model of renal ischemia/reperfusion injury. *Eur J Pharmacol* 2008;581:306-314. <https://doi.org/10.1016/j.ejphar.2007.11.050>
28. Demir M, Kutlucan A, Akin H, Aydin O, Sezer T. Comparison of different agents on radiographic contrast agent induced nephropathy. *Eur J Gen Med* 2008;5:222-227. <https://doi.org/10.29333/ejgm/82611>
29. Diaz Sandoval LJ, Kosowsky BD, Losordo DW. Acetylcysteine to prevent angiography-related renal tissue injury (the apart trial). *Am J Cardiol* 2002;89:356-358. [https://doi.org/10.1016/S0002-9149\(01\)02243-3](https://doi.org/10.1016/S0002-9149(01)02243-3)

Acknowledgments: We would like to thank Dr. Ziyne Cinar for her support for the statistical analysis. In addition, Histopathological examinations made by Dr. Mehmet Tuzcu. Thank you to him.

Ethics committee approval: Our institute's Ethics Committee approved the study (Sivas Cumhuriyet University, Animal Ethics Committee; date: 01.03.2018; number: 65202830-050.04.04-150).

Contributions of the authors to the article

M.A. and M.E.B. set up the main idea and hypothesis of the study. M.R.A. developed the theory and edited the material method section. A.T. made the evaluation of the data in the results section. The discussion part of the article was written by M.A., M.R.A., M.E.B. and A.T., M.A. reviewed, made necessary corrections and approved. In addition, all authors discussed the entire study and approved its final version.