

Definition of sustentacular screw length based on computed tomography measurements for calcaneus intraarticular fracture surgery

KALKANEUS İNTRAARTİKÜLER KIRIK CERRAHİ TEDAVİSİNDE BİLGİSAYARLI TOMOGRAFİ ÜZERİNDEN SUSTENTAKULER VİDA UZUNLUĞUNUN BELİRLENMESİ

 Can Doruk BASA¹,  Emre SARIEKİZ¹,  İsmail Eralp KAÇMAZ¹,  Ali ER²,  Vadym ZHAMİLOV¹,  Ali REİSOĞLU¹,  Oğuzhan EKİZOĞLU³

¹Sağlık Bilimleri Üniversitesi, Tepecik Eğitim ve Araştırma Hastanesi, Ortopedi ve Travmatoloji Kliniği, İzmir, Türkiye

²Sağlık Bilimleri Üniversitesi, Tepecik Eğitim ve Araştırma Hastanesi, Radyoloji Kliniği, İzmir, Türkiye

³Sağlık Bilimleri Üniversitesi, Tepecik Eğitim ve Araştırma Hastanesi, Adli Tıp, İzmir, Türkiye

ABSTRACT

Objective: It was aimed to define radiologically the length of the sustentacular screw for guidance of calcaneus intraarticular fracture surgery.

Materials and Methods: In this radiological measurement study, computed tomography (CT) images of 200 (100 males, 100 females) patients who underwent multidetector lower extremity CT were investigated. CT axial sections were subjected to coronal and sagittal multiplanar reconstruction. The longest calcaneal diameters in the axial, sagittal, and coronal planes were measured. The distance between the standardized entry point of the screw on the lateral wall of calcaneus and the sustentaculum tali was measured.

Results: Mean age was 42.31 ± 13.64 years (minimum, 18 years; maximum, 82 years). The distance from the determined point on the lateral wall to the sustentaculum tali (LSA) was measured along the axial plane and was 46.08 ± 4.34 mm in males and 41.37 ± 2.97 mm in females. The distance between the lateral wall and the sustentaculum tali (LSC) in the coronal plane was 50.15 ± 3.89 mm in males and 43.65 ± 3.50 mm in females.

Conclusion: If mean community values are available, evaluation of screw length and calcaneal morphometry using preoperative images will enhance surgical success.

Keywords: calcaneus, sustentacular screw, morphometry, population, trauma

ÖZ

Amaç: Çalışmada kalkaneus intraartiküler kırıkları cerrahisinde kullanılan sustentakuler vidanın boyunun radyolojik olarak belirlenmesi amaçlanmıştır.

Gereç ve Yöntem: Bu radyolojik ölçüm çalışmasına, alt ekstremitte bilgisayarlı tomografisi (BT) çekilmiş olan 200 hasta (100 erkek, 100 kadın) dâhil edildi. Aksiyel BT kesitleri görüntüleri, koronal ve saggital multiplanar rekonstrükte edildi. Kalkanusun aksiyel, koronal ve saggital plandaki en uzun mesafesi ölçüldü. Ayrıca sustentakulum talinin en çıkıntılı noktası ile standardize edilmiş

Can Doruk BASA

Sağlık Bilimleri Üniversitesi, Tepecik Eğitim ve Araştırma Hastanesi, Ortopedi ve Travmatoloji Kliniği, İzmir

 <https://orcid.org/0000-0003-1300-7685>

noktası ile standardize edilmiş kalkaneus lateral duvarındaki nokta arasındaki mesafe koronal ve aksiyel planda ölçüldü.

Bulgular: Ölçüm yapılan BT'lerin ait olduğu kişilerin ortalama yaşı 42,31±13,64 (minimum, 18; maksimum, 82) idi. Aksiyel planda kalkaneustaki vidanın giriş yerine ait olan lateral duvar noktası ile sustentakulum tali arasındaki mesafe (LSA) erkeklerde 46,08±4,34 mm ve kadınlarda 41,37±2,97 mm idi. Koronal planda kalkaneustaki vidanın giriş yerine ait olan lateral duvar noktası ile sustentakulum tali arasındaki mesafe (LSC) erkeklerde 50,15±3,89 mm ve kadınlarda 43,65±3,50 mm idi.

Sonuç: Topluma ait ortalama ölçümlerin bilinmesi durumunda, ameliyat öncesi yapılacak ölçümlerle birlikte hesaplanacak sustentakuler vida uzunluğu ve morfometrik ölçümler cerrahinin başarısını arttıracaktır.

Anahtar Sözcükler: kalkaneus, sustentakuler vida, morfometri, popülasyon, travma

Calcaneal fractures constitute 1–4% of all adult bone fractures (1, 2). Both conservative and surgical treatments are available. The surgical treatments include percutaneous screwing, pin fixation, and open reduction osteosynthesis with plates and screws; all have their advantages and disadvantages (3). Conservative treatment can be applied in non-displaced fractures or in patients with comorbidity, in selected cases with smoking (4, 5).

Although open reduction and plate osteosynthesis via a lateral approach is commonly employed, percutaneous fixations may be more appropriate give the frequent skin complications (6, 7). The aims of surgery are to preserve calcaneal length, correct any hind leg varus and the Böhler angle, and reduce the subtalar joint (2). Although optimal reduction is impossible when the fracture fragments are very small, the best possible reduction is the principal goal.

As the quality of fracture reduction increases over time, so do the clinical success rates. An important indicator of fixation reliability and adequacy after reduction is the stabilization of the medial fragment (8). Such fixation is usually achieved using one or two screws running laterally to the sustentaculum tali. The screws can be delivered from the plate or the lateral wall. The sustentaculum tali is very small; this fact, combined with the complex three-dimensional structure of the calcaneus, means that laterally applied screws do not always adequately engage the sustentaculum tali (8, 9).

The placement of sustentacular screws is rather challenging. One problem is possible screw penetration of the subtalar joint (10). Another problem is irritation of medial structures by long screws that penetrate the sustentaculum tali. In such a case, fracture reduction is indeed stable, but the medial anatomical structures are irritated. It is not always possible to evaluate medial penetration during surgery (11).

The calcaneus bone exhibits a complex structure. Morphological and morphometric between-sex differences in various populations have been reported. Forensic anthropological evaluations facilitate sex assessments. In previous studies, the morphometric between-sex calcaneal data differed by >90% (12-14). A Turkish study found that calcaneal morphometric values varied by 96–100% between sexes (15).

It was aimed to radiological definition the length of the sustentacular screw in order to guidance of calcaneus intraarticular fracture surgery.

MATERIALS AND METHODS

This study is radiological in nature. Computed tomography (CT) angiography images of 200 patients who underwent multidetector lower extremity CT in our institution from January 2015 to January 2019 were reviewed retrospectively to determine the sustentacular screw length. Patients were referred for lower extremity CT angiography because of peripheral vascular pathology. CT was performed on the left, lower extremities of 100 males

and 100 females aged ≥ 18 years. Patients with foot and ankle fractures or deformities, those who had previously undergone surgery, and those with osteomyelitis were excluded. The age and sex of each patient was recorded.

CT was performed using a 128-slice CT scanner (SOMATOM Definition Edge, Siemens Healthcare, Erlangen, Germany). Scan parameters were 100 kV, 208 mA, section thickness 1 mm, and reconstruction interval 0.6 mm.

All data were transferred from the archive to a workstation (Aquarius workstation, TeraRecon, San Mateo, CA, USA) via internal network connections, providing MPR images. All measurements were performed by one orthopedic surgeon with 10 years of experience and one radiologist with experience in musculoskeletal radiology.

CT axial sections were subjected to coronal and sagittal multiplanar reconstruction (MPR). The longest calcaneal diameters in the axial, sagittal, and coronal planes were measured. The screw entry site determined by Olexa et al. (16) was marked in coronal and axial planes. The distance between the determined point and the sustentaculum tali was measured (Figure 1 a, b).

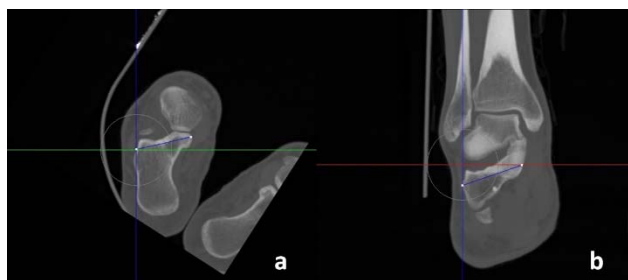


Figure 1a-b. Distance between lateral wall and sustentaculum tali in axial plane CT (LSA) (a) Distance between lateral wall and sustentaculum tali in corone plane CT (LSC) (b)

Statistical Package for the Social Sciences (ver. 17, SPSS Inc., Chicago, IL) software was used for all statistical analyses, and $p < 0.05$ was considered to denote statistical significance. Between-sex continuous variables were compared using the Student's *t*-test.

The protocol for collecting the CTA images of human subjects was approved by the İzmir Tepecik Training and Research Hospital Clinical Research Ethics Committee (08.05.2019/8-2) and the study was conducted in accordance with the standards of the Declaration of Helsinki (Finland).

RESULTS

We evaluated 100 male and 100 female patients with mean age 42.31 ± 13.64 years (minimum, 18 years; maximum, 82 years). The maximum calcaneal length along the axial plane (CA) was 43.55 ± 3.54 mm in males and 39.33 ± 3.11 mm in females. The maximum calcaneal length along the sagittal plane (CS) was 79.68 ± 5.27 mm in males and 71.61 ± 5.27 mm in females. The maximum calcaneal length along the coronal plane (CC) was 46.35 ± 3.40 mm in males and 40.78 ± 3.46 mm in females (Table 1).

Table 1. Maximum lengths of calcaneus in axial, sagittal and coronal multiplanar reconstruction views on CT.

Calcaneus Axial (CA)	Male	43.55 ± 3.54 mm
	Female	39.33 ± 3.11 mm
Calcaneus Sagittal (CS)	Male	79.68 ± 5.27 mm
	Female	71.61 ± 5.27 mm
Calcaneus Coronal (CC)	Male	46.35 ± 3.40 mm
	Female	40.78 ± 3.46 mm

The distance from the determined point on the lateral wall to the sustentaculum tali (LSA) was measured along the axial plane and was 46.08 ± 4.34 mm in males and 41.37 ± 2.97 mm in females. The distance between the lateral wall and the sustentaculum tali (LSC) in the coronal plane was 50.15 ± 3.89 mm in males and 43.65 ± 3.50 mm in females. We sought correlations between the CA and LSA data. A significantly high correlation was apparent ($r=0.806$; $p=0.000$). We examined the relationships between LSA and CC, as well as LSA and CS. Both LSA and CC as well as LSA and CS were significantly and moderately correlated ($r = 0.631$ and 0.539 , respectively; both $p = 0.000$). We also examined the relationship between CA and LSC. Both measures were moderately correlated ($r = 0.677$; $p = 0.000$). CS and LSC were moderately correlated ($r = 0.610$; $p = 0.000$), whereas CC and LSC were highly correlated ($p =$

0.910 and 0.000, within and between sexes, respectively) (Table 2). CA and LSA were significantly associated ($p = 0.000$; t-test), as were CS and LSA ($p = 0.000$). Conversely, CC and LSA were not significantly associated ($p = 0.551$).

Table 2. Correlations of LSC and LSA measurements with CC, CA and CS measurements.

		CA	CS	CC
LSA	Correlation coefficient	0.806	0.539	0.631
	Significance	0.000	0.000	0.000
LSC	Correlation coefficient	0.677	0.610	0.910
	Significance	0.000	0.000	0.000

CA: calcaneus axial; CS: calcaneus sagittal; CS: calcaneus coronal; LSA: distance between lateral wall and sustentaculum tali in axial plane; LSC: distance between the lateral wall and sustentaculum tali in coronal plane

DISCUSSION

Open reduction and internal fixation are frequently used to treat calcaneal fractures. Reduction quality greatly affects the long-term clinical outcomes (3). If the lateral approach that is frequently used to repair displaced articular calcaneal fractures is employed, appropriate sustentacular screw positioning during reduction of the subtalar joint is very important in terms of reduction continuity and stability (9, 17). Several guides for appropriate screw orientation have been published but are not often used (18, 19). It is essential to know the anatomy and morphometry of calcaneus to ensure that the sustentaculum tali is aimed well by screws (20). Even experienced surgeons may orient screws inappropriately. An understanding of morphometric values and within-population variations thus decreases the chances of errors. Hence, we seek to guide surgeons here by reporting the coronal and axial plane distances between the lateral cortex and the sustentaculum tali in a Turkish population.

At present, suggested mean sustentacular lengths for the treatment of calcaneal fractures are not unavailable in the literature. As such, our present Turkish data are useful. The mean LSA was 46.08 ± 4.34 mm in males and 41.37 ± 2.97 mm in females, and the mean LSC was 50.15 ± 3.89 mm in males and 43.65 ± 3.50 mm in females. Surgeons

should consider these measurements; if the screw chosen after drilling is too short, it will not engage with the sustentaculum tali, and reduction stability will be poor. If the screw is too long, the fracture will be inadequately reduced, or the screw will penetrate the bone and irritate the medial structures.

We measured the maximum axial, coronal, and sagittal lengths of the calcaneus. The relationships between these measurements and the axial plane distance between the lateral wall and the most medial part of the sustentaculum tali were analyzed. CS and CA were significantly associated with LSA and LCA, whereas CC did not exhibit significant associations with these lengths. Thus, morphometrically, coronal plan measurements do not yield correct sagittal and axial calcaneal lengths. Therefore, preoperative morphometric evaluations should be used to determine the optimal surgical method.

Our work had certain limitations. All measurements were taken using calcaneal CT scans of patients who lacked fracture and operation histories. In addition, all measurements were made on MPR-reconstructed images. As measurements were not 3D reconstructed views, we could not measure angle between axis of calcaneus and screw. As patients operated upon to treat calcaneal fractures included sustentaculum tali were not included, we could not explore the relationship between reduction quality and screw length.

We examined calcaneal morphometry from an orthopedic surgical perspective to predict the optimal lengths of sustentacular screws for Turkish patients. If mean community values are available, evaluation of screw length and calcaneal morphometry using preoperative images will enhance surgical success.

REFERENCES

1. Epstein N, Chandran S, Chou L. Current concepts review: intra-articular fractures of the calcaneus. *Foot Ankle Int.* 2012;33:79-86.
2. Wei N, Zhou Y, Chang W, Zhang Y, Chen W. Displaced Intra-articular Calcaneal Fractures: Classification and Treatment. *Orthopedics.* 2017;40:e921-9.

3. Buckley R, Tough S, McCormack R, et al. Operative compared with nonoperative treatment of displaced intra-articular calcaneal fractures: a prospective, randomized, controlled multicenter trial. *J Bone Joint Surg Am.* 2002;84:1733-44.
4. Lim EV, Leung JP. Complications of intraarticular calcaneal fractures. *Clin Orthop Relat Res.* 2001;7-16.
5. Schepers T, van Lieshout EM, van Ginhoven TM, Heetveld MJ, Patka P. Current concepts in the treatment of intra-articular calcaneal fractures: results of a nationwide survey. *Int Orthop.* 2008;32:711-15.
6. Fan B, Zhou X, Wei Z, Ren Y, Lin W, Hao Y, et al. Cannulated screw fixation and plate fixation for displaced intra-articular calcaneus fracture: A meta-analysis of randomized controlled trials. *Int J Surg.* 2016;34:64-72.
7. Tantavisut S, Phisitkul P, Westerlind BO, Gao Y, Karam MD, Marsh JL. Percutaneous Reduction and Screw Fixation of Displaced Intra-articular Fractures of the Calcaneus. *Foot Ankle Int.* 2017;38:367-74.
8. Gitajn IL, Abousayed M, Toussaint RJ, Ting B, Jin J, Kwon JY. Anatomic Alignment and Integrity of the Sustentaculum Tali in Intra-Articular Calcaneal Fractures: Is the Sustentaculum Tali Truly Constant? *J Bone Joint Surg Am.* 2014;96:1000-5.
9. Bussewitz BW, Hyer CF. Screw placement relative to the calcaneal fracture constant fragment: an anatomic study. *J Foot Ankle Surg.* 2015;54:392-4.
10. Yu X, Pang QJ, Chen L, Yang CC, Chen XJ. Postoperative complications after closed calcaneus fracture treated by open reduction and internal fixation: a review. *J Int Med Res.* 2014;42:17-25.
11. Albert MJ, Waggoner SM, Smith JW. Internal fixation of calcaneus fractures: an anatomical study of structures at risk. *J Orthop Trauma.* 1995;9:107-12.
12. Bidmos MA, Asala SA. Discriminant function sexing of the calcaneus of the South African whites. *J Forensic Sci.* 2003;48:1213-8.
13. Gualdi-Russo E. Sex determination from the talus and calcaneus measurements. *Forensic Sci Int.* 2007;171:151-6.
14. Kim DI, Kim YS, Lee UY, Han SH. Sex determination from calcaneus in Korean using discriminant analysis. *Forensic Sci Int.* 2013;228:177.e1-7.
15. Ekizoglu O, Inci E, Palabiyik FB, Can İO, Er A, Bozdog M, et al. Sex estimation in a contemporary Turkish population based on CT scans of the calcaneus. *Forensic Sci Int.* 2017;279: 310.e1-310.e6.
16. Olexa TA, Ebraheim NA, Haman SP. The sustentaculum tali: anatomic, radiographic, and surgical considerations. *Foot Ankle Int.* 2000;2:400-3.
17. Tomesen T, Biert J, Frolke JP. Treatment of displaced intra-articular calcaneal fractures with closed reduction and percutaneous screw fixation. *J Bone Joint Surg Am.* 2011;93:920-8.
18. Gras F, Marintschev I, Wilharm A, Lindler R, Klos K, Mückley T, et al. [Sustentaculum tali screw placement for calcaneus fractures--different navigation procedures compared to the conventional technique]. *Z Orthop Unfall.* 2010;148:309-18.
19. Wang Z, Wang XH, Li SL, Tang X, Fu BG, Wang MH, et al. Minimally invasive (sinus tarsi) approach for calcaneal fractures. *J Orthop Surg Res.* 2016;11:164.
20. Wang C, Huang D, Ma X, Wang X, Huang J, Zhang C, et al. Sustentacular screw placement with guidance during ORIF of calcaneal fracture: an anatomical specimen study. *J Orthop Surg Res.* 2017;12:78.