

In situ transverse osteotomy and locked mini plate for the correction of metacarpal rotational deformity

Levent Adıyeke¹, Birkan Kibar²

¹Department of Orthopaedics and Traumatology, Haydarpaşa Numune Training and Research Hospital, İstanbul, Turkey; ²Department of Orthopaedics and Traumatology Hand Surgery, Haydarpaşa Numune Training and Research Hospital, İstanbul, Turkey

ABSTRACT

Objectives: We aimed to investigate the radiological and clinical results of transverse osteotomy and fixation applications in rotation deformities due to metacarpal malunion.

Methods: A total of 18 fingers from 18 patients were enrolled in the study (14 males and 4 females). The average age of the patients was 32.8 ± 14.4 years (range: 18-58 years). The average follow-up duration was 19.7 ± 7.9 months (range: 7-36 months). All patients had a scissoring deformity which affected their daily activities or caused cosmetic problems.

Results: In all patients, the scissoring and overlapping deformities improved and in all osteotomies union was achieved. A total range of motion for the DIP, PIP, MP and wrist joints was achieved in all patients. The average DASH score was 5.2 ± 5.6 (range: 0-21.7), and the average VAS score was 0.8 ± 0.9 (range: 0-3). The average grip strength was 40.5 ± 10.2 kg (range: 19-55 kg) and 94% of the healthy side. There was no statistically significant difference in grip strength compared to the healthy side ($p = 0.23$). Fourteen excellent and 4 good scores were obtained based on Büchler criteria.

Conclusions: In situ transverse osteotomy and the locked miniplate method is effective and feasible in the treatment of metacarpal malunions with finger rotational deformities, given their ease of use, allowance of early movement, high union rates, and good results.

Keywords: Finger, rotational deformity, osteotomy, transverse, malunion

Rotation deformity may occur in the fingers due to incorrectly united phalanx and metacarpal fractures, especially spiral and oblique fractures [1]. This can result in the scissoring finding of the fingers, pain and stiffness due to joint line rotation, impaired soft tissue balance, and reduced grip strength [2]. It is necessary to correct the functional and aesthetic problems caused by the deformity with surgical treatment. It is difficult to view the original fracture line in late cases, so an osteotomy is required [3]. A transverse, step-cut, or modified step-cut osteotomy can be performed on

the affected bone or metacarpus [3-5]. Osteosynthesis options include intraosseous wires, Kirschner (K) wires, plates, and screws [6].

Treatment of visual and physical defects in metacarpal rotation deformity increases the comfort of life of the patient. We employed a transverse metacarpal osteotomy and a locked miniplate on the affected metacarpal to treat finger rotation deformities caused by metacarpal malunions. In this study evaluated the clinical and radiological results of transverse osteotomy and fixation applications in rotation defor-

Received: February 14, 2021; Accepted: May 4, 2021; Published Online: January 25, 2022



How to cite this article: Adıyeke L, Kibar B. In situ transverse osteotomy and locked mini plate for the correction of metacarpal rotational deformity. Eur Res J 2022;8(4):428-433. DOI: 10.18621/eurj.879908

Address for correspondence: Levent Adıyeke, MD., Haydarpaşa Numune Training and Research Hospital, Department of Orthopaedics and Traumatology, Tıbbiye Street, Selimiye District, No:23, 34668, İstanbul, Turkey. E-mail: leventadiyeke@gmail.com, Tel (Mobil): +90 505 759 24 89, Tel (Office): +90 216 542 32 32

©Copyright © 2022 by Prusa Medical Publishing
Available at <http://dergipark.org.tr/eurj>

mities due to metacarpal malunion. Compared to studies in the literature evaluating osteotomy only in metacarpal malunions, the number of our cases is higher in this study.

METHODS

Adult patients who received an in-situ transverse metacarpal osteotomy and a locked miniplate to treat a finger rotation deformity caused by metacarpal malunions between 2015 and 2019 were evaluated retrospectively. Patients for whom at least one year of follow-up data were available were spoken to by phone, and those who responded to the last control call were considered for the study. The medical reports of these patients were reviewed, and those with incomplete metacarpal callus maturation, additional injuries in the ipsilateral extremity, previously undergone surgery on the same hand, presence metacarpal angulation and shortness were excluded. This study was approved by the institutional review board of Haydarpaşa Numune Training and Research Hospital (HNEAH-KAEK2020/KK/192), verbal and written informed consent was obtained from all patients.

Except for three patients who could not be reached, 18 fingers of 18 patients (14 males and 4 females) who met the criteria were enrolled in the study. The mean age of the patients was 32.8 ± 14.4 years (range: 18-58 years). All patients had a scissoring deformity which affected their daily activities or caused cosmetic problems, thus surgical treatment was employed. In addition, five patients complained of pain. The cause of the rotation deformity in all patients was a malunited metacarpal fracture; 14 patients had been treated with a closed reduction and plaster splint, while 4 patients had received no treatment. The average interval between the injury and surgery was 11.2 ± 7.3 months (range: 4-30 months). The fracture pattern could not be assessed clearly for all patients because the original fracture line could not be completely distinguished. None of the patients had vascular, nerve and tendon injuries before surgery. The fracture line was closed in all patients and there were no pathological fractures. Bone maturation was complete in all patients during injury.

A transverse osteotomy and a locked miniplate were used to treat the metacarpals of the patients. All

patients received 1 g of cefazolin sodium prophylactically 1 hour before surgery and then operated under general anesthesia or axillary block.

Surgical Technique

The patients were placed on the operating table in the supine position and then a 250 mmHg pressure pneumatic tourniquet was applied. A longitudinal incision was made over the metacarpal. The skin and subcutaneous tissue were passed and cutaneous nerves preserved. The extensor tendon was retracted to one side while preserving the paratenon. The carpometacarpal joint was identified using a needle. A straight line was drawn parallel to bone with a marker pen and the axis of the bone was determined. The plate was applied to the bone from dorsal side of the metacarpal bone, with one screw from the most proximal hole used as a single cortex. A transverse line was drawn distal to the 3rd or 4th screw hole to determine the osteotomy line and the plate was removed. A transverse osteotomy was performed perpendicular to the bone (from the previously marked transverse line) using an oscillating saw. The plate was fixed to the proximal fragment with three or four screws. The distal fragment was sufficiently rotated, the longitudinal line was checked, and two of the distal screw holes were temporarily fixed with two K-wires as double cortices. The wrist was extended, and the correction of the deformity was checked based on the tenodesis effect of the flexor tendons, in which the proximal interphalangeal phalanx (PIP) joint was flexed to 90° and the affected finger was observed to be parallel to the other fingers. Sufficient improvement was achieved with only a minor rotation. If the correction was appropriate, screws were applied to the distal fragment; if not, the temporary K-wire was removed, and the correction was made again. The correction was checked using a tenodesis test after placing each screw in the distal fragment. Intraoperative fluoroscopy was employed to confirm the plate placement, screw length, and osteotomy line.

No grafts or extra lag screws were used in any patient, and 2.0-mm fixed angle locked miniplates were used for all patients. Only locking screws were used, with three or four screws (at least six cortices) applied to both sides of the osteotomy line. No splint was applied to any patient after the operation. The correction was checked by making fist to patient immediately

postoperative. On the first day after the operation, active hand and wrist joint movements were started. Extremity elevation and cold compress were used for edema control at the first week. Daily activities such as writing with a pencil, button-up, eating and using cutlery were allowed for the first three weeks. After three weeks, the patients referred the physical therapy department of our hospital, and a hand rehabilitation program was initiated for 1 hour/day and 5 days/week, including Transcutaneous Electrical Nerve Stimulation (TENS) and soft tissue stretching exercises. Physical exercise program were initiated when radiographs confirmed osteotomy healing. The sutures were removed at postoperative second week. In the final follow-up, the range of motion (ROM) for the DIP, PIP and MP joints was measured using a finger goniometer and compared with the healthy side. Using posteroanterior, oblique, and lateral radiographs, union was defined as cortical trabeculation, the formation of a bridging callus, and no sensitivity upon palpation of the osteotomy line. The absence of a bridging callus after six months was evaluated as non-union [7]. In addition, the Disabilities of the Arm, Shoulder, and Hand (DASH) questionnaire and the visual analogue

scale (VAS) were used for functional evaluation and pain assessment [8, 9]. A Saehan hydraulic hand dynamometer was used to measure the patient’s grip strength while sitting with shoulder adduction, an elbow flexion of 90°, and the forearm and wrist in a neutral position. Periodical measurements were made three times and the average was calculated. The grip strength were compared with the healthy side. Büchler criteria were used to evaluate the results (Table 1) [2].

Statistical Analysis

The normality of the parameter distributions was evaluated using the Shapiro–Wilk test, while the Mann-Whitney U test was used to compare parameters between the two groups. $P < 0.05$ was considered statistically significant.

RESULTS

The average interval between surgery and contact via phone was 19.7 ± 7.9 months (range: 7-36 months). The average interval between fracture and surgery time was 7.3 months (range: 3-15). In 11 patients the dominant side was affected. The right side was affected in nine patients and the left side in nine patients. The cause of the injury was a fall for 10 patients, injury during sports activities for three patients, a work accident for two patients, a motor vehicle accident for one patient, punch injury for one patient, and an attack for one patient. The index metacarp was affected in four patients, the middle metacarp in three patients, the ring metacarp in five patients, and the small metacarp in six patients.

In all patients, the scissoring and overlapping deformities improved and in all osteotomies union was achieved. Fig.1. A complete ROM for the distal interphalangeal, proximal interphalangeal, metacarpophalangeal and wrist joints were achieved in all patients. The mean DASH score was 5.2 ± 5.6 (range: 0-21.7), and the mean VAS score was 0.8 ± 0.9 (range: 0-3). The average grip strength was 40.5 ± 10.2 kg (range: 19-55 kg) and 94% of the healthy side. Mean surgery time was 50.5 ± 13.7 minutes (range: 30-75 minutes). When compared with the healthy side, no statistical significant difference was found in terms of grip strength ($p = 0.23$). In total, 14 excellent and 4 good scores were obtained based on Büchler criteria.

Table 1. Criteria and grading of results [2]

Criteria	
1	Complete correction of preoperative deformity
2	Full bony union
3	Patients experiencing no pain
4	Patients has returned to work
5	Patients satisfaction rating good or above
6	No trophic or sensory problems
7	No tendon adhesions
8	ROM to within 10 degrees of full range in each joint
9	Flexion brings finger tip to within 1 cm of palm
Grading	
Excellent	≥ 8 criteria satisfied
Good	7 criteria satisfied
Fair	5 or 6 criteria satisfied
Poor	< 5 criteria satisfied

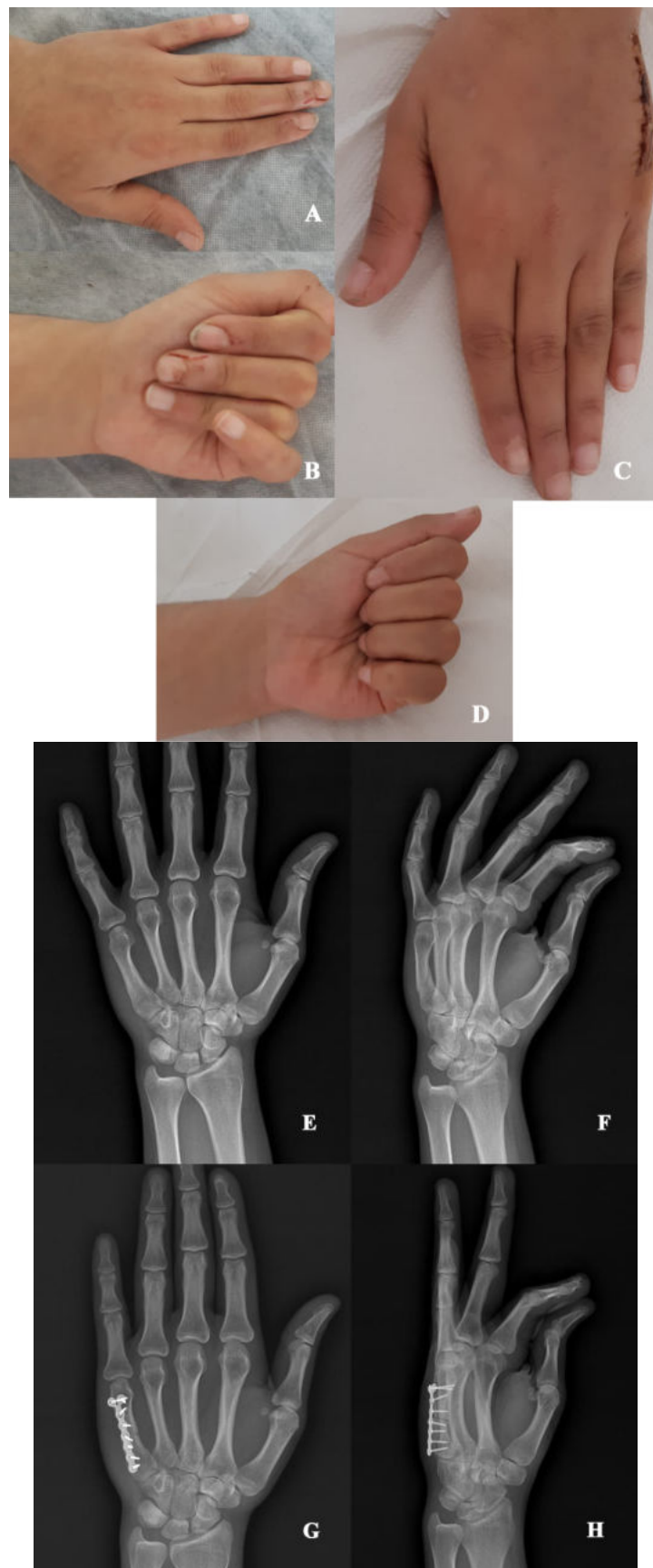


Fig. 1: A-B: Malrotation of the small finger caused scissoring during finger flexion, C-D: postoperative 2. week clinical images after the rotational deformity was corrected, E-F: preoperative and, G-H: postoperative 6. week radiographs of the same patient.

There were no complications such as plate/screw irritation, implant displacement, hardware loosening or loss of correction, and no implant was removed from any patient. In addition, no patient experienced infection, digital nerve injury, or hypertrophic scarring. No secondary surgery was required in any patient. One patient experienced sudeck atrophy syndrome that improved using physical therapy and conservative therapy.

DISCUSSION

While metacarpal and phalangeal fractures are treated conservatively, interphalangeal joints are splinted in extension and the MP joint in flexion. In doing so, any rotation deformity that occurs is not obvious. A scissoring deformity becomes apparent when movement is started and the finger is flexed, and this causes functional and aesthetic problems. If diagnosed late, the fracture will unite and surgical treatment becomes necessary [3].

There is no consensus on the location, type, and fixation method for an osteotomy. There are two osteotomy locations for a finger with rotation deformity; the first is at the site of the malunion and the second is at the metacarpal of the affected ray. Weckesser was the first to report on the treatment of finger rotational deformities in 1965. He described the transverse osteotomy of the metacarpal base for both phalanx and metacarpal malunions and fixation with K-wires, emphasizing the importance of early movement [10].

Gross *et al.* [11] performed basal metacarpal osteotomies on 80 fingers of 40 cadavers, showing that a correction of 18-19° was possible in the index, long, and ring fingers, and a correction of 20-30° was possible in small fingers. It was reported that the deep transverse metacarpal ligament was the limiting factor for rotation. The release of this ligament can cause loss of the transverse palmar arch and instability of the MP joint [11].

Pichora *et al.* [12] performed a step-cut osteotomy on the malunion area of 23 fingers of 18 patients with rotational deformity, of which seven involved the metacarpal and 16 the proximal phalanx. They reported good results and fast union. In the literature review of Lei *et al.* [13], metacarpal corrective osteotomies were performed on nine phalanges and six

metacarpals, and complete recovery was achieved in 13 of the 15 patients (87%), while bony union was obtained in all patients.

Menon *et al.* [14] performed a metacarpal osteotomy on 12 fingers with metacarpal and phalangeal malunion-induced rotational deformities and all pre-operative deformities were corrected. The metacarpal-based osteotomy described by Bindra *et al.* [3] is simple, allows early movement and has few complications. However, this technique is not suitable for fingers with rotational deformities of more than 20° [3]. Jawa *et al.* [4] performed a step-cut osteotomy at the metacarpal shaft level for 12 fingers with rotational deformities and fixed them with lag screws. Seven of these were metacarpal and five were phalanx malunions. They recommended this method due to the advantage of precise intraoperative control, including selecting the osteotomy site, offering a large surface area with bony healing, and making possible rigid fixation with early digital motion [4].

Limitations

The retrospective nature of our study and the absence of a control group are weaknesses of the present study. We preferred in situ osteotomy because exposure of the malunited area allows for more accurate evaluation, intervention in flexor and extensor tendon adhesion, and the potential for further correction. We preferred transverse osteotomy because it is less complicated. We preferred plate fixation for early rehabilitation; we applied at least three screws on both sides of the osteotomy line and did not apply postoperative splints. We achieved a full ROM in the DIP, PIP and MP joints and achieved union in all patients.

CONCLUSION

We believe that in-situ transverse osteotomy and the locked miniplate method is effective and feasible in the treatment of metacarpal malunions with finger rotational deformities, given their ease of use, allowance of early movement, high union rates, and good results.

Authors' Contribution

Study Conception: BK; Study Design: LA; Supervision: LA, BK; Funding: N/A; Materials: LA, BK; Data Collection and/or Processing LA, BK; Statistical

Analysis and/or Data Interpretation: LA; Literature Review: LA; Manuscript Preparation: LA, BK and Critical Review: LA.

Conflict of interest

The authors disclosed no conflict of interest during the preparation or publication of this manuscript.

Financing

The authors disclosed that they did not receive any grant during conduction or writing of this study.

REFERENCES

1. Bloem JJ, Kon M, de Graaf FH. Rotational deformity of the index finger caused by reversed finger sucking. *Ann Plast Surg* 1988;21:597-600.
2. Büchler U, Gupta A, Ruf S. Corrective osteotomy for post-traumatic malunion of the phalanges in the hand. *J Hand Surg Br* 1996;21:33-42.
3. Bindra RR, Burke FD. Metacarpal osteotomy for correction of acquired phalangeal rotational deformity. *J Hand Surg Am* 2009;34:1895-99.
4. Jawa A, Zucchini M, Lauri G, Jupiter J. Modified step-cut osteotomy for metacarpal and phalangeal rotational deformity. *J Hand Surg Am* 2009;34:335-40.
5. Manktelow RT, Mahoney JL. Step osteotomy: a precise rotation osteotomy to correct scissoring deformities of the fingers. *Plast Reconstr Surg* 1981;68:571-6.
6. Gollamudi S, Jones WA. Corrective osteotomy of malunited fractures of phalanges and metacarpals. *J Hand Surg Br* 2000;25:439-41.
7. Kibar B. Hemi-hamate osteochondral autograft for acute dorsal proximal interphalangeal fracture-dislocations. *Eur J Trauma Emerg Surg* 2021;47:825-9.
8. Hudak PL, Amadio PC, Bombardier C. Development of an upper extremity outcome measure: the DASH (disabilities of the arm, shoulder and hand) [corrected]. The Upper Extremity Collaborative Group (UECG). *Am J Ind Med* 1996;29:602-8.
9. Kibar B, Malkoç FE. Reconstruction of chronic thumb metacarpophalangeal radial collateral ligament injuries with free tendon grafts. *Jt Dis Relat Surg* 2020;31:62-7.
10. Weckesser EC. Rotational osteotomy of the metacarpal for overlapping fingers. *J Bone Joint Surg Am* 1965;47:751-6.
11. Gross MS, Gelberman RH. Metacarpal rotational osteotomy. *J Hand Surg Am* 1985;10:105-8.
12. Pichora DR, Meyer R, Masear VR. Rotational step-cut osteotomy for treatment of metacarpal and phalangeal malunion. *J Hand Surg Am* 1991;16:551-5.
13. Van der Lei B, de Jonge J, Robinson PH, Klasen HJ. Correction osteotomies of phalanges and metacarpals for rotational and angular malunion: a long-term follow-up and a review of the literature. *J Trauma* 1993;35:902-8.
14. Menon J. Correction of rotary malunion of the fingers by metacarpal osteotomy. *Orthopedics* 1990;13:197-200.



This is an open access article distributed under the terms of Creative Commons Attribution-NonCommercial-NoDerivatives 4.0 International License.