

Transient Complete Heart Block in a Patient with Bicuspid Aortic Valve: A Case Report

Biküspit Aort Kapaklı Hastada Geçici Kalp Bloğu: Olgu Sunumu

Özlem ARICAN ÖZLÜK, Kemal KARAAĞAÇ, Pınar YAĞCIOĞLU, Mustafa KUZEYTEMİZ,
Muhammed ŞENTÜRK, Tezcan PEKER, Mustafa YILMAZ

Bursa Postgraduate Hospital, Department of Cardiology, Bursa

Geliş Tarihi / Received: 27.08.2012

Kabul Tarihi / Accepted: 01.10.2012

ABSTRACT

Bicuspid aortic valve is a common congenital cardiovascular malformation. We present a case with bicuspid aorta and ascending aortic aneurysm developing transient complete heart block. This case is the first in literature to report the concurrence of bicuspid aortic valve and ascending aortic dilatation with transient complete heart block.

Keywords: Bicuspid aortic valve; atrioventricular block; aortic aneurysm.

ÖZET

Biküspit aort kapak sık görülen doğumsal kardiyovasküler bozukluktur. Sunduğumuz vaka biküspit aort kapak ve çıkan aort anevrizmasında gelişen geçici tam kalp bloğudur. Bu vaka biküspit aort ve çıkan aort genişlemesine geçici kalp bloğunun eşlik ettiği literatürdeki ilk vakadır.

Anahtar Kelimeler: Biküspit aortik kapak; atriyoventriküler blok; aort anevrizması.

INTRODUCTION

Bicuspid aortic valve is a common congenital cardiovascular malformation (1). It may be alone or with concomitant congenital cardiac lesions, most commonly with dilatation of the proximal ascending aorta. This report presents a case with bicuspid aorta and ascending aortic aneurysm developing transient complete heart block.

CASE PRESENTATION

A 53-year-old man presented to the emergency department of our hospital with near syncope and palpitation. He had no similar complaints or known coronary artery disease before. In his first examination, he was confused with a blood pressure of 80/60 mmHg. His first ECG showed complete heart block with a ventricular escape rhythm of 38 bpm. QRS complexes were wide with a right bundle block pattern (Figure I). Complete heart block briefly disappeared with atropine administration. He was transferred to the catheterization room where a temporary pacemaker was inserted via femoral venous route. Shortly thereafter the patient developed complete heart block again and the pacemaker started to pace. His angiogram was normal (Figure II A-B-C). An aortogram to rule out aortic dissection revealed a

markedly dilated ascending aorta (6,1 cm) (Figure 2D).

During hospital stay, other conditions with the potential to cause complete heart block such as electrolyte disorders, drugs, hypertension etc. were excluded. His blood pressure remained within normal limits. On bedside echocardiography, a normal left ventricular systolic function, a bicuspid aortic valve, mild aortic regurgitation, and ascending aortic dilatation were noted. Aortic valve had no marked gradient. A transesophageal echocardiography revealed no aortic dissection but a bicuspid aortic valve and ascending aortic dilatation (Figure III). A joint commission of cardiology and thoracic surgery decided aortic valve replacement and graft insertion for ascending aortic aneurysm. The patient was then transferred to cardiovascular surgery ward. Before operation, a thoracic CT was done in which an ascending aortic aneurysm without dissection was found. The patient underwent aortic valve replacement and ascending aortic grafting. Postoperative ECG showed a trifascicular block (Figure IV). He had no need for pacemaker postoperatively. A pre-discharge holter monitoring showed no advanced AV block or bradycardia, and he was discharged. At first month postoperatively, he had a sinus rhythm with right bundle branch block and a PR interval of 200 ms. He had no presyncope, dizziness or palpitations.

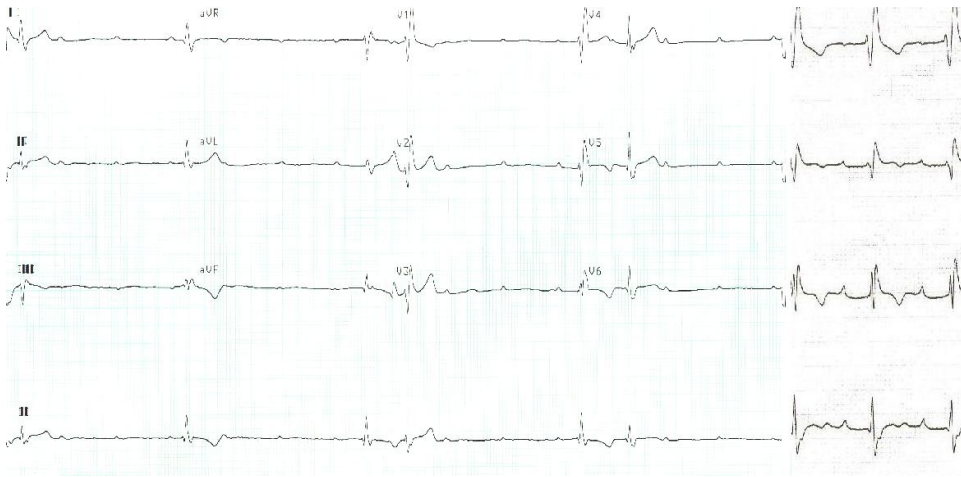


Figure I: Complete heart block in presentation electrocardiography.

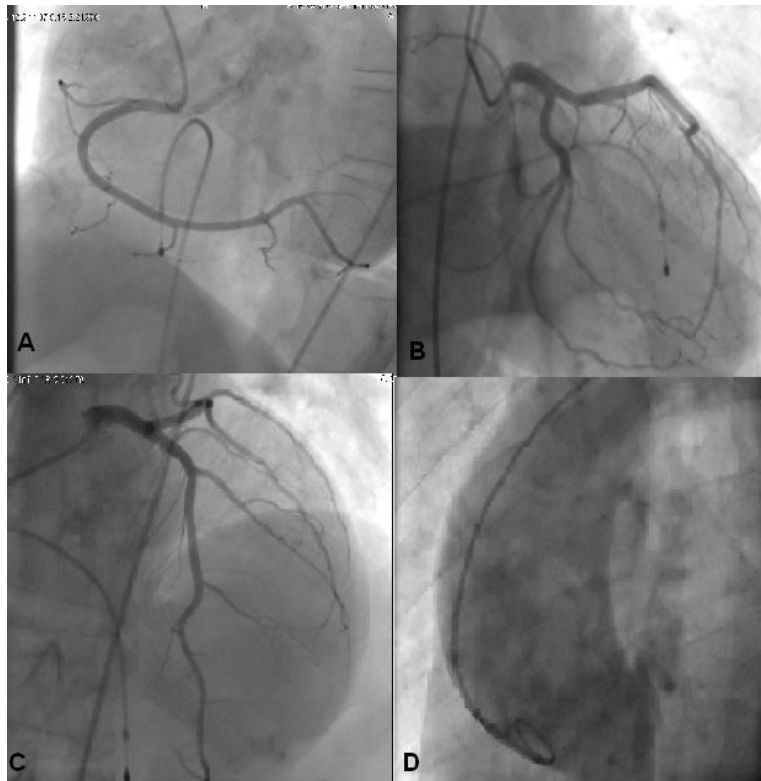


Figure II: A-B-C Normal coronary arteries. D- In aortography a calcification below the aortic valve at the level of interventricular septum is shown.

Transient Complete Heart Block in a Patient with Bicuspid Aortic Valve
Biküspit Aort Kapaklı Hastada Geçici Kalp Bloğu

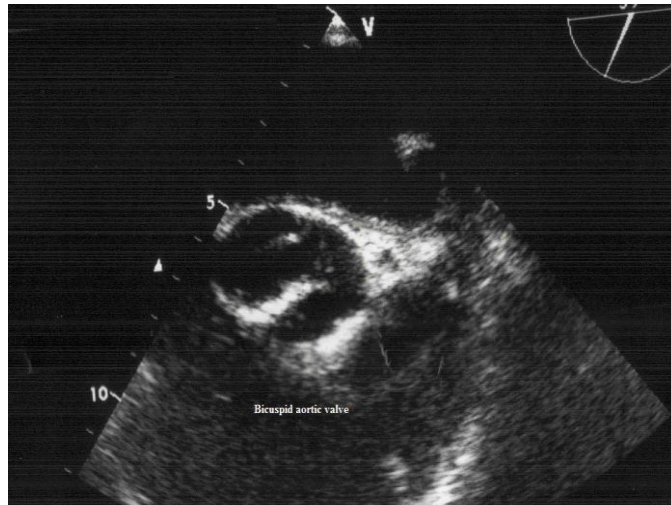


Figure III: Bicuspid aortic valve in transesophageal echocardiography.

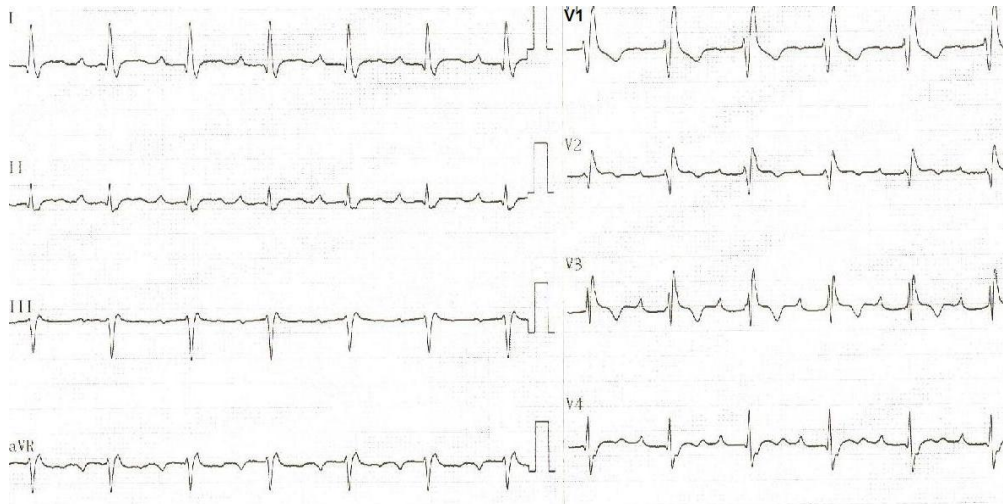


Figure IV: Postoperative ECG showed a trifascicular block (sinus rhythm with 1st degree AV block, right bundle branch block (RBBB), left anterior hemiblock).

DISCUSSION

Bicuspid aortic valve is a common congenital cardiac malformation. On autopsy series, its prevalence has been reported to be 0,9- 2,5 % (1). It is three times more common in males compared to females (2). It is the most common cause of isolated aortic valve stenosis in adults (3). It is frequently accompanied by other congenital aortic and cardiac anomalies, most commonly coarctation of aorta which is found in 6 % of patients with bicuspid aortic valve in autopsy series (1). On the other hand, coarctation patients have a bicuspid aortic valve prevalence of 30- 40 % (4). The

less common concurrences are with ventricular and atrial septal defects, hypoplastic left heart syndrome, patent ductus arteriosus, bicuspid pulmonic valve and Ebstein anomaly (5).

Our patient had an aortic pathology sparing sinus valsalva. It has also been reported that complete heart block may develop in aortic dissection, allegedly by compression of interatrial septum and atrioventricular junction by the hematoma resulting from dissection (6). In literature, there is no cases of

transient complete heart block associated with ascending aortic aneurysm, as in our case.

Aortography in our patient revealed a prominent calcified area beneath the aortic valve at the interventricular septal localization (Figure IV). We know that fibrosis and calcification extending to the neighboring conduction system may cause atrioventricular block. This is the etiologic agent in more than half of all atrioventricular blocks. However, this phenomenon is progressive in nature. In contrast, complete heart block suddenly developed in our patient and did not recur after the operation.

REFERENCES

1. Roberts WC. The congenitally bicuspid aortic valve. A study of 85 autopsy cases. *Am J Cardiol* 1970;26(1):72-83.
2. Roberts WC, Ko JM. Frequency by decades of unicuspid, bicuspid, and tricuspid aortic valves in adults having isolated aortic valve replacement for aortic stenosis, with or without associated aortic regurgitation. *Circulation* 2005;111(7):920-5.
3. Campbell M. Calcific aortic stenosis and congenital bicuspid aortic valves. *Br Heart J* 1968;30(5):606-16.
4. Nihoyannopoulos P, Karas S, Sapsford RN, Hallidie-Smith K, Foale R. Accuracy of two-dimensional echocardiography in the diagnosis of aortic arch obstruction. *J Am Coll Cardiol* 1987;10(5):1072-7.
5. Cripe L, Andelfinger G, Martin LJ, Shooner K, Benson DW. Bicuspid aortic valve is heritable. *J Am Coll Cardiol* 2004;44(1):138-43.
6. Jessen ME, Horn VP, Weaver DE, Boehrer JD, Ring WS. Successful surgical repair of aortic dissection presenting with complete heart block. *Ann Thorac Surg* 1996;62(4):1202-3.