

## INVESTIGATION OF PROTECTIVE EFFECTS OF DIFFERENT DOSES OF OMEGA 3 FATTY ACIDS IN EXPERIMENTAL RENAL ISCHEMIA REPERFUSION DAMAGE

### DENEYSEL BÖBREK İSKEMİ REPERFÜZYON HASARINDA FARKLI DOZLARDAKİ OMEGA 3 YAĞ ASİTLERİNİN KORUYUCU ETKİLERİNİN ARAŞTIRILMASI

Ferhat ŞİRİNİLDİZ<sup>1</sup>, Gökhan CESUR<sup>1</sup>

<sup>1</sup>Department Of Physiology, Aydin Adnan Menderes University Faculty of Medicine, AYDIN

**Cite this article as:** Şirinyıldız F, Cesur G. Investigation of Protective Effects of Different Doses of Omega 3 Fatty Acids in Experimental Renal Ischemia Reperfusion Damage Med J SDU 2021; 28(2): 283-289.

#### Öz

##### Amaç

İskemi reperfüzyon (IR) hasarı, belirli bir organa kan akışının ani ve geçici olarak bozulmasından kaynaklanır. Renal IR kaynaklı böbrek hasarı, yüksek düzeyde kalıcı hasar ve mortaliteye neden olur. Diyet ile alınan omega-3 yağ asitleri, antiinflamatuvar ve immün modüle edici etkilere sahiptir ve koruyucu olarak kullanılmaktadır. Çalışmada; iskemi reperfüzyon hasarında omega-3 yağ asidinin farklı dozlarının koruyucu etkileri biyokimyasal ve histolojik analizler ile incelenmiştir.

##### Gereç ve Yöntem

40 adet erişkin dişi sıçan Düz kontrol, sham kontrol, IR, IR+100, IR+400, IR+700 olmak üzere 5 gruba ayrıldı (n:8). Sham grubunda sağ böbrek nefrektomi ile alındı, sol böbreğe işlem uygulanmadı. I/R hasarına maruz kalan sağ böbrek nefrektomi ile alındı, sol böbreklere ise klemp takıldı. Tedavi gruplarına cerrahi girişimden önceki 14 gün ve operasyon gününün sabahında toplam 15 sefer 100 mg/kg, 400 mg/kg ve 700 mg/kg'lık omega-3 yağ asitleri gastrik gavaj ile verildi.

##### Bulgular

Elde edilen verilere göre; artan dozlardaki omega-3

ile histopatolojik inceleme sonuçları korale şekilde iyileşme tespit edildi. Histopatolojik sonuçlar, biyokimyasal sonuçlar ile desteklendi. Malondialdehit (MDA) ve myeloperoksidaz (MPO) düzeylerinde tedavi uygulanan gruplarda anlamlı düzeyde azalma saptanırken, katalaz (CAT) ve glutatyon peroksidaz (GSH-Px) düzeylerinde artış saptandı.

##### Sonuç

Sonuç olarak; elde edilen bulgulara göre, böbrekte iskemi ve reperfüzyon hasarı oluşturma ihtimali olan vakalarda önceden omega-3 yağ asidi verilmesinin bu dokuda koruyucu etki sağlayabileceği sonucuna ulaşılmıştır.

**Anahtar Kelimeler:** Böbrek, İnflamasyon, İskemi-Reperfüzyon Hasarı, Oksidatif stres, Omega 3 yağ asitleri.

##### Abstract

##### Objective

Ischemia reperfusion (IR) injury is caused by a sudden and temporary impairment of blood flow to a particular organ or tissue. Renal IR-induced kidney damage causes high levels of permanent damage and mortality. Dietary omega-3 fatty acids have anti-inflammatory

İletişim kurulacak yazar/Corresponding author: ferhat.sirinyildiz@adu.edu.tr

Müracaat tarihi/Application Date: 05.03.2021 • Kabul tarihi/Accepted Date: 30.07.2021

ORCID IDs of the authors: F.Ş. 0000-0001-8800-9787; G.C. 0000-0002-6943-7521

and immune-modulating effects and are used as protective agents.

### Materials and Methods

In the study; Protective effects of different doses of omega-3 fatty acid in ischemia reperfusion injury were investigated by biochemical and histological analyses. 40 adult female rats were divided into 5 groups as sham control, IR, IR+100, IR+400, IR+700 (n:8). The right kidney was removed by nephrectomy in the sham control group, and the left kidney was not treated. For IR injury; the right kidney was removed by nephrectomy, and the left kidney was clamped. Omega-3 fatty acids of 100 mg/kg, 400 mg/kg and 700 mg/kg were administered by gastric gavage to the treatment groups for 14 days before the surgery and for 15. gastric gavage was administrated in the morning of the operation.

### Results

According to these data; with application of omega-3, histopathological examination results were correlated. It is found that, histopathological results were supported by biochemical results. There was a significant decrease in malondialdehyde (MDA) and myeloperoxidase (MPO) levels in the treated groups, while catalase (CAT) and glutathione peroxidase (GSH-Px) levels were detected to be increased.

### Conclusion

It was concluded that administration of omega-3 fatty acids beforehand in cases that may cause ischemia and reperfusion damage in the kidney can provide a protective effect on this tissue.

**Keywords:** Inflammation, Ischemia-Reperfusion Injury, Kidney, Omega 3 fatty acids, Oxidative stress.

## Introduction

IR injury can be defined by restriction of blood flow to an organ followed by restoration of blood flow and re-oxygenation. In particular, IR damage may occur in the processes after infarction, sepsis, and organ transplantation (1). IR; it is a process that leads to the depletion of cellular energy, the accumulation of sodium, calcium and reactive oxygen radicals in the cell, and the activation of numerous enzyme systems, including proteases, nitric oxide synthases, phospholipases, and endonucleases. It also exacerbates tissue damage by initiating an inflammatory cascade involving leukocyte activation. This process widely results in cell damage and cell death (2).

Kidneys; regulating the volume and content of body fluids, adjusting blood pressure, fluid-electrolyte balance and acid-base balance; purifying the blood from cellular waste products such as urea uric acid; it has different functions such as endocrine function. The amount of blood passing through to both kidneys is 21% of the cardiac output (3).

IR damage in the kidney causes rapid kidney dysfunction and acute kidney damage, a clinical syndrome with high mortality rates. Ischemia in the kidneys is often used in major urological surgeries such as transplantation, partial nephrectomy, anatomic nephrolithotomy, cardiopulmonary surgery. It is seen in cardiac surgeries such as bypass, intensive care patients, post-traumatic hypovolemia, severe hypotension, and burn patients (4). The pathophysiology

of IR injury in the kidney acts in a very complex way. Studies have shown that there are some pathological pathways, such as activation of neutrophils, release of reactive oxygen species, and other inflammatory mediators including adhesion molecules and various cytokines (5). If the blood supply stops in a tissue and a certain time is exceeded, irreversible tissue damage will occur. In experimental studies, it has been determined that this critical time period is around 30 minutes for the kidney (6).

Fatty acids containing double bonds in the hydrocarbon chain are called unsaturated fatty acids, a fatty acid containing 2 double bonds is called a polyunsaturated fatty acid (PUFA). Although omega-3 fatty acids, which are included in the PUFA group, are divided into various groups, various studies have been carried out on the types that are consumed by adding to the diet. Very long-chain omega-3 fatty acids, eicosapentaenoic acid (EPA) and docosahexaenoic acid (DHA) affect the physical structure of cell membranes and membrane protein-mediated responses, lipid mediator production, cell signaling, and gene expression in many different cell types (7).

Results from experimental and clinical studies provided evidence that omega-3 fatty acids are anti-inflammatory and immunomodulatory, making them potential therapeutic agents for inflammatory and autoimmune diseases (8). Omega-3 fatty acids have a wide range of biological effects leading to improvements in blood pressure and cardiac function, arterial compliance, endothelial function and vascular reactivity, lipid and lipoprotein metabolism, decreased neu-

trophil and monocyte cytokine formation, and potent antiplatelet and anti-inflammatory effects (9).

The aim of this study is to investigate the efficacy of omega-3 fatty acids at different doses in experimental renal ischemia reperfusion injury, which has been shown to be effective as a result of various experimental studies. For this purpose, the efficacy of omega-3 applied to the ischemia and subsequent reperfusion created by surgical methods for 14 days before the procedure was determined by biochemical and histopathological methods.

## Materials And Methods

### Experimental Animal Material

This experimental study was started with the approval of ADU HADYEK, numbered 64583101/2015/083. All animal experiments were carried out under optimized laboratory conditions using a total of 40 female Wistar-albino rats weighing between 250-300 g in the ADU Experimental Animals unit. Analyzes of the experiment were carried out in ADU Central Research Laboratory and Faculty of Medicine Histology-Embryology and Physiology Department Laboratory.

### Experimental Groups and Application Protocol

*Sham group:* These animals were surgically intervened, the right kidney was removed by nephrectomy, and the left kidney was not exposed to IR damage with a clamp.

*IR group:* The animals in this group underwent surgery, the right kidney was removed by nephrectomy, and the left kidney was exposed to IR damage with a clamp.

*IR+100 group:* The doses of 100 mg/kg omega 3 fatty acids were administered by gastric gavage for 14 days before surgery and for 15. administration in the morning of the operation. On the day of operation, the right kidney was removed by nephrectomy, and the left kidney was exposed to IR damage with a clamp.

*IR+400 group:* The doses of 400 mg/kg omega 3 fatty acids were administered by gastric gavage for 14 days before the surgery and for 15. administration in the morning of the operation. On the day of operation, the right kidney was removed by nephrectomy, and the left kidney was exposed to IR damage with a clamp.

*IR+700 group:* The doses of 700 mg/kg omega 3 fatty acids were administered by gastric gavage for 14 days before the surgery and for 15. administration in the morning of the operation. On the day of opera-

tion, the right kidney was removed by nephrectomy, and the left kidney was exposed to IR damage with a clamp.

IR injury procedure was applied to all groups except the negative control and sham control group. Anesthesia dose was prepared as ketamine (90 mg/kg) - xylazine (10 mg/kg). After the nephrectomy of the right kidney, the ischemia time of the remaining left renal artery was applied as 45 minutes. At the end of 45 minutes, the clamp was removed and a 60-minute reperfusion period was applied. At the end of the reperfusion period, the IR injured kidney was removed and the rats were sacrificed.

### Biochemical Analysis

Kidney tissues weighed for biochemical analysis were homogenized with a tissue homogenizer (Ultra Turrax, IKA-WERKE, Germany). Malondialdehyde (MDA), myeloperoxidase (MPO), glutathione peroxidase (GPH-Px) catalase (CAT) levels were measured in kidney tissue. Measurements were made with ELISA Reader (BIO-TEK ELX800, U.S.A.) following the kit procedures.

### Histopathological Analysis

Cortical degeneration, glomerular shrinkage-growth, tubular damage, medulla degeneration and congestion in the kidney tissues were evaluated. The histological scoring performed was as follows: 0: no damage, 1: mild, 2: moderate, and 3: extensive damage. For histopathological evaluation, hematoxylin and eosin (HE) staining was performed and examined under a light microscope.

### Statistical analysis

Results were given as mean  $\pm$  standard deviation according to the data. Analyzes were done with GraphPad 7 statistical program (GraphPad Software, Inc., CA, USA). Mann-Whitney U test and One Way ANOVA tests were used for statistical evaluation and  $p < 0.05$  was considered statistically significant.

## Results

The results obtained were examined in two sections: Histopathological and Biochemical results.

### Histopathological Results

The results of histological analysis are shown in Table 1. According to these results, while the histopathological scores were highest in the untreated IR group, scores were found close to the sham group with treatment. No significant difference was found between the doses of omega-3 therapy.



As a result of HE staining and examination under light microscope, the following results were found about the groups: In the sham group; mild cortical-medullary congestion and mild glomerular size were observed (Figure 1). In the IR group; mild cortical degeneration, glomerular shrinkage, hemorrhage, tubular and medullary degeneration were detected (Figure 2). In the IR+100 group; mild cortical and tubular degeneration was determined (Figure 3). In the IR+400 group; mild cortical and tubular degeneration and mild glomerular shrinkage were observed (Figure 4). In the IR+700 group; mild cortical and tubular degeneration, mild glomerular shrinkage and mild cortical-medullary congestion were observed (Figure 5).

**Biochemical Results**

The lowest kidney tissue GSH levels were observed in the IR group (Figure 6). The GSH value of the sham group was statistically significantly lower than in the IR group ( $p < 0.005$ ). There was no significant difference in GSH levels between the IR-IR+100, IR+100-IR+400 and IR+400-IR+700 groups. It was observed that the GSH level of the IR400 group was significantly lower than the IR group ( $p < 0.05$ ). The tissue GSH level of the IR700 group was found to be significantly

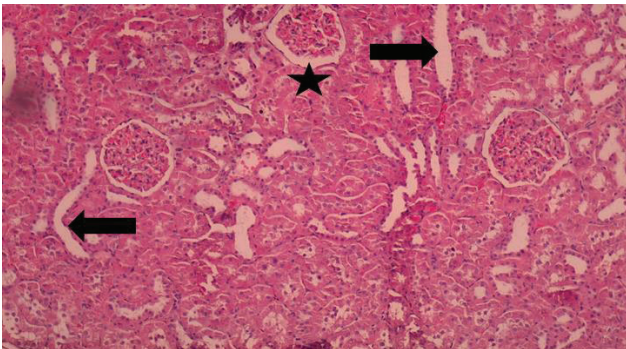
lower than the IR and IR+100 groups ( $p < 0.05$ ).

The highest kidney tissue MPO levels were observed in the IR group (Figure 7). The MPO value of the sham group was statistically significantly lower than in the IR group ( $p < 0.005$ ). The MPO value of the IR+100, IR+400 and IR+700 groups was statistically significantly lower than the IR group. ( $p < 0.05$ ). There was no statistically significant difference in MPO levels between the other groups ( $p > 0.05$ ).

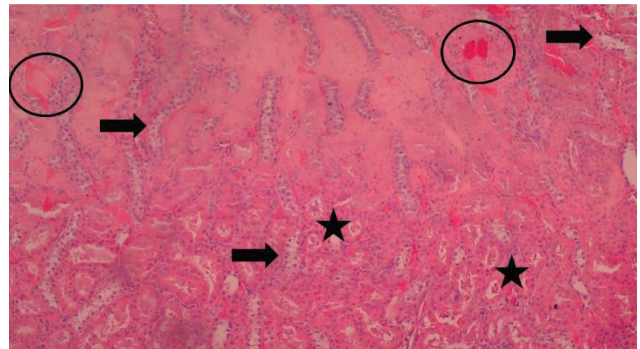
The highest kidney tissue MDA levels were observed in the IR group (Figure 8). The MDA value of the sham group was statistically significantly lower than in the IR group ( $p < 0.01$ ). The MDA values of the IR+100, IR+400 and IR+700 groups were statistically significantly lower than the IR group. ( $p < 0.05$ ). There was no significant difference in MDA levels between the treatment groups ( $p > 0.05$ ).

There was no significant difference between the groups in terms of CAT levels ( $p > 0.05$ ) (Figure 9).

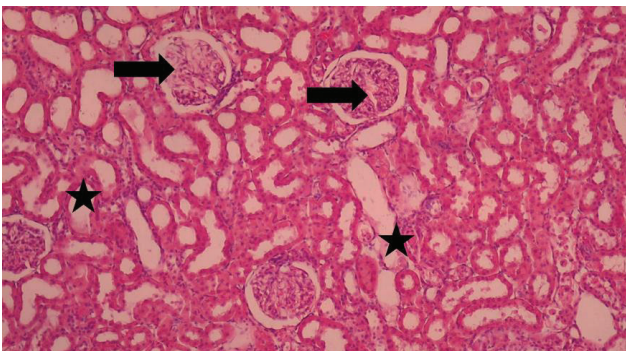
All biochemical results are given in Table 2 in a comparative manner.



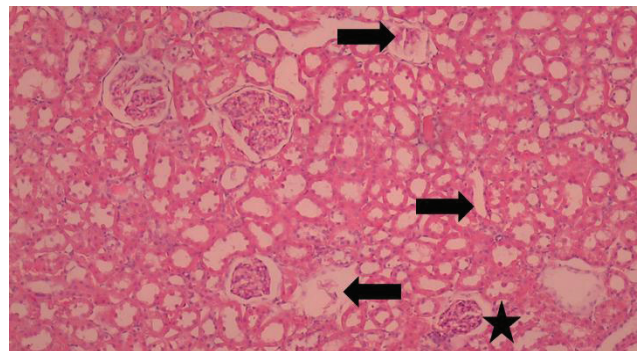
**Figure 1**  
Histological View of the Sham Group (Arrow: Congestion; Star: Slight glomerular enlargement). HE dying.



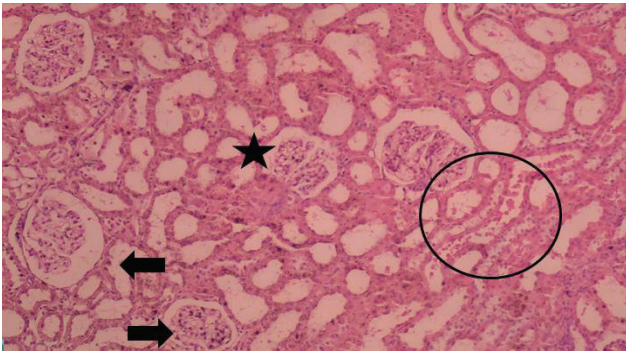
**Figure 2**  
Histological View of the IR Group (Arrow: Degeneration; Star: Glomerular shrinkage, Circle: Hemorrhage). HE dying.



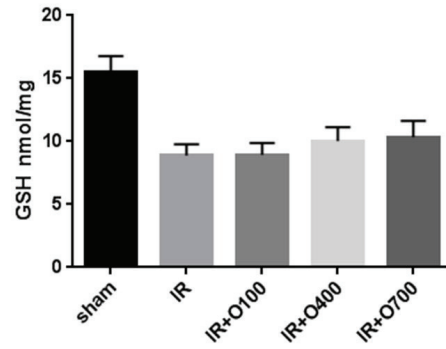
**Figure 3**  
Histological View of the IR+100 Group (Arrow: Cortical degeneration; Star: Tubular degeneration). HE dying.



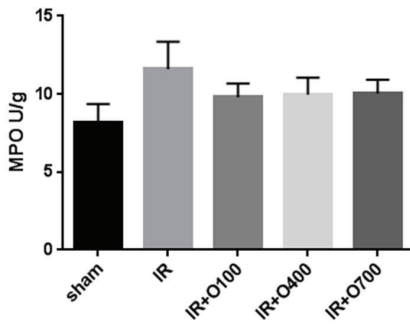
**Figure 4**  
Histological View of the IR+400 Group (Arrow: Cortical and tubular degeneration; Star: Mild glomerular shrinkage). HE dying.



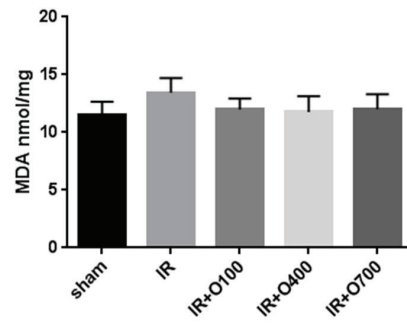
**Figure 5**  
Histological View of the IR+700 Group (Arrow: Cortical and tubular degeneration; Star: Mild glomerular shrinkage; Circle: Cortical-medullar congestion). HE dying.



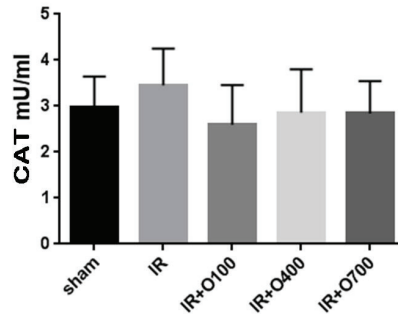
**Figure 6**  
Tissue GSH Levels in Experimental Groups



**Figure 7**  
Tissue MPO Levels of Experimental Groups



**Figure 8**  
Tissue MDA Levels of Experimental Groups



**Figure 9**  
Tissue CAT Levels of Experimental Groups

**Table 1** Histopathological scoring results

	Congestion	Cortical degeneration	Glomerular degeneration	Tubular degeneration	Medullary degeneration
Sham	1	0	0	0	0
IR	2	2	1	2	0
IR+100	1	1	0	1	0
IR+400	0	1	0	1	0
IR+700	0	1	0	1	0

**Table 2** Tissue GSH, MPO, MDA, CAT Levels of Study Groups

Groups (n:8)	GSH (nmol/mg)	MPO (U/g)	MDA (nmol/mg)	CAT (mU/ml)
SHAM	15.47±0.465	8.186±0.413	11.50±0.413	2.978±0.235
IR	8.871±0.328	11.59±0.625	13.42±0.453	3.454±0.282
IR+100	8.948±0.334	9.793±0.315	11.97±0.340	2.600±0.303
IR+400	10.04±0.391	9.961±0.388	11.75±0.487	2.859±0.334
IR+700	10.32±0.458	10.04±0.310	12.01±0.460	2.841±0.249

## Discussion

In kidney transplants, the blood flow to the kidney is interrupted until the kidney is removed from the donor and the arterial connection is established in the recipient. Apart from renal transplantation, ischemic renal failure develops in many conditions with a decrease in renal blood flow that may occur in the kidneys due to various reasons (9). In the experimental IR damage model simulated in our study, one of the pioneering interventions that can be taken against real life problems was investigated.

Different animal models have been developed for the experimental induction of renal ischemia reperfusion injury. It was found that the most common method among these models is clamping the renal arteries and veins together. Ischemia damage created in this way is in parallel with clinical findings (10). In our study, after a single kidney was surgically removed, the renal artery and vein in the remaining kidney were clamped. The results obtained support the results of experimental ischemia reperfusion injury in the literature.

It has been stated that the duration of renal ischemia is as important as the ischemia reperfusion method. Ischemia period in the kidney is generally limited to 30 to 60 minutes (11,12). Williams et al. (13) investigated the effects of renal IR injury on blood and tissue samples at 0, 0.5, 1, 2, 4, 6, 9 and 24 hours and 1 week after reperfusion following 45 minutes of ischemia. In this study, it was stated that the effects of reperfusion were detected at the 1st hour. In our study, in accordance with the literature, a 60-minute reperfusion time

was applied, followed by a 45-minute ischemia period. Both biochemical and histopathological results clearly showed that IR damage occurred.

It has been determined that oxidative damage is the main effect of IR damage. In studies aimed at treating the damage caused by oxidative stress, sweeping the ROS formed with the help of a powerful antioxidant is one of the main goals, and it also contributes to the acceleration of the treatment process (14). In our study, omega-3 was used as a precursor against IR damage. It was thought that the oxidant scavenger, possessed by omega-3 fatty acids, was responsible for the detected improvement.

Omega-3 fatty acids play an important role in maintaining cellular functions appropriately. In experimental studies, it has been shown that omega-3 fatty acids have a protective effect against oxidative damage (15,16). The different doses of omega-3 IR group used in our study were effective in approaching the results in the sham group. These results were shown biochemically and histopathologically.

Grande et al. (17) showed that DHA has antiproliferative effects on renal mesenchyme in mesangial proliferative glomerulonephritis model in their studies. In our study, protective effects of omega-3 fatty acids on experimental damage were shown.

After oxidation, MDA as the final product as a result of peroxidation occurring especially in the lipids of cellular membranes, and different methods are used as an indicator of lipid peroxidation in the tissue. In many studies, MDA levels have been evaluated as an indi-



cator of oxidative damage (18-20). In our study, MDA values, one of the indicators of lipid peroxidation, were examined in kidney tissue. The significant increase in this parameter especially in the ischemia-reperfusion group is in line with the increased MDA values obtained in previous studies.

Measurement of SOD, CAT and GSH-Px enzyme activities has been used as an antioxidant marker in various experimental studies (21-23). In our study, glutathione levels were determined in the studied kidney tissue as an indicator of the antioxidant system. It is thought that increased GSH levels in the tissue due to ischemia-reperfusion result from the increase in the antioxidant system activity of the related tissue against oxidative damage. In addition, when MPO is high in the IR group that supports MDA levels and the CAT levels are low, it can be said that the oxidant-antioxidant balance is disrupted by IR and the balance is achieved with omega-3 application.

## Conclusion

The results showed that IR injury caused a serious damage to the kidney tissue, especially with oxidative damage caused. It has been shown that omega-3 fatty acids, which are used as food supplements due to their different effects, also have a protective effect against renal IR injury. In order to benefit from this protective effect of omega-3 fatty acids, it is thought that the protective use of them in order to prevent possible renal IR injury will contribute to other pre-treatment or post-treatment processes.

*Ethics Approval:* ADU-HADYEK 64583101/2015/083

*Financial Disclosure:* The project was supported by the Scientific Research Projects Unit of ADU with the number TPF-16032.

## References

- Jang HR, Rabb H. The innate immune response in ischemic acute kidney injury. *Clin Immunol.* 2009;130:41-50.
- Ergün O, Ulman C, Kılıçalp AS. Carnitine as a agent in experimental renal ischemia-reperfusion injury. *Urol Res* 2001;29:186-9.
- Guyton AC. The kidneys and body fluids. In: *Textbook of Medical Physiology.* 9th edition. Philadelphia: WB Saunders Company; 1996. 297–313.
- Gasnov, F., Aytac, B., & Vuruskan, H. (2011). The effects of tadalafil on renal ischemia reperfusion injury: an experimental study. *Bosnian journal of basic medical sciences,* 11(3), 158.
- Malek, M., & Nematbakhsh, M. (2015). Renal ischemia/reperfusion injury; from pathophysiology to treatment. *Journal of renal injury prevention,* 4(2), 20.
- Islam CF, Mathie RT, Dinneen MD, Kiely EA, Peters AM, Grace PA. Ischemia-reperfusion injury in the rat kidney the effect of preconditioning. *Br J Urol* 1997;6:842–7.
- Calder, P. C., & Yaqoob, P. (2009). Understanding omega-3 polyunsaturated fatty acids. *Postgraduate medicine,* 121(6), 148-157. Calder PC: Polyunsaturated fatty acids, inflammation, and immunity. *Lipids* 2001, 36:1007–1024.
- Mori TA, Beilin LJ: n-3 Fatty acids, blood lipids and cardiovascular risk reduction. *Curr Opin Lipidol* 2001, 12:1211–1217.
- Alejandro V, Scandling JD, Sibley RK, et al: Mechanisms of filtration failure during postischemic injury of the human kidney. *J Clin invest* 95: 820-831,1995
- Simmons MN, Schreiber MJ, Gill IS. Surgical Renal Ischemia: A Contemporary Overview. *J Urol.* 2008;180(1):19-30.
- Fouad AA, Al-Mulhim AS, Jresat I, Morsy MA. Protective effects of captopril in diabetic rats exposed to ischemia/reperfusion renal injury. *J Pharm Pharmacol.* 2013;65(2):243- 252.
- Kocoglu H, Ozturk H, Ozturk H, et al. Effect of dexmedetomidine on ischemiareperfusion injury in rat kidney: A histopathologic study. *Ren Fail.* 2009;31(1):70-74.
- Williams P, Lopez H, Britt D, et al. Characterization of Renal Ischemia-Reperfusion Injury in Rats. *J Pharmacol Toxicol Methods.* 1997;Feb:37(1):1-7
- Mortensen M, Rosenfield RL, Littlejohn E. Functional significance of polycystic ovaries in healthy adolescents. *J Clin Endocrinol Metab,* 2006, 91: 3786-3790.
- Sarsılmaz M, Songur A, Özyurt H, et al. Potential role of dietary ω-3 essential fatty acids on some oxidant/antioxidant parameters in rats' corpus striatum. *Prostagl Leukot Essent Fatty Acids* 2003; 69(4): 253-259.
- Miyasaca CK, Alves de Souza JA, Torres RP, Filho JM, Lajolo FM, Curi R. Effect of the administration of fish oil by gavage on activities of antioxidant enzymes of rat lymphoid organs. *Gen Pharmacol* 1998; 30 (5): 759-762.
- Grande JP, Walker HJ, Holub BJ ve ark. Suppressive effects of fish oil on mesengial cell proliferation in vitro and in vivo. *Kidney Int* 2000;57:1027-1040.
- Slater TF. Free radical mechanisms in tissue injury. *J Biochem* 1984; 222:1-15.
- Ozan E. Koyutürk L.Sapmaz T. Böbrek İskemi Reperfüzyon Hasarında Antioksidan Olarak Prostaglandin E1(PGE)Kullnımının İncelenmesi: Fırat Üniversitesi Tıp Fakültesi Histoloji Ve Embriyoloji Anabilimdalı. *Fırat Tıp Dergisi* 2004;9(3):67-71
- Ohkawa H, Ohishi N, Tagi K. Assay for lipid peroxides in animal tissues by thiobarbituric acid reaction. *Anal Biochem.* 1979; 95: 351-358.
- İnal M, Altınışık M, Bilgin MD. The effect of quercetin on renal ischemia and reperfusion injury in the rat. *Cell Biochem Funct.* 2002 dec; 20(4):291-6.
- Wall J. Antioxidants In Prevention Of Reperfusion Damage Of Vascular Endothelium. *TSMJ* May 2000;1:67-70.
- Becker BF, Reinholz N, Leipert B, Raschke P, Permanetter B, Gerlach E. Role of uric acid as an endogenous radical scavenger and antioxidant. *Chest.* 1991; 100: 176-181.