

The Healing Effect of Resveratrol on Ischemic Tissue Injury in an Experimental Carbon Monoxide Poisoning Model

Aynur Sahin¹, Sinan Pasli², Mustafa Cicek³, Suleyman Caner Karahan⁴, Ahmet Mentese⁵, Esin Yulug⁶, Yunus Karaca¹, Ozgur Tatli¹

¹Karadeniz Technical University, School of Medicine, Department of Emergency Medicine, Trabzon, Turkey

²Gumushane State Hospital, Emergency Medicine Service, Gumushane, Turkey

³Kanuni Education and Research Hospital, Department of Emergency Medicine, Trabzon, Turkey

⁴Karadeniz Technical University, School of Medicine, Department Of Medical Biochemistry, Trabzon, Turkey

⁵Karadeniz Technical University, Health Services Vocational School, Program Of Medical Laboratory Techniques, Trabzon, Turkey

⁶Karadeniz Technical University, School of Medicine, Department of Histology and Embriology, Trabzon, Turkey

Address for Correspondence: Sinan Pasli, **E-mail:** drsinanpasli@gmail.com

Received: 17.04.2020; **Accepted:** 06.07.2020; **Available Online Date:** xxx

©Copyright 2020 by Dokuz Eylul University, Institute of Health Sciences - Available online at www.jbachs.org

Cite this article as: Sahin A, Pasli S, Cicek M, Karahan SC, Mentese A, Yulug E, Karaca Y, Tatli O. The Healing Effect of Resveratrol on Ischemic Tissue Injury in an Experimental Carbon Monoxide Poisoning Model. J Basic Clin Health Sci 2020; 4:288-296.

ABSTRACT

Purpose: To investigate the healing effect of resveratrol on ischemia, inflammation and oxidative injury in brain and heart tissue of rats in an experimentally induced carbonmonoxide (CO) intoxication model.

Methods: Twenty-eight mature female Sprague Dawley rats were randomized into four groups of seven animals each. Groups I and II inhaled room air for 60 minutes. Groups III and IV inhaled a high concentration of a 5000 ppm CO gas mixture at 4 L/min until loss of consciousness. Blood CO levels were measured from 1 mL blood specimens collected from the tail vein. Groups I and III received 1 mL of normal saline while groups II and IV received 25 mg/kg resveratrol intraperitoneally. At the end of 48 hour, the rats were sacrificed and later blood, brain and heart tissue samples were taken for histopathological and biochemical evaluation. Neuron damage scores, percentages of degenerate neurons and apoptosis rates in the cortex and hypothalamus were calculated in brain tissues. Myocyte degeneration, vascular congestion and myocyte apoptosis rates were calculated in heart tissues. Total antioxidant (TAS), total oxidant (TOS) and oxidative stress index (OSI) levels were also calculated from the tissue samples.

Results: Histopathological evaluation revealed that resveratrol significantly reduced tissue damage in the brain when groups III and IV were compared ($p < 0.05$). Resveratrol also reduced cardiac myocyte degeneration and myocyte apoptosis rate in heart tissue ($p = 0.004$ and $p = 0.002$). No positive effect was determined at analysis of antioxidant parameters.

Conclusion: The results of this study investigated that resveratrol administration in experimental setting may be beneficial in healing injury secondary to CO intoxication in brain and heart tissue.

Keywords: CO poisoning, resveratrol, brain, heart

INTRODUCTION

Intoxications associated with carbon monoxide (CO), a colorless and odorless gas resulting from incomplete combustion of carbon-containing compounds, are a cause of growing worldwide mortality and morbidity. The pathophysiology of CO intoxication is complex, and in addition to the cellular damage caused by CO itself, the hypoxia and ischemia produced by the CO-hemoglobin complex also play a significant role in the process (1). Low endogenous levels of CO are physiological. The essential problem lies in excessive exogenous CO intake (2). The main target of CO is hemoglobin

(Hb), and the affinity of Hb for CO is 210 times greater than that for oxygen. CO binds to Hb, and COHb forms when the oxygen in Hb is replaced by CO. Since the oxygen binding regions in this compound that forms have higher affinity for oxygen, the bound oxygen is prevented from being presented to tissues. This in turn results in tissue hypoxia. The most important causes of mortality and morbidity are complications developing secondary to tissue hypoxia developing in the brain and heart. However, tissue hypoxia is not the only mechanism responsible for the toxic effects of CO.

Direct cellular damage caused by inflammation and oxidative stress developing following hypoxia also produce deleterious effects in several tissues, particularly the brain and heart (3). These range from mild, nonspecific findings in the acute period to severe manifestations including coma, cerebral and myocardial infarction, and death (4). Another problem following acute exposure is delayed or permanent neurocognitive sequelae. These typically emerge 27–270 days after intoxication, and may be lifelong (5).

The measurement of COHb levels is today an important diagnostic technique. However, the correlation between blood or tissue COHb levels and organ damage is not a powerful one. COHb levels exceeding 60% generally result in mortality, while clinical findings are variable at lower levels. It is not always possible to determine clinical severity using COHb levels (1). The basis of treatment of acute CO intoxication is administration of 100% oxygen with establishment of an open airway. Hyperbaric oxygen therapy (HBO) is applied when clinical findings are severe, and under limited indications. Nonetheless, the effectiveness of HBO in preventing acute and delayed complications developing in association with severe intoxications is controversial (6). This is because the underlying mechanism the resulting complications is not limited to tissue hypoxia.

The options available in treatment planning of patients with CO intoxication are limited. Synthesis of reactive oxygen products increases in intoxication secondary to tissue hypoxia. The numbers of studies concerning the place and importance of antioxidant therapies as an alternative to oxygen therapy are therefore increasing rapidly. Treatments with antioxidant and anti-inflammatory efficacy therefore need to be investigated in terms of preventing damage occurring secondary to inflammation under the oxidant effect of free oxygen radicals.

Resveratrol (3,4', 5-trihydroxystilbene; $C_{14}H_{12}O_3$) is a natural polyphenolic molecule shown by researches to possess anti-inflammatory, antioxidant, anti-apoptotic, anti-aging and anti-cancer properties (7). Resveratrol is a phenolic phytoalexin found in approximately 72 plants in nature, particularly in red grape, and in peanuts, pine trees, and legumes (8). Studies have revealed that the most important mechanism in the neuroprotective and cardio-protective effects of resveratrol is its potent protective activity against oxidative stress. Its reactions with several signalling pathways at the molecular level are also a particular subject of investigation (9).

The aim of this study was to investigate whether resveratrol, with its known antioxidant and cyto-protective properties, can prevent or reduce damage developing secondary to ischemia, oxidative damage, and inflammation in brain and heart tissue which are hypoxia-sensitive vital organs.

METHODS

Study Design

This randomized, non-blinded experimental animal study was performed following approval of the study protocol by the Institutional Animal Care and Ethics Committee (Approval No. 2016/18)

Study Groups

Twenty-eight female Sprague-Dawley rats (10 weeks old and weighing approximately 240–280 g) were used. These were housed in steel cages at room temperature until the day of the study with access to water and standard rat chow. Only water was permitted in the final 12 h before the study.

Experimental Protocol

The experimental protocol was based on a previously published experimental CO intoxication model (10). Rats were randomly assigned into four groups of seven rats each. For purposes of randomization, the rats were numbered from 1 to 28. These were written down and placed separately into an opaque envelope. These numbers were then drawn from the envelope by a member of staff in a blinded manner (11). For the experimental protocol, a two-part container made from special glass, 100x40x50 cm in size, capable of receiving gas from one end and with a hole to allow gas to escape in the other end, was designed as the experimental apparatus. During the first 60 min of the experimental protocol, rats in groups I and II were placed inside this glass jar and allowed to breathe room air. Rats in groups III and IV were made to inhale a high concentration of 5000 ppm CO gas mixture at 4 lt/min until losing consciousness. Carboxyhemoglobin (COHb) levels were measured immediately from 1 mL blood specimens collected from the tail veins into the blood gas syringe after the rats were removed from the jar, and the protocol specified for each group was initiated. The treatment protocol was applied four times to all rats via the intraperitoneal (i. p.) route at 12-h intervals over a total period of 48 h. Groups I and III received 1 mL normal saline solution while groups II and IV received 25 mg/kg resveratrol i. p. The dosage of resveratrol was based on a previous study in the literature (12). At the end of 48 h, rats were sacrificed by decapitation under 50 mg/kg ketamine and 5 mg/kg xylazine anesthesia and blood specimens were collected into yellow biochemistry tube, brain and heart tissue specimens were separately collected in a jar that contains 10% formaldehyde and the study was terminated.

Laboratory analysis

All measurements and scoring in the experimental protocol were performed by a biochemist and histologist blinded to the study groups.

COHb Level Measurement: Blood COHb levels were measured automatically using a blood gas device (Rapidlab 1265, Bayer Health Care LLC, Pittsburgh, USA) in the biochemistry laboratory.

Measurement of tissue antioxidant parameters: Protein levels in specimens were determined using a commercial kit (Thermo Scientific Pierce BCA Protein Assay Kit, Cat No: 23227, Rockford, IL, USA) following the manufacturer's instructions, and the results were expressed as mg/mL. Levels of all biochemical parameters measured in tissue were given in proportion to the sample protein amounts calculated for standardization.

Malondialdehyde (MDA), superoxide dismutase (SOD) and catalase (CAT) levels in brain and heart tissue specimens were measured using enzyme-linked immunosorbent assay (ELISA)

kits (Elabscience; Cat No. E-EL-0060, E-EL-R1424 and E-EL-R2456, respectively, Wuhan, China) in line with the manufacturer's instructions. The results were expressed as pg/mg protein. Total antioxidant status (TAS) and total oxidant status (TOS) in tissue specimens were measured using colorimetric kits (Rel Assay Diagnostics; Cat No. RL0024 and RL0017, respectively; Gaziantep, Turkey) in line with the manufacturer's instructions. The results were expressed as $\mu\text{mol H}_2\text{O}_2$ equivalent/L and mmol trolox equivalent/L, respectively. OSI values in tissue specimens were calculated using the formula $\text{OSI} = [(\text{TOS}, \mu\text{mol H}_2\text{O}_2 \text{ equivalent/L}) / (\text{TAS}, \mu\text{mol trolox equivalent/L}) \times 100]$ (13).

Histopathological Analysis

Brain and heart tissue specimens were fixed for 48 h in 10% formaldehyde and then subjected to histopathological analysis. All specimens were dehydrated by being passed through increasing alcohol series, cleared in xylene, and embedded in paraffin blocks. Sections 5 μm in thickness were then taken from these blocks using a fully automatic microtome (Leica RM 2255, Tokyo, Japan), stained with hematoxylin-eosin (H&E), and evaluated under a light microscope (Olympus BX-51; Olympus Optical Co., Tokyo, Japan).

Brain tissue was also scored semiquantitatively in terms of neuronal changes in the bilateral cortex regions following staining with cresyl violet (0=none, 1=mild, 2=moderate, 3=severe). The CA1, CA2 and CA3 regions in the cortex and hippocampus in all groups were examined in terms of percentages of degenerative neurons at 200X magnifications under a light microscope (Olympus Soft Imaging Solutions, Münster, Germany) (14, 15).

Heart tissue was evaluated semiquantitatively from 0 to 3 under light microscopy in terms of both myocardial cell degeneration and vascular congestion (0=none, 1=mild, 2=moderate, 3=severe) (16).

DNA fragmentations in cells from each tissue were identified using the terminal deoxynucleotidyl transferase (TdT) deoxyuridine triphosphate nick end-labeling assay (TUNEL) at analysis of tissue specimen apoptosis. An in situ cell death detection kit (Roche, Mannheim, Germany) was used for TUNEL staining in line with the manufacturer's instructions. TUNEL (+) with no areas of necrosis and with homogeneously stained brown were defined as apoptotic cells. The apoptotic index (AI=TUNEL (+) cell number/total cell number \times 100) was calculated by evaluating 100 cells in five different areas at 400X magnification in the brain (pyramidal neurons in the cortex and hippocampus) and heart (myocytes) (17).

Statistical Evaluations

Statistical analysis was performed on SPSS 23.0 software (IBM SPSS, Armonk, NY, USA). Statistical analysis of biochemical parameters, antioxidant enzymes were performed by ANOVA and Tukey Kramer multiple comparisons test was used for identification of the source of variation. Statistical analysis of histomorphological parameters were analysed by the non-parametric Mann Whitney-U test with Bonferroni correction. All data were shown as mean \pm standard deviation. $p < 0.05$ was considered statistically significant.

RESULTS

Biochemical results

The results and analyses of serum biochemical parameters in all the experimental groups are shown in Table 1. Significant elevation was observed in serum COHb levels between the control groups (Groups I-II) and the study groups exposed to CO (Groups III-IV) ($p = 0.006$ and $p = 0.003$ respectively). No statistically significant differences were observed between the groups in terms of serum oxidant and antioxidant parameters (Table 1).

Table 1. Brain and heart tissue serum oxidant and antioxidant parameter analyses and results in the study groups

	Group I Control+NS (Mean\pmSD)	Group II Control+RES (Mean\pmSD)	Group III CO+NS (Mean\pmSD)	Group IV CO+RES (Mean\pmSD)
*COHb level (mg/dl)	0.57 \pm 1.46 ^a	0.18 \pm 0.29 ^b	36.1 \pm 3.49 ^a	39.9 \pm 9.91 ^b
Brain Tissue				
-TAS	0.87 \pm 0.31	1.01 \pm 0.25	1.39 \pm 0.34	0.86 \pm 0.21
-TOS	1.95 \pm 0.42	1.84 \pm 0.51	1.79 \pm 0.25	1.71 \pm 0.33
-OSI	0.24 \pm 0.07	0.19 \pm 0.06	0.13 \pm 0.03	0.20 \pm 0.03
-MDA	32.5 \pm 17.9	24.9 \pm 6.17	29.3 \pm 10.8	26.5 \pm 2.83
-MPO	4.6 \pm 1.39	4.9 \pm 1.08	3.7 \pm 1.22	2.7 \pm 0.29
-SOD	326 \pm 131	86 \pm 13.2	119 \pm 58.3	173 \pm 48.2
-CAT	4.5 \pm 1.77	4.0 \pm 0.60	3.6 \pm 0.95	3.1 \pm 0.71
Heart Tissue				
-TAS	1.29 \pm 0.23	1.01 \pm 0.10	0.93 \pm 0.14	0.91 \pm 0.34
-TOS	2.02 \pm 0.44	2.67 \pm 0.96	2.57 \pm 1.04	2.02 \pm 0.60
-OSI	0.16 \pm 0.05	0.27 \pm 0.12	0.28 \pm 0.11	0.24 \pm 0.10
-MDA	9.24 \pm 6.39	10.1 \pm 4.69	8.8 \pm 2.35	21.0 \pm 14.2
-MPO	68.8 \pm 5.6	51.2 \pm 17.3	68.1 \pm 20.6	54.5 \pm 24.0
-SOD	44.5 \pm 14.9	47.3 \pm 25.7	71.0 \pm 5.90	90.7 \pm 22.8
-CAT	75.3 \pm 23.9	61.6 \pm 28.7	56.0 \pm 16.5	56.9 \pm 45.4

COHb level and antioxidant parameters: Comparisons in groups 1&2 and 3&4, also in groups 1&3, and 2&4 according to the Mann-Whitney U test with Bonferroni correction. $p < 0.05$ is statistically significant.

*: a, $p = 0.006$ b, $p = 0.003$

COHb: carboxyhemoglobin; **TAS:** total antioxidant status; **TOS:** total oxidant status; **OSI:** oxidative stress index; **MPO:** myeloperoxidase; **MDA:** malondialdehyde; **SOD:** superoxide dismutase; **CAT:** catalase; **RES:** resveratrol; **NS:** normal saline.

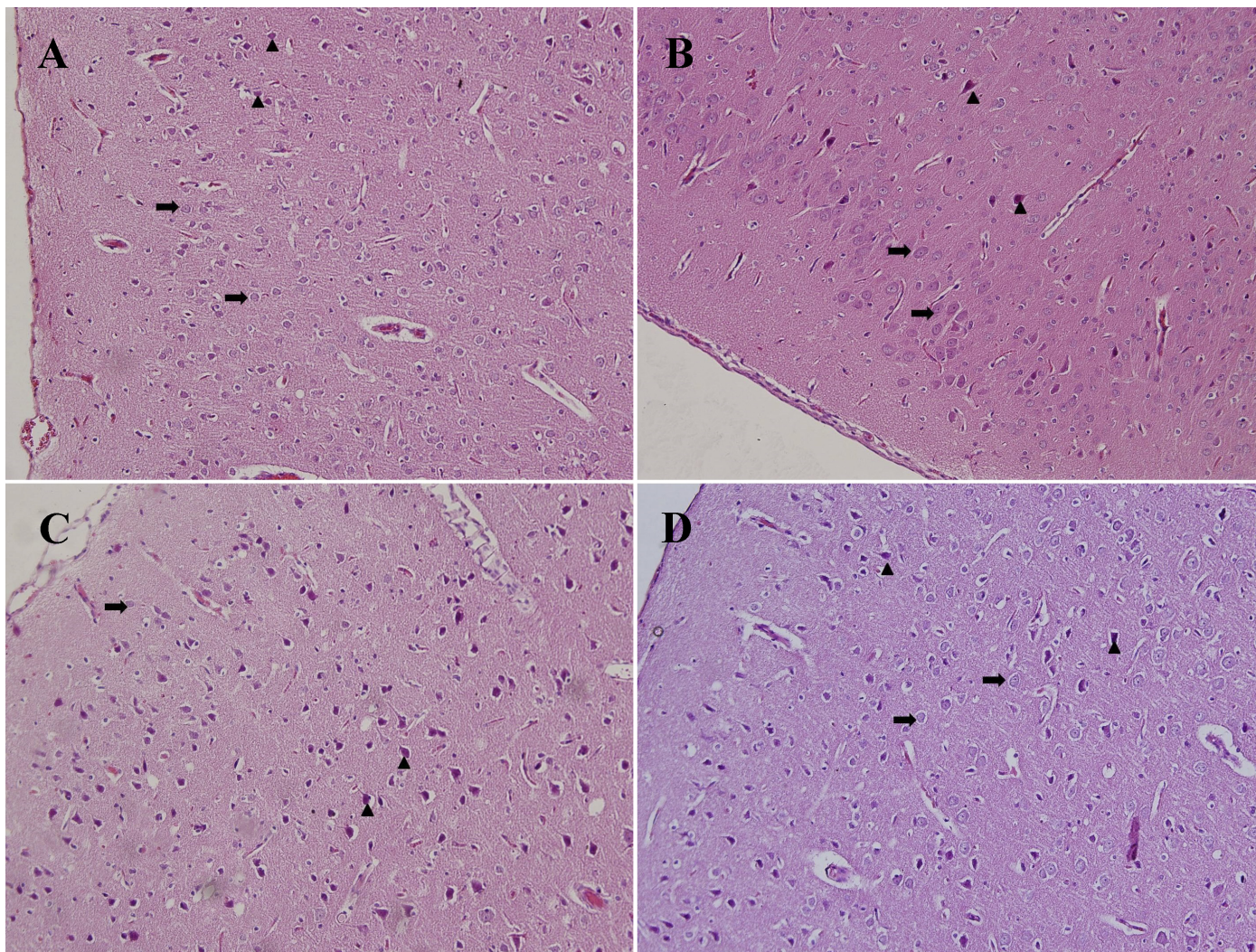


Figure 1. Cerebral cortex microphotographs (H&E X200). (A: Group 1, B: Group 2, C: Group 3, D: Group 4) Normal pyramidal neurons (↑), degenerative pyramidal neurons (Δ)

Table 2. A comparison of heart and brain tissue histopathological damage scores between the groups

	Group I Control+NS (Mean±SD)	Group II Control+RES (Mean±SD)	Group III CO+NS (Mean±SD)	Group IV CO+RES (Mean±SD)
Brain Tissue				
¥Neuran Damage Score	1.14±0.37 ^b	1.40±0.54	2.50±0.57 ^{a,b}	1.71±0.48 ^a
*Neuron Degeneration (%)	12.5±3.20 ^b	13.6±2.70 ^c	61.0±5.16 ^{a,b}	34.5±6.05 ^{a,c}
∞Kortex Apoptosis Rate (%)	7.85±2.54 ^{a,c}	13.0±3.08 ^{a,d}	54.0±6.37 ^{b,c}	25.8±4.09 ^{b,d}
<i>Hypothalamus Apoptozis Rate (%)</i>				
¶ CA-1 zone	6.85±3.89 ^b	7.60±4.03 ^c	37.2±4.03 ^{a,b}	20.0±2.44 ^{a,c}
# CA-2 zone	1.85±0.69 ^b	1.60±0.54 ^c	11.7±1.89 ^{a,b}	4.71±1.11 ^{a,c}
† CA-3 zone	3.28±1.60 ^b	3.60±1.14	10.0±2.58 ^{a,b}	4.28±1.38 ^a
Heart Tissue (%)				
Δ Myosit Degeneration	0.71±0.48 ^b	0.60±0.54 ^c	2.75±0.50 ^{a,b}	1.42±0.53 ^{a,c}
■ Vascular Congesion	1.14±0.37	1.40±0.54	1.75±0.50	1.42±0.53
▲ Myosit Apoptosis rate	8.71±1.79 ^b	8.20±1.30 ^c	46.0±6.05 ^{a,b}	21.7±5.12 ^{a,c}

¥, *, ∞, ¶, #, †, Δ, ■, ▲: Comparitions groups 1&2 and groups 3&4, also in groups 1&3, and 2&4 according to the Mann-Whitney U test with Bonferroni correction. Both of these analysis p<0.05 is statistically significant.

¥: a, p=0.015; and b, p=0.002 ¶: a, b, and c, p=0.002 Δ: a, p=0.004; b, p<0.001; and c, p=0.03
 *: a, p=0.015; and b, p=0.02 #: a, p=0.002; b and c; p<0.001
 ∞: a, p=0.03; b, c, and d, p=0.002 †: a and b, p=0.002 ▲: a, b, and c, p=0.002

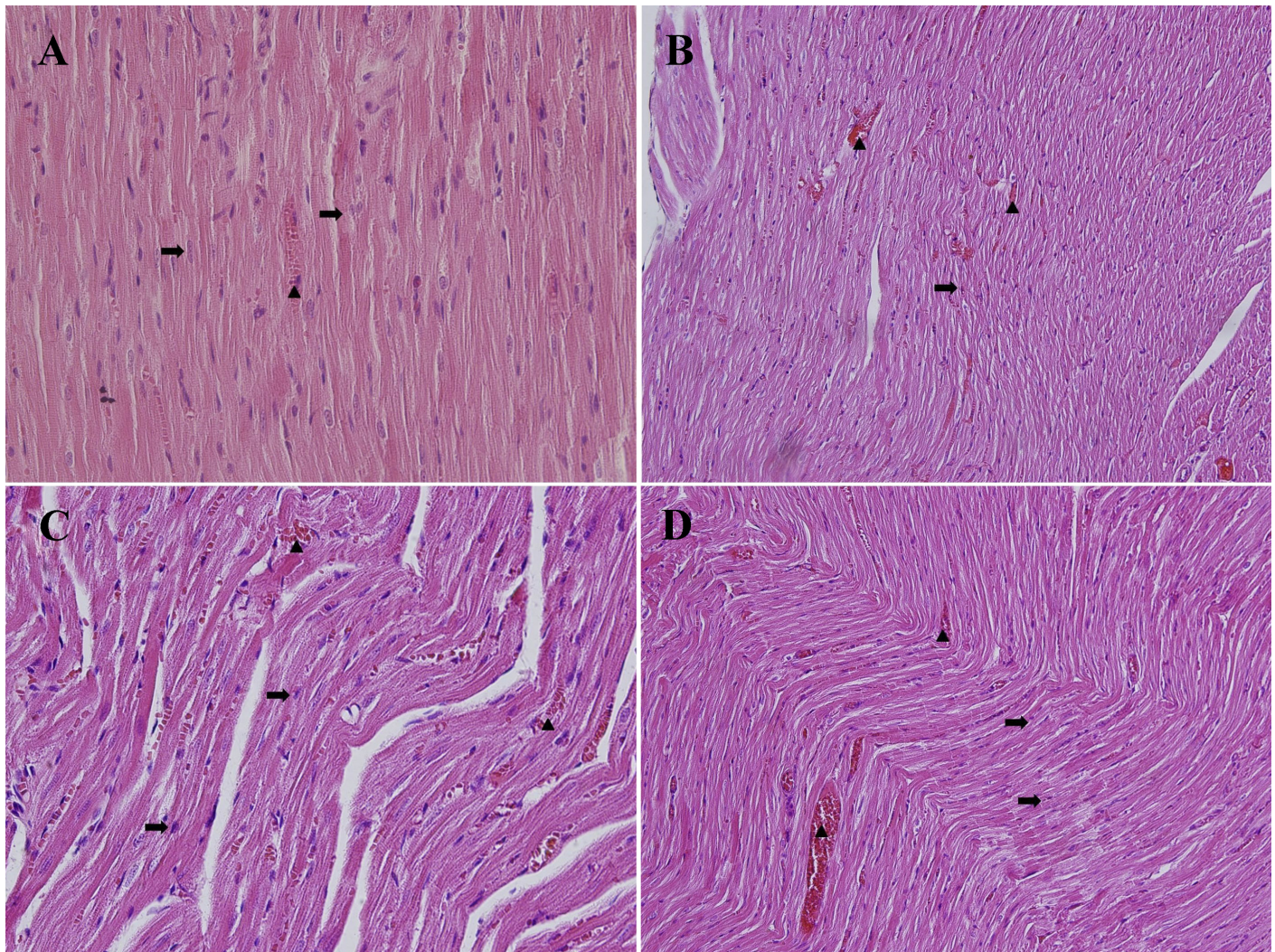


Figure 2. Myocardial tissue microphotographs (H&E X200) A: Group 1, B: Group 2, C: Group 3, D: Group 4) Myocardial cells (↑), vascular congestion (Δ)

Histopathological results

Evaluation of cerebral cortex tissues revealed normal pyramidal neurons in the control groups (Group I and II), while degenerative neurons and widespread apoptosis were observed in the groups exposed to CO (Groups III and IV) (Figure 1-3). Individual analysis of hippocampus regions CA1, CA2 and CA3 revealed that the CA1 region was the most affected (Figure 4). The greatest number of degenerative neurons was observed in the CA1 region in Group III. Histopathological damage scoring and results for brain tissues from all the study groups are shown in Table 2. Comparisons of neuron damage scores and neuron degeneration rates and apoptosis rates in three different regions of the cortex and hippocampus between the control groups (Group I and II) and the study groups (Groups III and IV) revealed that CO caused statistically significant damage (Table 2). A comparison of Group III, which received saline solution following CO exposure, and Group IV, which was treated with resveratrol, in terms of neuron damage scores, cortex apoptosis, and apoptosis rates in regions CA1, CA2, and CA3 of the hippocampus revealed significant healing in the following CO exposure (Table 2).

Heart tissue evaluation revealed a normal myocardial structure in groups I and II. Degeneration in heart muscle cells, expansion between muscle cells, widespread vascular congestion, and increased apoptosis were observed in Group III, which received saline solution only following CO exposure (Figure 2-5). However, heart muscle cells in Group IV, the group subjected to CO plus resveratrol treatment, exhibited an almost normal morphology. An analysis of the histopathological damage results for heart tissue is shown in Table 2. According to these results, CO exposure caused damage at the cellular level, while statistically significant improvement was observed in myocyte degeneration and myocyte apoptosis rates in the group receiving resveratrol treatment ($p=0.004$ and $p=0.002$, respectively). No significant improvement was observed in the group receiving resveratrol in vascular congestion scores ($p>0.05$).

DISCUSSION

This study investigated the effect of resveratrol, with known high antioxidant and anti-inflammatory capacities, on damage

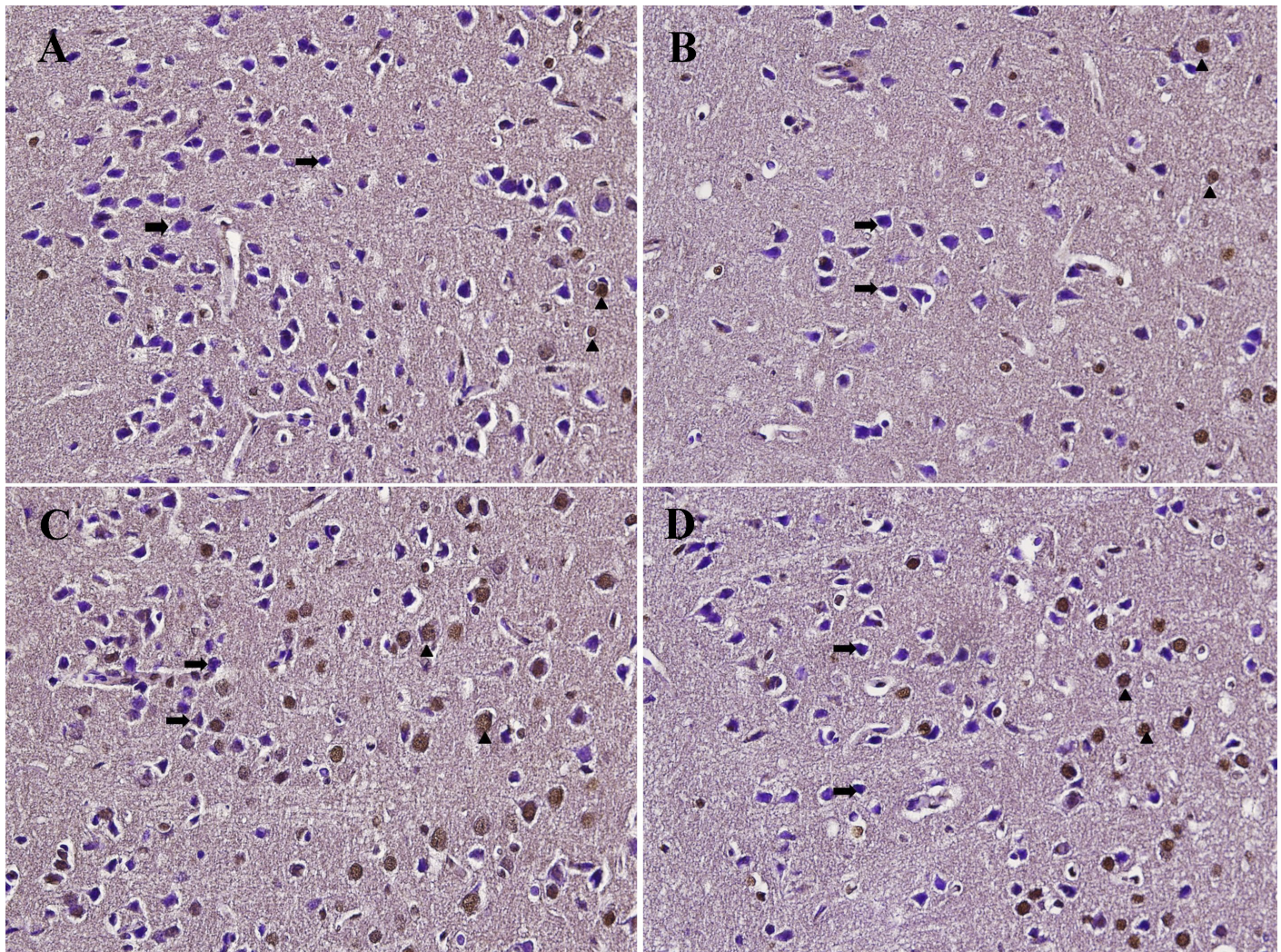


Figure 3. Cerebral cortex microphotographs (TUNELX200). (A: Group 1, B: Group 2, C: Group 3, D: Group 4) Normal pyramidal neurons (↑), apoptotic pyramidal neurons (Δ)

occurring in brain and heart tissue in an experimentally induced model of CO intoxication. Our study results showed that resveratrol exhibited an ameliorating effect on damage occurring secondary to CO exposure in both brain and heart tissue.

According to our study findings, CO exposure resulted in severe damage in cerebral tissue, showing that our toxicity model was successfully established. Analysis showed that resveratrol treatment exhibited significant positive effects on histopathological damage parameters. Carbon monoxide poisoning induces ischemia and cause cerebral damage (18). Oxidative stress is one of the most important mechanisms of CO poisoning (19). The principal toxicity mechanism of CO involves the prevention of oxygen transport by haemoglobin and causing tissue hypoxia and cell death by inactivating aerobic phosphorylation through inhibition of the enzyme mitochondrial cytochrome c (10). Brain and heart cells, which have the highest susceptibility to hypoxia, are therefore the tissues most affected by CO intoxication. Pin Wang and colleagues explained that MDA levels increased in serum, cerebral cortex

and hippocampus of rats with CO intoxication (20). According to the literature, histopathological injury begins with necrosis and apoptosis as a result of CO intoxication, followed by increased brain inflammation and oxidative stress in a period of time (19, 21). Studies have shown that resveratrol passes into brain tissue and exhibits a neuroprotective effect in hypoxia associated with Alzheimer's dementia, and cerebral ischemia (18, 22, 23). Several anti-inflammatory (microglia inhibition, astrocyte modulation, NF- κ B activity, anti-apoptotic, antioxidant NF- κ B, lipid peroxidation, veROS inhibition, and SIRT1 stimulation), anti-apoptotic and anti-amyloidogenic effects specific to the central nervous system underlie the neuroprotective effect of resveratrol (24). Tabrizan et al. evaluated necrosis, lipid peroxidation and Akt levels, and BAX and BCL2 expression following treatment with resveratrol at different lower levels (resveratrol 1, 5 and 10 mg/kg) in an in vivo CO toxicity model and compared these with a control group receiving normal saline solution only. In that study, there was no decrease in MDA levels in the groups given 1 and 5 mg/kg resveratrol treatment in 5 days period, whereas

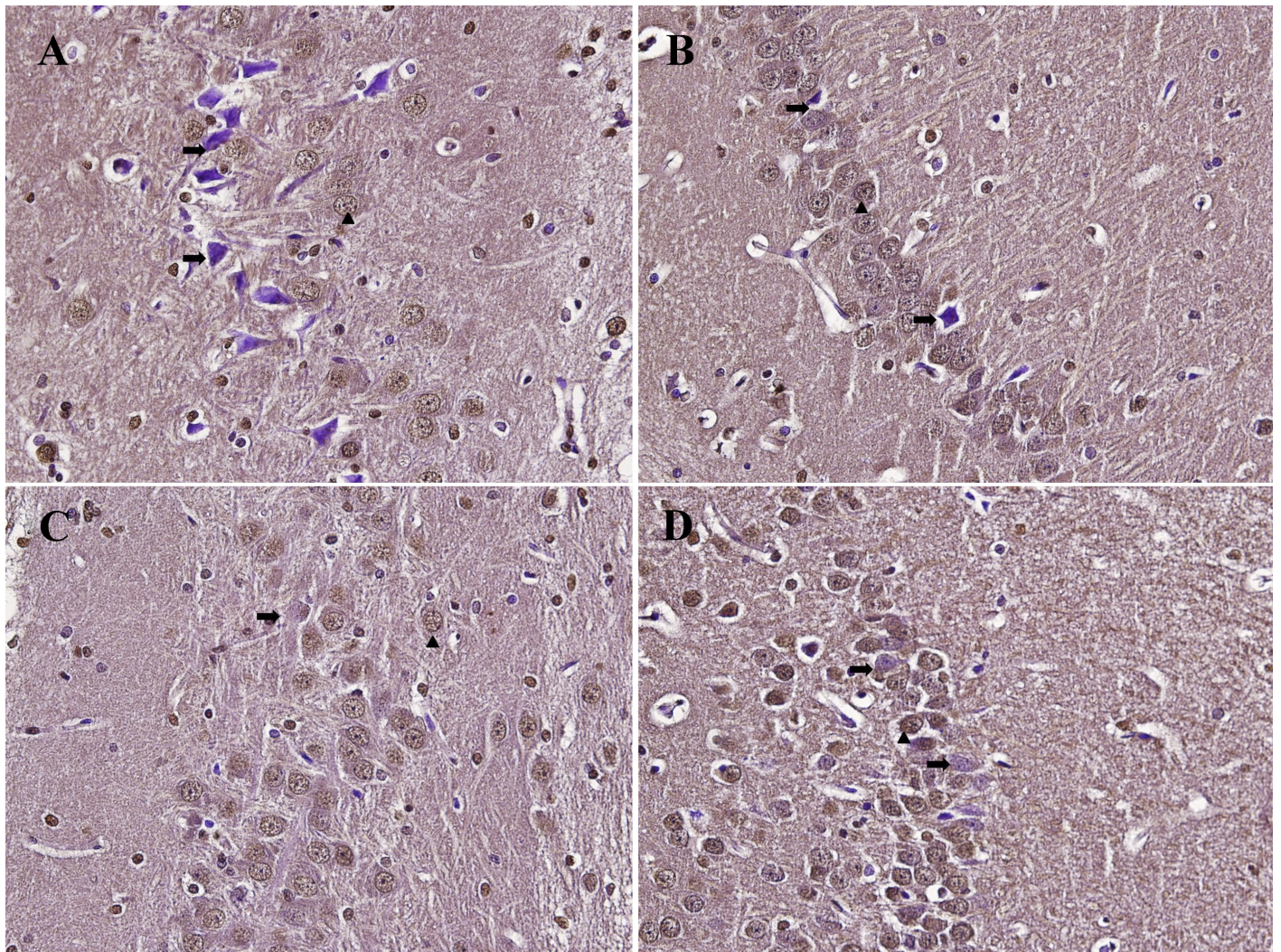


Figure 4. Hippocampus microphotographs (TUNELX200). (A: Group 1, B: Group 2, C: Group 3, D: Group 4) Normal pyramidal neurons (↑), degenerative pyramidal neurons (Δ)

in the rats given 10 mg/kg resveratrol treatment, MDA levels decreased (25). However, in our study, there was no difference between the MDA levels measured in the brain tissue of the rats between the treatment group and the control group. In our study, histopathological examination of the brain tissue revealed that, an improvement was observed in the neuron damage and degeneration, also apoptosis rate in the cortex and hypothalamus, compared to the control group. The underlying mechanism of the histopathological results is not clear because there was no statistically difference between oxidative stress parameter levels and we couldn't evaluate other cell survival path mechanisms, the anti-inflammatory process. The reason why for this statistically insignificant difference in oxidative stress levels might be the time of the measurement which was done in a 48-hour period at study protocol. It is thought that similar effects can be detected by prolonging the treatment period.

Our study results showed CO poisoning caused significant histopathological damage in heart tissue like in brain and

administration of resveratrol made significant positive effects. Few studies are available on the role of apoptosis in heart damage caused by CO. In a study, it was shown that myocardial apoptosis occurs after CO poisoning in rats and erythropoietin administration has been shown to have a beneficial effect in apoptosis suppression and myocardial healing (26). In another study, resveratrol administration reduced myocyte apoptosis by up-regulation of Akt protein, one of the main pathophysiological ways of apoptosis down-regulation (27). According to study results, compared to the control group, a significant improvement in the rate of myocyte apoptosis and a decrease in myocyte degeneration were found in the group treated with resveratrol. Lin et al. showed that giving Resveratrol (10 mg/kg) for four weeks following ischemia/reperfusion reduced infarction size and improved left ventricle systolic and diastolic function by reducing reduction of atrial natriuretic peptide and transforming growth factor- β 1 which are known to protect the heart from detrimental remodelling (28). Although the underlying mechanism is not clarified, the positive effect

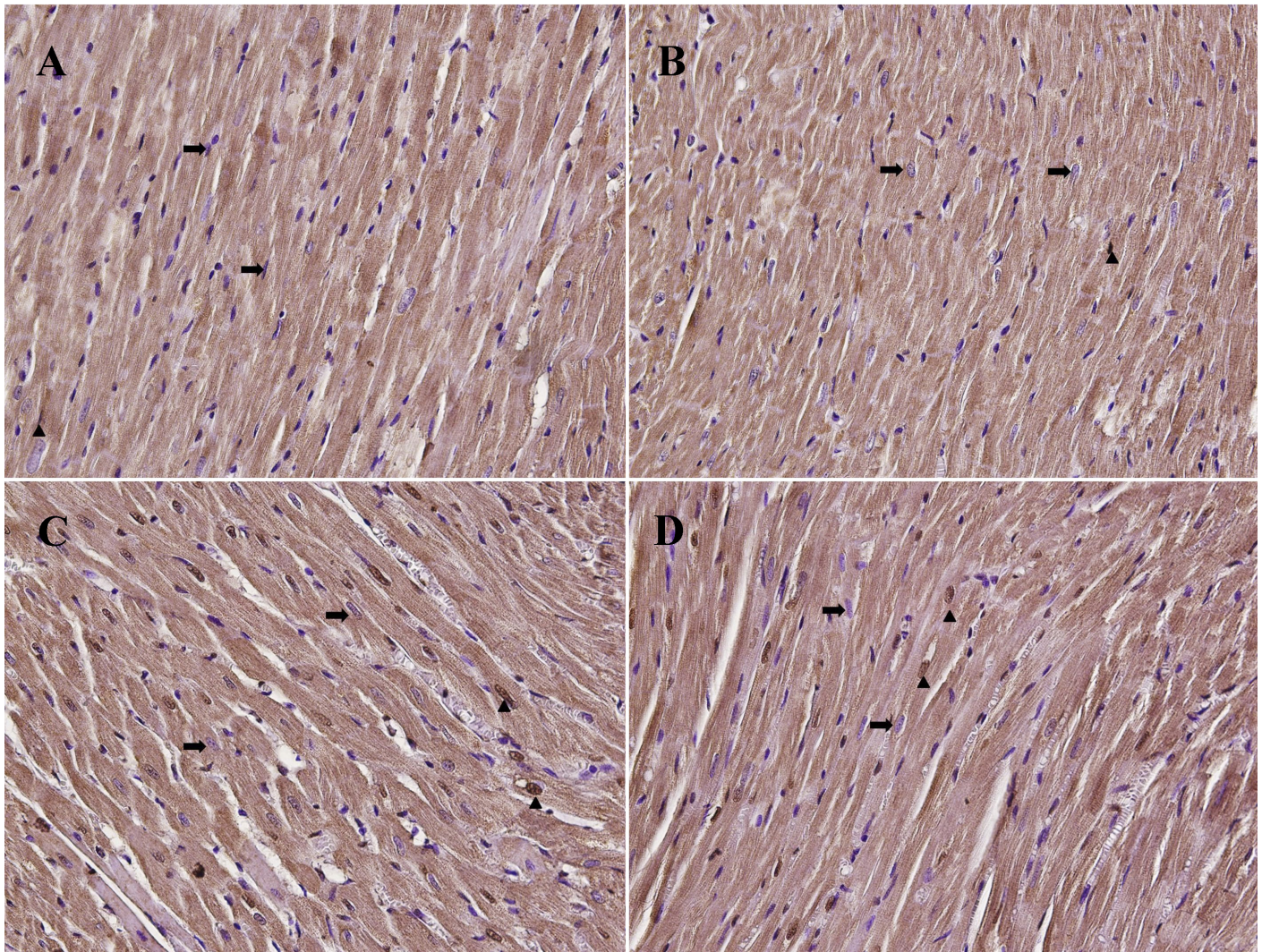


Figure 5. Myocardial tissue microphotographs (TUNELX200). (A: Group 1, B: Group 2, C: Group 3, D: Group 4) Normal myocytes (t), apoptotic myocytes (Δ)

of resveratrol on heart tissue may be mediated by via many different mechanisms showed in literature including free radical scavenging, increasing glutathione peroxides, decreasing the expression level of Akt proteins and pre-apoptotic proteins (29). Also other therapies can decrease damage in brain and heart tissue due to oxidative stress. In a study, Wang et al. showed that a hydrogen-rich saline solution reduced lipid peroxidation in brain tissue, and that it may thus exhibit a positive effect on neurological sequelae (30). Another study showed that N-acetylcysteine and melatonin reduced brain and lung damage caused by CO (31).

There are a number of limitations to this study. The first involves a limitation in the application of resveratrol treatment in the experimental protocol. Resveratrol was applied in a single standard dose for 48 h immediately after CO exposure. This was in order not to exceed the experimental animal and group numbers within the framework of the 3R ethical rules (32). Our

research therefore provides no information concerning the ameliorating effect of resveratrol at different doses and in the late period following exposure to CO. A longer treatment period or the administration of higher doses might result in a further increase in the ameliorating effect of resveratrol. A second limitation was that there was no significant difference between the control and study groups in terms of biochemical oxidant and antioxidant parameters, despite the presence of a factor such as CO that caused significant oxidative damage. There may be several reasons for this. The first is that these measurements only being capable of being taken at the end of the treatment protocol may have led to us being unable to detect this variation occurring in association with CO. Secondly, these parameters were only measured in serum, and tissue level measurement might have revealed this difference more clearly. In the light of these results, the antioxidant effect of resveratrol in improving CO damage could not be shown. The third limitation is that parameters such as the inflammatory markers TNF- α , NF κ B and

interleukin that might have helped better clarify the mechanism underlying the healing effect of resveratrol could not be measured.

In conclusion, our study results show that the application of resveratrol in an experimental animal model may be useful in reducing damage in brain and heart tissue developing secondary to CO poisoning.

REFERENCES

- Bojakowski K, Gaciong Z, Grochowicki T, Szmidi J. Carbon Monoxide May Reduce Ischemia Reperfusion Injury: A Case Report of Complicated Kidney Transplantation From a Carbon Monoxide Poisoned Donor. *Transplant Proc* 2007;39:2928-2929. [CrossRef]
- Gorman DF. Carbon monoxide: From toxic poison to brain messenger. *S Pac Underwater Med Soc J* 1995;25:77. https://scholar.google.com/scholar?cluster=13806997695340807464&hl=tr&as_sdt=0,5
- Chiew AL, Buckley NA. Carbon monoxide poisoning in the 21st century. *Crit Care Med* 2014;18:221. <https://doi.org/10.1186/cc13846>
- Tomaszewski C. Carbon Monoxide. In: Goldfrank's Toxicologic Emergencies, 8th ed. Flomenbaum NE, Goldfrank LR, Hoffman R, Howland MA, Lewin NA, Nelson LS, editors. New York: Mc Graw-Hill; 2006.
- Roderique JD, Josef CS, Feldman MJ, Spiess BD. A modern literature review of carbon monoxide poisoning theories, therapies, and potential targets for therapy advancement. *Toxicology* 2015;334:45-58. [CrossRef]
- Hampson NB, Hauff NM. Risk factors for short-term mortality from carbon monoxide poisoning treated with hyperbaric oxygen. *Crit Care Med* 2008;36:2523-2527. [CrossRef]
- Jardim FR, de Rossi FT, Nascimento MX, et al. Resveratrol and Brain Mitochondria: a Review. *Mol Neurobiol* 2018;55:2085-2101. [CrossRef]
- Soleas GJ, Diamandis EP, Goldberg DM. Resveratrol: a molecule whose time has come? And gone? *Clin Biochem* 1997;30:91-113. [CrossRef]
- Bonnefont-Rousselot D. Resveratrol and Cardiovascular Diseases. *Nutrients* 2016;8:250. [CrossRef]
- Turedi S, Yilmaz SE, Mentese A, et al. The diagnostic value of serum ischemia-modified albumin levels in experimentally induced carbon monoxide poisoning and their correlation with poisoning severity. *Acad Emerg Med* 2013;20:652-658. [CrossRef]
- Kim J, Shin W. How to Do Random Allocation (Randomization). *Clin Orthop Surg* 2014;6:103-109. [CrossRef]
- Chavez E, Reyes-Gordillo K, Segovia J, et al. Resveratrol prevents fibrosis, NF-kappaB activation and TGF-beta increases induced by chronic CCl4 treatment in rats. *J Appl Toxicol* 2008;28:35-43. [CrossRef]
- Yulug E, Turedi S, Karaguzel E, Kutlu O, Mentese A, Alver A. The short term effects of resveratrol on ischemia-reperfusion injury in rat testis. *J Pediatr Surg* 2014;49:484-489. [CrossRef]
- Garman RH. Histology of the central nervous system. *Toxicol Pathol* 2011;39:22-35. [CrossRef]
- Kesim M, Yulug E, Kadioglu M, et al. The effect of simvastatin on picrotoxin-induced seizure in mice. *J Pak Med Assoc* 2012;62:1187-1191. https://jpma.org.pk/article-details/3800?article_id=3800
- Tokatli F, Uzal C, Doganay L, et al. The potential cardioprotective effects of amifostine in irradiated rats. *Int J Radiat Oncol Biol Phys* 2004;58:1228-1234. [CrossRef]
- Chang JE, Kim HJ, Jheon S, Lim C. Protective effects of GV1001 on myocardial ischemiareperfusion injury. *Mol Med Rep* 2017;16:7315-7320. [CrossRef]
- Hu Huang SS, Tsai MC, Chih CL, Hung LM, Tsai SK. Resveratrol reduction of infarct size in Long-Evans rats subjected to focal cerebral ischemia. *Life Sci* 2001;69:1057-1065. [CrossRef]
- Weaver LK. Carbon monoxide poisoning. *New Engl J Med* 2009;360:1217-1225. [CrossRef]
- Wang P, Zeng T, Zhang CL, et al. Lipid peroxidation was involved in the memory impairment of carbon monoxide induced delayed neuron damage. *Neurochem Res* 2009;34:1293-1298. [CrossRef]
- Satran D, Henry CR, Adkinson C, Nicholson CI, Bracha Y, Henry TD. Cardiovascular manifestations of moderate to severe carbon monoxide poisoning. *J Am Coll Cardiol* 2005;45:1513-1516. [CrossRef]
- Pineda-Ramirez N, Gutierrez Aguilar GF, Espinoza-Rojo M, Aguilera P. Current evidence for AMPK activation involvement on resveratrol-induced neuroprotection in cerebral ischemia. *Nutr Neurosci* 2018;21:229-247. [CrossRef]
- Gomez SS, Sahin TD, Yazir Y, et al. Resveratrol prevents cognitive deficits by attenuating oxidative damage and inflammation in rat model of streptozotocin diabetes induced vascular dementia. *Physiol Behav* 2019;201:198-207. [CrossRef]
- Andrade S, Ramalho MJ, Carmo Pereira MD, Loureiro JA. Resveratrol Brain Delivery for Neurological Disorders Prevention and Treatment. *Front Pharmacol* 2018;9:1261. [CrossRef]
- Tabrizian K, Shahraki J, Bazzi M, Rezaee R, Jahantigh H, Hashemzaei M. Neuro-Protective Effects of Resveratrol on Carbon Monoxide-Induced Toxicity in Male Rats. *Phytother Res* 2017;31:1310-1315. [CrossRef]
- Rezaee MA, Mohammadpour AH, Imenshahidi M, et al. Protective effect of erythropoietin on myocardial apoptosis in rats exposed to carbon monoxide. *Life Sci* 2016;148:118-124. [CrossRef]
- Hashemzaei M, Barani AK, Iranshahi M, et al. Effects of resveratrol on carbon monoxide-induced cardiotoxicity in rats. *Environ Toxicol Pharmacol* 2016;46:110-115. [CrossRef]
- Lin J-F, Lin S-M, Chih C-L, et al. Resveratrol reduces infarct size and improves ventricular function after myocardial ischemia in rats. *Life Sci* 2008;83:313-317. [CrossRef]
- Bastianetto S, Ménard C, Quirion R. Neuroprotective action of resveratrol. *Biochim Biophys Acta* 2015;1852:1195-1201. [CrossRef]
- Wang W, Li Y, Ren J, Xia F, Li J, Zhang Z. Hydrogen rich saline reduces immunemediated brain injury in rats with acute carbon monoxide poisoning. *Neuro Res* 2012;34:1007-1015. [CrossRef]
- Kekce Z, Seydaoglu G, Sever H, Ozturk F. The effect of antioxidants (N-acetylcysteine and melatonin) on hypoxia due to carbon monoxide poisoning. *Bratisl Lek Listy* 2010;111:189-193. <https://pubmed.ncbi.nlm.nih.gov/20586144/>
- Fenwick N, Griffin G, Gauthier C. The welfare of animals used in science: how the "Three Rs" ethic guides improvements. *Can Vet J* 2009;50:523-530. <https://www.ncbi.nlm.nih.gov/pmc/articles/PMC2671878/>

Compliance with Ethical Standards: Karadeniz Technical University Faculty of Medicine Animal Experiments Ethics Committee (protocol no: 2016/18)

Peer-review: Externally peer-reviewed.

Author Contributions: Concept - AS; Design - AS, OT; Supervision - OT, YK; Fundings - YK; Materials - EY, SCK; Data Collection and/or Processing - SP, MC; Analysis and/or Interpretation - AM, MC; Literature Search - AS, SP; Writing Manuscript - AS, SP, MC; Critical Review - AS, YK, OT

Conflict of Interest: No conflict of interest was declared by the authors.

Financial Disclosure: The authors declared that this study has received no financial support.