



Case Report

J Exp Clin Med
2021; 38(4): 693-695
doi: 10.52142/omujecm.38.4.52

A case report of atypical Ramsay-Hunt Syndrome presented with severe vertigo and vomiting

Kemal KEF

Department of Otolaryngology, Private Kesan Hospital, Edirne, Turkey

Received: 19.03.2021

Accepted/Published Online: 31.03.2021

Final Version: 30.08.2021

Abstract

Ramsay-Hunt Syndrome (Herpes zoster oticus) is often characterized by severe ear pain, vesicles on external auditory canal or auricula and peripheral facial paralysis. However, the patient in this case presented to the clinic with dizziness, pain in the ear and vomiting. During the physical examination there was no vesicles and no evidence of skin changes found around the auricula that were typical for Ramsay Hunt syndrome. The patient did not have facial paralysis. If there is an unexpected severe ear pain accompanying vertigo, Ramsay Hunt syndrome should be considered in the differential diagnosis even if there is no rash or facial paralysis.

Keywords: acyclovir, Herpes zoster oticus, vertigo, vomiting

1. Introduction

Ramsay-Hunt Syndrome (Herpes zoster oticus) is often characterized by severe ear pain, vesicles on external auditory canal or auricula and peripheral facial paralysis. The syndrome is named after the American neurologist, James Ramsay Hunt; the first person to describe the relationship between facial paralysis and typical vesiculopathy in Ganglion's geniculitis, ear canal, and auricular concha (1). However, paralysis can be seen in other cranial and cervical nerves (due to anastomoses in between). Vesicles can be seen in various portions of the skin, inside the mouth or on the uvula (2, 3). Symptoms such as disfunctions in hearing and balance, defects in sense of taste, decreased secretion of tear and saliva, trouble in senses should come to mind with motor, autonomic and sensory nerve paralysis.

Although the clinical symptoms of primary Varicella infection had during and after early childhood completely disappears the virus settles into cranial and spinal nerve ganglions (4, 5). When the immune system weakens, the virus gets activated and reproduces. Vesicles occur-ring on the skin and nerves effected depends on the ganglion on which the virus settles into (6).

Facial paralysis and vesicles are the primary characterization of the Ramsay-Hunt Syndrome. The aim of this case report is to present an atypical case of Ramsay-Hunt Syndrome who was presented with severe vertigo, ear pain, vomiting and no facial paralysis.

2. Case report

2.1. Patient information

A 55-year-old female patient living in a rural area, in a family

that works in agricultural and stock farming. Physical labor and fatigue were thought to explain the patient's vertigo. She had never consulted to a clinic from a similar complaint.

2.2. Clinical findings

Nystagmus, balance disorder, and positive Romberg test were found during the physical examination confirming vertigo. The patient vomited during the examination due to vertigo. Earache remained unexplained after the patient refused radiological imaging due to her economic condition.

2.3. Timeline

A 55-year-old female patient was presented to the clinic with nausea, vomiting, severe vertigo and pain in her left ear. Physical examination showed no vesicles in the ear canal or the auricular concha. Hearing loss was not present. A through anamnesis showed no history of a similar disease or an indication of a previous viral infection. The disease seemed to have an acute onset due to an increase in her physical workload.

2.4. Diagnostic assessment

Audiometry and tympanometry tests were normal. The patient re-fused radiological imaging (MRI to assess cranial nerve involvement for the earache) due to her economic condition. The lack of imaging which reveals the incidence of nerve edema typical of Ramsay Hunt syndrome caused a delay in the diagnosis of the syndrome until the rash-es developed. Facial paralysis improved without sequelae, but early treatment can be started with radiological imaging and better treatment can be provided. Otherwise, a delay in the anti-viral therapy could cause sequelae.

2.5. Therapeutic intervention

The patient was hospitalized due to severe vertigo, nausea, and vomiting. After 2 days of hospitalization, vesicles in right auricular concha (Fig. 1a) and type 4 House-Brackmann peripheral facial paralysis on her right side (Fig. 1b and 1c) occurred. Acyclovir (5 mg/kg IV, 8-hour intervals), Prednisone (80 mg/day for 3 days, 30mg for the following 10 days) were added to the patient's anti-vertiginous and analgesic treatment. Superficial Rifocin and antibiotic pomade applications were performed to prevent secondary infections of vesicles on the skin. Patient's vertigo disappeared after day 5 of hospitalization. Facial paralysis started to recover on the 7th day. On day 10, the vesicles recovered completely (Fig. 2A). At the end of the second week, facial paralysis disappeared without any sequela (Fig. 2B and 2C).

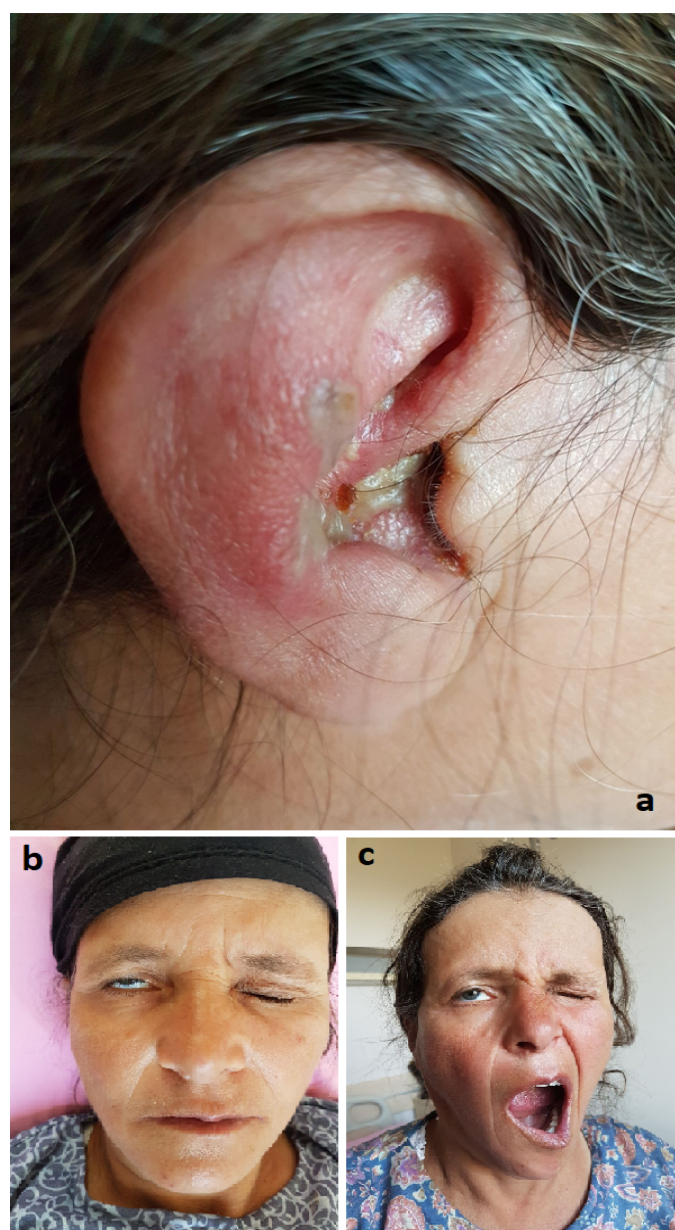


Fig. 1 (a) Vesicles in right auricular concha; (b) and (c) House-Brackmann peripheral facial paralysis on her right side

2.6. Follow-up and outcomes

Romberg test and other neurological examination showed normal results after the fifth day of hospitalization. Patient's complaints related to vertigo disappeared. Follow-up examination on the 15th day of discharge showed no sign of sequelae caused by facial paralysis and no skin abnormalities where the vesicles were located.

2.7. Patient perspective

The patient did not give any negative feedback about the drug use, hospitalization, and follow-up examinations. The patient was thankful for the total recovery without any sequela.

2.8. Informed consent

Informed consent was obtained from all individual participants included in the study.

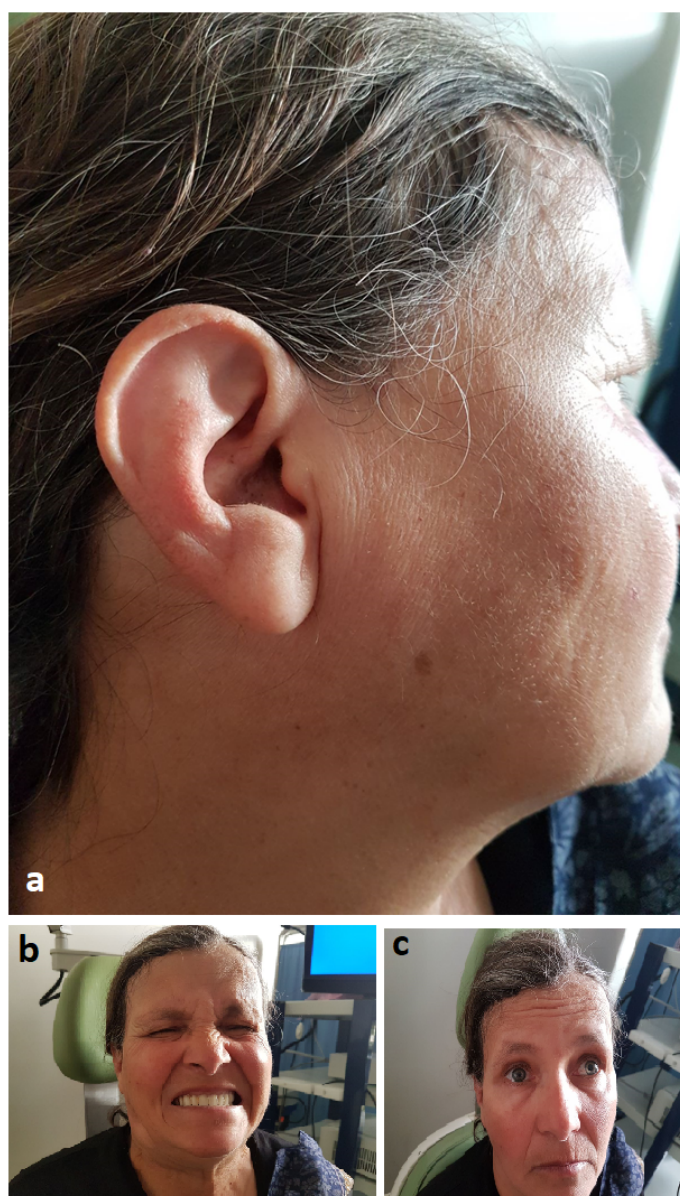


Fig. 2 (a) Recovered vesicles (b) and (c) recovered facial paralysis

3. Discussion

After a previous Varicella zoster virus infection, the virus remains in the motor and sensory nerve ganglions inactively (7). The Virus gets activated following immune suppressing diseases and reproduces quickly. Ramsay-Hunt Syndrome occurs in 1% of the Varicella zoster infections. Primary characteristics of the syndrome include peripheral facial paralysis and typical, painful vesicles in the ear. However cranial polyneuropathy may be seen when the 5th, 9th, 10th cranial nerves and the 2nd, 3rd, 4th cervical nerves are infected (7). Pathological contrasting color may be seen at the facial nerve at the level of the internal acoustic canal during MRI with contrast. MRI with contrast could not be performed in this case due to patient's personal reasons. Ramsay Hunt Syndrome is the second most common cause of peripheral facial paralysis after Bell's palsy (7). The reason for presenting this case is contrary to typical symptoms the patient was presented with severe vertigo, nausea, and vomiting. Typical vesicle eruptions and facial paralysis developed later. Although facial paralysis developed from Ramsay Hunt syndrome has a lower rate of healing without any lesions of sequela compared to Bell's palsy, the patient has shown a full recovery without any lesions of sequela (3).

Virus eradication could not be reached. The biggest limitation was not being able to use radio-logical imaging. Although the literature indicates a high risk of sequela in cases with late diagnosis the facial paralysis improved without sequela in this case (8). Superficial Rifocin and antibiotic pomade applications were performed to prevent secondary infections of vesicles on the skin in addition to anti-viral therapy. This provided better results in the healing of skin lesions without any scars (9). Ramsay Hunt Syndrome should be considered in the differential diagnosis of vertigo cases with severe earache even if there is no rash or facial paralysis.

Conflict of interest

The author declared no conflict of interest.

Acknowledgments

None to declare.

References

- Hunt JR. On herpetic inflammations of the geniculate ganglion. A new syndrome and its complications. *Arch Neurol.* 1968;18(5):584–589. doi:10.1001/archneur.1968.00470350143016
- Sweeney CJ, Gildeen DH. Ramsay Hunt syndrome. *J Neurol Neurosurg Psychiatry.* 2001 Aug;71(2):149-154. doi: 10.1136/jnnp.71.2.149.
- Yetişer S, Tosun F, Satar B, Özkaptan Y. Herpes Zoster Oticus Oral Asiklovir tedavisi sonuçları. *Otoskop* 2002; 1:19-23.
- Walther LE, Prosowsky K, Walther A, Gudziol H. Untersuchungen zum Zoster oticus [Herpes zoster oticus: symptom constellation and serological diagnosis]. *Laryngorhinootologie.* 2004 Jun;83(6):355-362. German. doi: 10.1055/s-2004-814105.
- Schrader A, Stickel H. Virale und bakterielle Infektionen des Zentralnervensystem. In: Neundörfer B, Schimrigk K, Soyka D (eds): *Praktische Neurologie, Band 6* Weinheim: VCH; 1988, p. 149-157.
- Baba M, Seçkin D, Eryılmaz A, Gençay S. Atipik Seyirli Ramsay Hunt sendromlu bir olgu. *Türkderm* 2006;40(Özel ek B); B80-81.
- Kennedy PG. Varicella-zoster virus latency in human ganglia. *Rev Med Virol.* 2002 Sep-Oct;12(5):327-334. doi: 10.1002/rmv.362. PMID: 12211045.
- de Mendonca Vaz R, Linthicum FH Jr. Ramsay hunt syndrome: a histopathologic observation of a facial sequela. *Otol Neurotol.* 2009 Apr;30(3):428-9. doi: 10.1097/MAO.0b013e318180a481.
- Waldman RA. Ramsay Hunt Syndrome Type 2: A Review of an uncommon and unwelcome neurodermatologic disease. *J Otolaryngol Rhinol.* 2015 Dec;31;1(1). <https://doi.org/10.23937/2572-4193.1510003>.