



Research Article

Ultrasonographic Measurements of the Bulbus Oculi of the Camel

Firuze TÜRKER¹, Komal KHAN^{1*}

¹Anatomy Department, Veterinary Faculty, Adnan Menderes University, Aydın, Turkey

ABSTRACT

Ophthalmic ultrasonography is considered a useful modern tool to quantify the ocular dimensions. The main aim of this study was to give information about the ultrasonographic measurements of the normal hybrid camel eye. Besides, to calculate some indices of the camel eye and discuss them in comparison with the ocular measurements of other animals reported previously. Fourteen formalin-preserved eyeballs were subjected to corneal ocular ultrasonographic examination in horizontal imaging plane. The ultrasonographic results of the eyeballs showed 95% confidence intervals for measurements as corneal thickness (CT) (1.56-1.87), anterior chamber depth (ACD) (2.33-4.27), lens thickness (LT) (6.81-10.00), vitreous chamber depth (VCD) (23.01-24.44), axial length (AL) (35.13-38.60), and optical axis (OA) (34.89-37.24). Indices also showed that 95% confidence interval ranges were as CT/AL (0.04-0.05), ACD/AL (0.06-0.11), LT/AL (0.19-0.26), VCD/AL (0.62-0.66) and OA/AL (0.96-1.00). This knowledge of the normal ocular dimensions may especially be helpful in the diagnosis of the deviation from normal eye and progression towards any ocular problem in the camel.

Keywords: camel, corneal index, eyeball, ophthalmology, ultrasound

Devede Bulbus Oculi'nin Ultrasonografik Ölçümleri

ÖZET

Oftalmik ultrasonografi, oküler boyutları ölçmek için kullanışlı modern bir cihaz olarak kabul edilmektedir. Bu çalışmanın ana amacı, melez deve gözünün ultrasonografik ölçümleri hakkında bilgi vermektir. Bunun yanında deve gözünün bazı indekslerini hesaplamak ve bunları daha önce kayıt altına alınmış hayvanların oküler ölçümleriyle karşılaştırarak tartışmaktır. Formalin ile fikzasyonu yapılmış 14 göz küresi, horizontal görüntüleme düzleminde korneal oküler ultrasonografik incelemeye tabi tutuldu.

Göz kürelerinin ultrasonografik sonuçları (%95 güven aralığında); kornea kalınlığı (CT) (1.56-1.87), ön kamara derinliği (ACD) (2.33-4.27), lens kalınlığı (LT) (6.81-10.00), vitröz kamara derinliği (VCD) (23.01-24.44), eksenel uzunluk (AL) (35.13-38.60) ve optik eksen (OA) (34.89-37.24) olarak bulundu.

Ayrıca indeksler (%95 güven aralığında); CT/AL (0,04-0,05), ACD/AL (0,06-0,11), LT/AL (0,19-0,26), VCD/AL (0,62-0,66) ve OA/AL (0,96-1,00) hesaplandı. Devede, oküler boyutların bilinmesi, normal göz boyutlarından sapmalar ve herhangi bir oküler sorunun ilerlemesinin teşhisinde yardımcı olabilir.

Anahtar kelimeler: Deve, korneal indeks, göz küresi, oftalmoloji, ultrason

*Corresponding author: Komal KHAN, Anatomy Department, Veterinary Faculty, Adnan Menderes University, Aydın, Turkey, e-mail: komal.khan@uvas.edu.pk

Received Date: 05.04.2021 – Accepted Date: 05.05.2021

Introduction

The knowledge of ocular status and visual acuity is important factor for the good performance of any animal. Optical biometry is an important technique for the assessment of normal healthy eyes and appendages but it has a limitation of requiring good optical pathway to get accurate results. It seems impossible to meet this criteria in some pathological conditions. The ophthalmic ultrasonography is considered useful modern tool to quantify the ocular dimensions instead of direct clinical measurements. This technique is preferred because of its safety and non-invasiveness (Dudea, 2011). So, ultrasonography seems a good approach where use of ophthalmoscopy is unimpressive (Holladay, 2009).

A-mode (amplitude modification) is most commonly used in research oriented studies (Oliver, 2008) but B-mode (brightness modification) ultrasonography is preferred in clinical ophthalmology for two-dimensional cross-section unveiling of an organ. It shows amplitude of returned echoes as dots (Mirshahi et al., 2014) while A-mode shows amplitude as spikes on horizontal line (Oliver, 2008). A probe of the B-scan can also generate charismatic image of the eye as it transmits multiple sound waves (Solarte & Shaikh, 2007). Another crucial

excess formalin. The eyeballs were then engrossed in water bath and ultrasonography was performed. B-mode ultrasound scanner (Esaote MyLab 30 Vet) was used, which accepted linear transducer with 8 MHz.

Trans-corneal method was applied with gel on surface of cornea to measure different dimensions of eye. The probe was settled at right angle to mid of cornea. The sound waves reflected from eyeball were recorded on attached computer screen. Recordings were made when posterior wall of eyeball was visualized (Kassab, 2012). The corneal thickness (CT) was measured from anterior to posterior surfaces of the cornea. The lens thickness (LT) was calculated from anterior to posterior surface of the lens. The anterior chamber depth (ACD) was assessed from the distance between posterior corneal surface and anterior lens surface. The vitreous chamber depth (VCD) was computed as distance between posterior lens surface and the retina. The axial length (AL) was the straight distance from anterior surface of the cornea to the retina (Kassab, 2012; Osuobeni & Hamidzada, 1999). Optical axis (OA) was measured as the length starting from anterior surface of the cornea up to the optic nerve papilla (Lehmkuhl et al., 2010). All the measurements were made in millimeters. The ultrasonographic image and measurements are shown in the Figure 1 (A and B).

Table 1. Direct measurements (Mean \pm Standard Deviation) of the ocular dimensions of the hybrid camel through ultrasonography

Eyeball Measurements	Mean \pm SD (mm)	95% Confidence Intervals
CT	1.71 \pm 0.66	1.56-1.87
ACD	3.3 \pm 1.051	2.33-4.27
LT	8.41 \pm 1.73	6.81-10.34
VCD	23.72 \pm 0.77	23.01-24.44
AL	36.86 \pm 1.87	35.13-38.60
OA	36.06 \pm 1.27	24.89-37.24

Corneal thickness (CT), Anterior Chamber Depth (ACD), Lens Thickness (LT), Vitreous Chamber Depth (VCD), Axial Length (AL), Optical Axis (OA).

component of these devices is transducer and generally, linear transducers having 7.5 to 10 MHz frequency are used for ocular measurements (Dudea, 2011).

Improvements in the technology has proved ocular ultrasound biometry as useful tool in different animals like dolphin (Cartee et al., 1995), goat (Ribeiro et al., 2009), horse (Gialletti et al., 2018; Sorouri et al., 2009), Indian camel (Kelawala et al., 2015) and also in birds like parrot (Lehmkuhl et al., 2010). There are some studies related to ultrasonography of one-humped camel eyes, even showing comparison with other animals like buffalo (Kassab, 2012). So, the objective of this study was firstly, to get ocular measurements of hybrid camel "Tülü" (Çalişkan, 2016). by using ultrasonographic imaging modality and then, figure out some indices and compare those results with already available data so far.

Material and Methods

Total 14 eyes of the seven hybrid male camels were obtained from local slaughterhouse. The carcass weight of the camels were 380.29 \pm 45.45 kg. The both right and left eyes (n = 14) were collected initially dissecting through the conjunctiva of the upper and lower eyelids. Optic nerves were detached close to their exit from eyeballs. Newly unfolded camel eyes were then trimmed carefully to remove fat, extra ocular muscles and other tissues. After dissection the eyes were immersed in 10% formaldehyde solution and kept at 4 °C up to the study. Before examination, eyes were kept under running water to remove

Some indices like CT/AL, ACD/AL, LT/AL, VCD/AL and OA/AL were also determined. The statistical analyses was performed using the Statistical Package for the Social Sciences (SPSS) 16.0 for Windows (SPSS Inc, Chicago, IL, USA). The right and left side data were pooled to calculations. Data was expressed as mean \pm standard deviation. The 95% confidence intervals were also calculated for all the optical measurements.

Results

Ultrasonographic measurements of right and left eyeballs showed that 95% confidence intervals for CT, ACD, LT, VCD, AL and OA were 1.56-1.87, 2.33-4.27, 6.81-10.00, 23.01-24.44, 35.13-38.60 and 24.89-37.24, respectively. Indices also showed that 95% confidence interval ranges were as 0.04-0.05, 0.06-0.11, 0.19-0.26, 0.62-0.66 and 0.96-1.00, respectively. These values are mentioned along with their means and standard deviations in the Table 1 and 2.

Discussion

Ultrasonographic eye measurements are generally presented as direct dimensions (Kelawala et al., 2015; Osuobeni & Hamidzada, 1999; Yadegari et al., 2013). However, in morphometric evaluations, indices are more reliable than diameters because they are independent of the size (Kara et al., 2011). For this reason, index values for hybrid camel eye ultrasonographic measurements are presented in this study. These results were especially important in the veterinary clinics

Table 2. Indices of the hybrid camel eye calculated from the ocular measurements

Indices	Mean \pm SD	95% Confidence Intervals
CT/AL	0.05 \pm 0.004	0.04-0.05
ACD/AL	0.09 \pm 0.031	0.06-0.12
LT/AL	0.23 \pm 0.036	0.19-0.26
VCD/AL	0.64 \pm 0.022	0.62-0.66
OA/AL	0.97 \pm 0.026	0.96-1.00

for camels, because they deal with different camel breeds of various sizes.

The ultrasonographic appearance of the hybrid camel eye was just like the camel studies reported previously by Kelawala et al. (2015) and Yadegari et al. (2013). The anterior and posterior surfaces of the cornea and the lens appeared to be hyper echoic. The aqueous, vitreous humors and the central part of the lens were seemed anechoic.

As the assessment was made on the indices, corneal thickness index and lens thickness index were measured exactly similar

equine, caprine and Persian cat (Kassab, 2012; Mirshahi et al., 2014; Potter et al., 2008). The Persian cat was having very much smaller ACD/AL than the camel (Mirshahi et al., 2014). The LT/AL of both young and adult buffalo was similar but cattle, horse, goat and cat were having very much bigger LT/AL than the hybrid camel (Kassab, 2012; Mirshahi et al., 2014; Potter et al., 2008; Sorouri et al., 2009).

While looking for the comparison with birds, the parrot showed higher values for both the ACD/AL and LT/AL but very much smaller optical axis index (OA/AL) than the camel (Lehmkuhl et al., 2010). Besides, humans possessed same ACD/AL for the eye

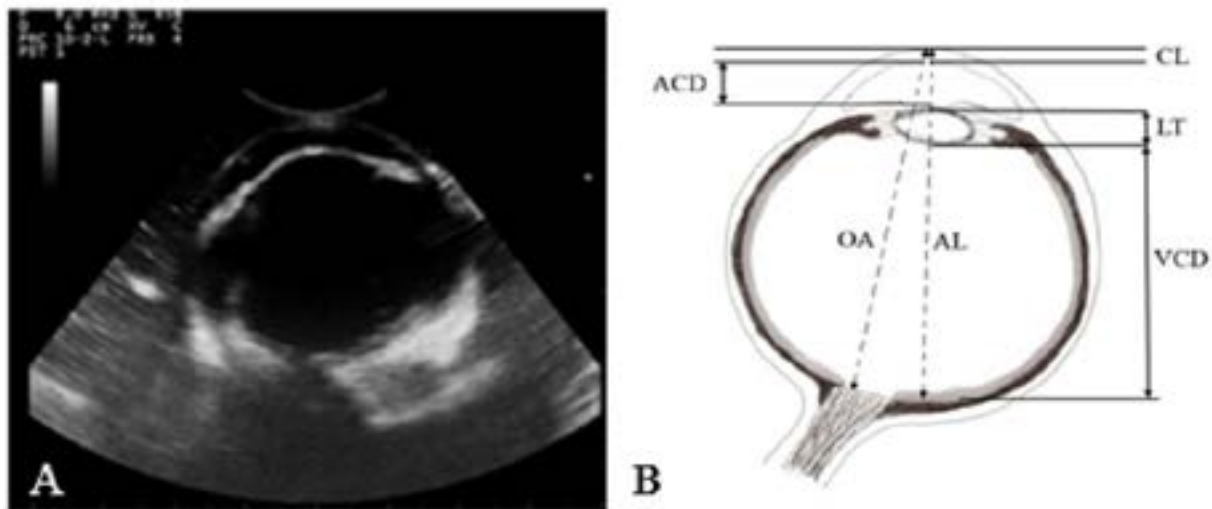


Figure 1 (A). B-mode ultrasonography of the camel showing ocular measurements.

Figure 1 (B). showing schematic diagram of the camel eye measurements. Corneal Thickness (CT), Anterior Chamber Depth (ACD), Lens Thickness (LT), Vitreous Chamber Depth (VCD), Axial Length (AL), Optical Axis (OA).

to that of the adult one-humped camel but young camel was having little thinner cornea (Kassab, 2012) as compared to our camel. For camel in their studies, Yadegari et al. (2013) and Kelawala et al. (2015) found very much greater lens index than the recent study. The value of ACD/AL was very much bigger while VCD/AL of adult one-humped camel were found very much smaller in size by Kassab (2012), Kelawala et al. (2015) and Yadegari et al. (2013) than that of the hybrid camel. But the ACD/AL of eye of the hybrid camel appeared same as that of the young camel.

In comparison with other large animals, the calculations indicated that adult buffalo (Kassab, 2012) and Jersey cattle were having same corneal index but Holstein Friesian cattle was having higher than that of the hybrid camel (Potter et al., 2008). In recent study, the measurement of the ACD/AL of the camel was little smaller than the buffalo and goat but similar to the cattle and miniature horse. Unlikely, the VCD/AL was found very much larger in our studied camel than that of the bovine,

(Quan-hao et al., 2007) as the camel.

In a study by Osuobeni & Hamidzada (1999), available data about the indices showed that the ACD/AL and LT/AL ratios of the hybrid camel were smaller as compared to the humans (0.16), one-humped camel (0.17 and 0.35) horse, cow (0.15 and 0.31-0.34) and cat (0.40). The VCD/AL ratio in present study was perceived greater than the one-humped camel (0.48), horse (0.55) and cow (0.51) but smaller than in the humans i.e. about 0.70.

In general, the animals are having larger ocular dimensions than the human especially thicker lens make them more efficient to focus light on the retina. The differences in measurements between camel and other larger animals could be attributed to the fact that a compensatory mechanism might have been adopted by "the ship of the desert" for the harsh and dry weather conditions, to keep the eyes in proper shape while facing powerful winds over there. The variation between camel

and small animals could be ascribed to the smaller skull and orbit size of them. Moreover, these differences could have been influenced by the age of different animals as seen by Kassab (2012) and Hashemi et al. (2012) in camel and humans, respectively. Besides, there was no impact seen by the gender on eyeball of the goat by Ribeiro et al. (2010), so this concept can be rejected or must be studied in detail for other animals as well.

This study has some limitations that preserved eyeballs had been used and the number of camels was not sufficient. It was seen in the research by Tran et al. (2017), performed recently on the formalin-fixed eye samples, that there was only negligible shrinkage in tissue. Therefore, this fixation point can be neglected. Also, we are giving indices so the shrinkage effect can be ignored.

In conclusion, the present study revealed ocular measurements of the hybrid camel using ultrasound B-mode technique. Ultimately, the knowledge of the optical dimensions will help veterinary clinicians in understanding problems related to the vision of camels. Moreover, ocular ultrasonography could prove to be a complementary technique in diagnosis of the ocular problems in routine clinical cases as well. In future more reliable results could be generated if the limitations of this study could possibly be eradicated. These outcomes should also be compared with the research performed in the live hybrid camel to increase their authenticity.

Acknowledgements

We are thankful to slaughterhouse (Veterinarian Ali Ibrahim Bağdatlıoğlu, Aydın) from where camel eyes were obtained and Dr. Cevdet Peker, Faculty of Veterinary Medicine Adnan Menderes University, Aydın, Turkey, for providing assistance in this research work.

Conflict of interest

The authors declare that they have no conflict of interest in this study.

References

- Çalışkan, V. (2016). A World Cultural Heritage: Anatolian Camel Dealing Culture and Camel Wrestles. *Ankara: Incirliova Municipality*, (pp. 32).
- Cartee, R., Brosemer, K., & Ridgway, S. (1995). The Eye of the Bottlenose Dolphin (*Tursiops truncatus*) Evaluated by B Mode Ultrasonography. *Journal of Zoo and Wildlife Medicine*, 26(3), 414-421.
- Dudea S. M. (2011). Ultrasonography of the eye and orbit. *Medical Ultrasonography*, 13(2), 171-174.
- Gialletti, R., Marchegiani, A., Valeriani, T., Nannarone, S., Beccati, F., Fruganti, A., & Laus, F. (2018). A survey of ocular ultrasound abnormalities in horse: 145 cases. *Journal of Ultrasound*, 21(1), 53-59. <https://doi.org/10.1007/s40477-018-0284-7>
- Hashemi, H., Khabazkhoob, M., Miraftab, M., Emamian, M. H., Shariati, M., Abdolahinia, T., & Fotouhi, A. (2012). The distribution of axial length, anterior chamber depth, lens thickness, and vitreous chamber depth in an adult population of Shahroud, Iran. *BMC Ophthalmology*, 12, 50. <https://doi.org/10.1186/1471-2415-12-50>
- Holladay, J. T. (2009). Ultrasonography and optical biometry. *Cataract & Refractive Surgery Today Europe*, 18-19.
- Kara, M. E., Sevil Kilimci, F., Yildirim, I. G., Onar, V., & Pazvant, G. (2011). The intercondylar fossa indices of male and female dog femora. *Veterinary and Comparative Orthopaedics and Traumatology* : V.C.O.T, 24(3), 211-214. <https://doi.org/10.3415/VCOT-10-04-0058>
- Kassab, A. (2012). Ultrasonographic and macroscopic anatomy of the enucleated eyes of the buffalo (*Bos bubalis*) and the one-humped camel (*Camelus dromedarius*) of different ages. *Anatomia, Histologia, Embryologia*, 41(1), 7-11.
- Kelawala, D., Patil, D., Parikh, P., Sini, K., Parulekar, E., Amin, N., Ratnu D. A. Rajput, P.K. (2015). Normal Ocular Ultrasonographic Biometry and Fundus Imaging of Indian Camel (*Camelus dromedarius*). *Journal of Camel Practice and Research*, 22(2), 181-185. <https://doi.org/10.5958/2277-8934.2015.00028.4>
- Lehmkuhl, R. C., Almeida, M. F., Mamprim, M. J., & Vulcano, L. C. (2010). B-mode ultrasonography biometry of the Amazon Parrot (*Amazona aestiva*) eye. *Veterinary Ophthalmology*, 13 Suppl, 26-28. <https://doi.org/10.1111/j.1463-5224.2010.00797.x>
- Mirshahi, A., Shafigh, S. H., & Azizzadeh, M. (2014). Ultrasonographic biometry of the normal eye of the Persian cat. *Australian Veterinary Journal*, 92(7), 246-249. <https://doi.org/10.1111/avj.12189>
- Oliver, J. (2008). Ophthalmology and Ultrasound. <https://www.vettimes.co.uk> (assessed April 28, 2008).
- Osuoben, E. P., & Hamidzada, W. A. (1999). Ultrasonographic determination of the dimensions of ocular components in enucleated eyes of the one-humped camel (*Camelus dromedarius*). *Research in veterinary science*, 67(2), 125-129. <https://doi.org/10.1053/rvsc.1998.0288>
- Potter, T. J., Hallowell, G. D., & Bowen, I. M. (2008). Ultrasonographic anatomy of the bovine eye. *Veterinary radiology & ultrasound : the official journal of the American College of Veterinary Radiology and the International Veterinary Radiology Association*, 49(2), 172-175. <https://doi.org/10.1111/j.1740-8261.2008.00345.x>
- Quan-hao, B., Jun-li, W., Qing-qiang, W., Qi-chang, Y., & Jin-song, Z. (2007). The measurement of anterior chamber depth and axial length with the IOLMaster compared with contact ultrasonic axial scan. *International Eye Science*, 7(4), 921-924.
- Ribeiro, A. P., Silva, M. L., Rosa, J. P., Souza, S. F., Teixeira, I. A., & Laus, J. L. (2009). Ultrasonographic and echobiometric findings in the eyes of Saanen goats of different ages. *Veterinary Ophthalmology*, 12(5), 313-317. <https://doi.org/10.1111/j.1463-5224.2009.00719.x>
- Solarte, C. E., & Shaikh, A. (2007). Ultrasound techniques in ophthalmology. *Ophthalmology investigation and examination techniques*. Butterworth-Heinemann, Philadelphia, 137-149. DOI: 10.1016/B978-0-7506-7586-4.50017-9.
- Sorouri, S., Masoudifard, M., Raoufi, A., & Aghazadeh, M. (2009). Ultrasonographic findings of some ocular structures in Caspian miniature horse. <https://doi.org/10.22099/IJVR.2009.1716>
- Tran, H., Jan, N. J., Hu, D., Voorhees, A., Schuman, J. S., Smith, M. A., Wollstein, G., & Sigal, I. A. (2017). Formalin Fixation and Cryosectioning Cause Only Minimal Changes in Shape or Size of Ocular Tissues. *Scientific Reports*, 7(1), 12065. <https://doi.org/10.1038/s41598-017-12006-1>
- Yadegari, M., Salehi, A., Ashtari, A., & Ashtari, M. S. (2013). B-mode ultrasound biometry of intraocular structures in dromedary camels (*Camelus dromedarius*). *Global Veterinaria*, 10(1), 71-74.