



Demirtas' early renal vascular control technique (DERVACT): A novel technique for open partial nephrectomy

Gökhan SÖNMEZ¹, Şevket T. TOMBUL¹, Turev DEMİRTAŞ², Abdullah GÖLBAŞI¹, Abdullah DEMİRTAŞ^{1*}

¹Department of Urology, Faculty of Medicine, Erciyes University, Kayseri, Turkey

²Department of Medical History and Ethics, Faculty of Medicine, Erciyes University, Kayseri, Turkey

Received: 12.05.2021

Accepted/Published Online: 31.05.2021

Final Version: 01.01.2022

Abstract

“Demirtas' Early Renal Vascular Control Technique (DERVACT)” is a novel technique for renal pedicle control that aims to achieve rapid and direct access to the renal artery through the retroperitoneal space and then the superior-dorso-lateral aspect of the kidney. In this study, we aimed to introduce DERVACT and to present the initial outcomes of this technique. This retrospective-observational study compared two groups of patients that were operatively treated by the same surgical team using two different nephron sparing surgery (NSS) procedures. Group I (n=95) underwent standard open NSS and Group II (n=92) underwent open NSS with the DERVACT between Jan 2015 and July 2020. Mean age was 56.42 ± 13.27 years. No significant difference was found between the two groups with regard to age, gender, Body mass index, mass laterality and size, and the Padua and c-index scores ($p=0.087$, $p=0.354$, $p=0.642$, $p=0.957$, $p=0.200$, $p=0.101$, $p=0.361$, respectively). Similarly, no significant difference was found between the DERVACT group and the other group with regard to ischemia duration (20.0 [15.0-30.0] min vs. 18.5 [11.0-27.0] min, respectively, $p=0.060$) and intraoperative vascular complication rate (6.3% vs. 1.1%, respectively, $p=0.059$). However, non-ischemic operative time was significantly shorter in the DERVACT group than in the standard partial nephrectomy group (64.0 [50.0-75.0] vs. 84.0 [61.0-105.0], $p<0.001$). As a conclusion, DERVACT is a simple, time-saving, and safe procedure for NSS that can be used in clinics with no opportunities for robotic-laparoscopic partial nephrectomy or in open partial nephrectomy.

Keywords: kidney surgery, retroperitoneal approach, vascular anatomy, partial nephrectomy

1. Introduction

Renal cell carcinoma (RCC) is the third most common urological cancer worldwide. Nephron-sparing surgery (NSS) or partial nephrectomy (PN) is a common technique used in the treatment of RCC (1). This technique typically consists of three stages: (i) dissection of renal hilum and vascular clamp, (ii) dissection and complete release of the kidney, and (iii) removal of the mass and renorrhaphy (2). The primary aim in this technique is to achieve renal hilar clamping and vascular control as promptly as possible (3).

In addition to classic PN techniques, numerous other techniques have also been developed to date. These novel techniques have mainly focused on ischemic/non-ischemic PN and its effect on renal functions, differences between the effects of clamping main versus segmental renal arteries, treatment outcomes based on the type and duration of ischemia, and renorrhaphy (4-7). However, to our knowledge, there have been very few studies focusing on vascular control, which is a critical step in PN and has a direct effect on the operative time (8).

Variations in renal arteries account for ~30% of their existence (9). However, renal artery is mostly localized to the posterior renal segment, which complicates renal pedicle

control and thereby leads to inadequate control of the arterial system during the standard procedure (Fig. 1A and 1B) (8).

In this study, we aimed to introduce a new technique for open PN that aimed to reduce the duration of vascular control and achieve renal hilar dissection in a safer and faster manner by utilizing the localization of the renal artery, which runs more superiorly and posteriorly compared to the renal vein. The study also aimed to present the initial treatment outcomes of this technique.

2. Materials and Methods

2.1. Study design and population

The retrospective study compared two groups of patients that were operatively treated by the same surgical team with 10-year experience in PN using two different nephrectomy procedures at Erciyes University, Department of Urology. Group I (n=95) underwent standard open PN and Group II (n=92) underwent PN with the “Demirtas' Early Renal Vascular Control Technique (DERVACT)” between Jan 2015 and July 2020. Patients with a history of renal/adrenal surgery were excluded from the study. Demographic and clinical characteristics including age, gender, body mass index (BMI), laterality and size of the mass, Padua and Cindex scores,

* Correspondence: mesane@gmail.com

duration of ischemia, and surgical duration were compared between the two groups. Mass size was calculated based on the histological examination of the specimens.

2.2. Calculation of operative time

Operative time was calculated as the time from first incision to closure of the skin. However, duration of ischemia was excluded from when calculating the operative time in order to rule out the factors associated with mass localization, mass complexity, and renographic variations.

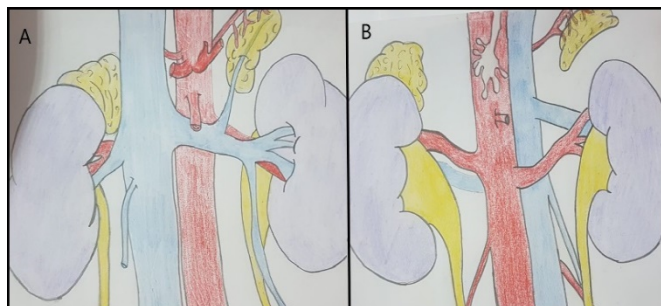


Fig. 1. Standard anatomical view of the kidneys. **A.** Anterior view. **B.** Posterior view

2.3. Anatomical touchstones: DERVACT-Point, DERVACT-Line and DERVACT-Triangle

DERVACT-Point was defined as the anterior-superior-lateral point on the kidney. In accordance with the Padua scoring system, this point was defined as the lateral point on the upper polar line (10).

DERVACT-Line was defined as the line extending from the DERVACT-Point to the posterior-inferior-medial point on the kidney (renal hilum) when the kidney is deviated anteriorly. This line technically indicates the renal artery. DERVACT-Triangle was defined as the space among (i) renal artery (which is exposed by a dissection made along the DERVACT-Line), (ii) medial segment of the upper pole kidney, and (iii) adrenal gland in the anterior-superior segment of the kidney. Renal hilum is normally located in this space and any type of hilar dissection can be performed in this area. Illustrations of the technique are shown in Fig. 2.

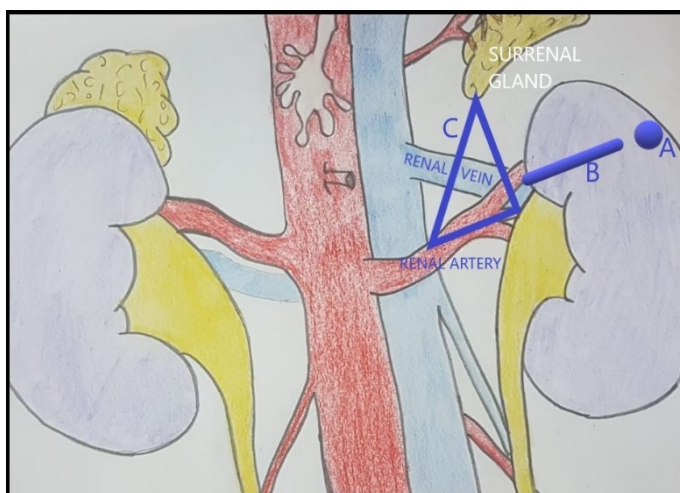


Fig. 2. Illustration for anatomical touchstones of the technique. **A.** DERVACT-Point. **B.** DERVACT-Line. **C.** DERVACT-Triangle

2.4. Novel surgical technique

The patient was placed in a full flank position with the affected kidney side facing upwards. A supra-11th flank incision was made through the skin and underlying subcutaneous tissues and the 11th rib was partially removed (Fig. 3A). The retroperitoneal space was accessed by retracting the peritoneum medially. After dissecting Gerota's fascia laterally, the upper pole of perirenal fat was dissected beginning from the anterior-superior-lateral point (DERVACT-Point) and then the upper pole was separated from the adrenal gland. The superior-lateral-posterior segment of the kidney was dissected and the dissection was continued along the DERVACT-Line towards the posterior-inferior-medial segment (renal hilum) by lifting the kidney anteriorly after it had been freed from the surrounding attachments. At the end of this line, the renal artery was easily accessed and was suspended by a vessel tape. At this stage, a triangle was formed, with the renal artery localized in its floor, the adrenal gland localized on its top, and the medial aspect of the upper pole localized at its lateral wall (DERVACT-Triangle) (Fig. 3B). After this stage, all the other attachments of the kidney were freed completely and the dissection was continued only to the renal hilum. However, renal hilum was not dissected so as not to lose time. Renal artery was subsequently occluded with Bulldog clamp after intravenous administration of 150 ml of 20% mannitol solution. Warm or cold ischemia was applied based on the clinical characteristics of the renal mass. In cases that were administered cold ischemia, the renal capsule around the mass was drawn after renal artery occlusion with Bulldog clamp and 10 min of cold ischemia, and then the mass was removed by enucleation. Surgical margin and frozen section specimens obtained from the mass base were sent for histological examination. Bleeding foci and resected portions of the collecting duct system (if any) were repaired with 3-0 absorbable sutures. Renorrhaphy was completed after the placement of Surgicel in the surgical site. PN was completed after the removal of the Bulldog clamp.

2.5. Standard nephron sparing surgery with anterior approach

The steps up to the Gerota's fascia are similar to those of DERVACT. In the standard technique, after the Gerota's fascia was parted, the psoas muscle and ureter were found. By following the ureter, kidney parenchyma and renal hilum were reached. Careful dissection was conducted to isolate the ureter, renal vein, and renal artery, each of which is surrounded by a different colored vessel loop. It should be remembered that the renal vein was usually located anteriorly in the renal hilum and this was the first vessel encountered. In order to reach the renal artery, the renal vein should be completely dissected and lateralized at the first step. Then the renal artery was dissected enough to put a bulldog clamp. The kidney was completely dissected starting from the lower pole and separated from the surrounding adipose tissue after hilum dissection. Dissections were made between the adrenal gland and the parenchyma in the upper pole. After the entire kidney was completely free, the

applied renal artery was brought into a state to be clamped. The methods applied from this stage are similar to DERVACT.

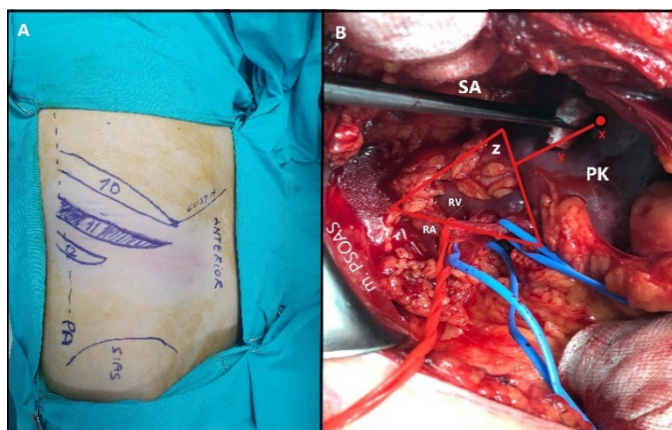


Fig. 3. Operation view for anatomical touchstones of the technique. **A.** Patient position and incision area. An incision is made on the 11th rib. PA: Posterior axillar line. **B.** Anatomical definitions of the technique. The DERVACT point is located in the posterior and upper pole of the kidney (x). The line extending from the DERVACT point to the posterior hilus-posterior renal lodge axis is the DERVACT-line (y), DERVACT-Triangle is defined as the space among renal artery-medial segment of the upper pole kidney, and adrenal area (z). Red vessel strip shows the main renal artery. Blue vessel strips show the segmental arteries. PK: posterior wall of the kidney, SA: Surrenal area, RV: Renal vein, RA: Renal artery

2.6. Statistical analysis

Data were analyzed using SPSS 22.0 for Windows (IBM Corp. Released 2013, Armonk, USA). Normal distribution of quantitative data was assessed using Shapiro-Wilk test and Histogram plots. Quantitative data with normal distribution were expressed as mean \pm standard deviation (SD) and data with non-normal distribution were expressed as median (1st-3rd quartile). Categorical data were expressed as percentages (%). Continuous variables in independent groups were compared using independent samples t-test or Mann-Whitney

Table 1. Comparison of the two techniques

Variable	Standard Enucleation Nephrectomy (n=95)	DERVACT Enucleation Nephrectomy (n=92)	p
Age (years)	54.79 \pm 12.82	58.11 \pm 13.58	0.087
Gender (Female/Male)	40/52	35/60	0.354
Body mass index (kg/m ²)	29.0(27.0-32.0)	29.0(27.0-34.0)	0.642
Laterality (Right/Left)	52/43	50/42	0.957
Mass size (cm)	5.0(4.0-7.0)	6.0(5.0-7.0)	0.200
Padua	6.5(6.0-8.0)	8.0(7.0-9.0)	0.101
C-Index	2.0(1.0-3.0)	3.0(2.0-4.0)	0.361
Duration of ischemia (min)	20.0(15.0-30.0)	18.5(11.0-27.0)	0.060
Operative time (min)	84.0(61.0-105.0)	64.0(50.0-75.0)	<0.001

DERVACT: Demirtaş' Early Renal Vascular Control Technique

3.3. Intraoperative complications

Intraoperative vascular complications occurred in six (6.3%) patients that underwent standard PN and in one (1.1%) patient in the DERVACT group ($p=0.059$). In the group that underwent standard PN, five (5.3%) patients developed minor vascular injury during renal pedicle control. In the same group, the segmental renal artery branch was injured in one (1.1%) patient and thus required ligation. In the DERVACT group,

U test based on their distribution pattern. Categorical variables were compared using chi-square test (Pearson's Chi-square test or Fisher's Exact test). A p value of less than 0.05 was considered significant.

2.7. Ethical approval

This study was approved by the Erciyes University Clinical Research Ethics Committee (Approval number: 2020/246). All participants were informed verbally and in writing before the operations and a written consent was obtained from each of them.

3. RESULTS

3.1. Patient characteristics

The 187 patients comprised 110 (58.8%) men and 77 (41.2%) women with a mean age of 56.42 ± 13.27 years and a median BMI value of 29.0 (27.0 - 33.0) kg/m². The mass was located in the right kidney in 102 (54.5%) and in the left kidney in 85 (45.5%) patients. The mass was mostly localized to the lower pole ($n=72$; 38.5%), followed by upper pole ($n=62$; 33.1%) and middle pole ($n=53$; 28.4%). Median mass size was 4.0 (3.0-5.0) cm, median Padua score was 7.0 (6.0-8.0), and median C-Index score was 2.0 (1.0-3.0). Median duration of intraoperative ischemia was 20.0 (12.0-29.5) min and median operative time was 70.0 (55.0-120.0) min. In histological examination, 157 (84.0%) cases were reported as RCC, 20 (10.7%) as oncocytoma, 9 (4.8%) as angiomyolipoma, and 1 (0.5%) as sarcoma.

3.2. Outcomes of the novel technique and comparison of groups

No significant difference was found between the two groups with regard to age, gender, BMI, mass laterality and size, and the Padua and C-Index scores ($p=0.087$, $p=0.354$, $p=0.642$, $p=0.957$, $p=0.200$, $p=0.101$, $p=0.361$, respectively). However, median operative time was significantly shorter in the DERVACT group ($p<0.001$) (Table 1).

however, only one patient developed renal venous injury. All these injuries were repaired intraoperatively and PN was completed in all patients. Apart from these complications, no major intraoperative complications occurred in both groups.

4. Discussion

The results indicated DERVACT provided several advantages: (1) safer and faster completion of kidney dissection, (2) avoidance of time loss due to the non-requirement of dissection

of fat tissues in the renal pedicle and renal vein, and (3) reduced operative time. Moreover, the DERVACT group had a similar complication rate to that of other group, which implicates that DERVACT is a safe procedure.

Renal hilar dissection followed by vascular clamping represents the most important and critical step in renal surgery (3). Although there are a limited number of studies conducted on this subject, Porpiglia et al. are known as the precursors of the strategy used for accessing and controlling the renal artery, who proposed that the arterial control can be achieved via direct access to the aorta and renal artery at the level of Treitz ligament (11-13). Based on this technique, Tunc et al. developed modified laparoscopic radical nephrectomy that involved accessing the renal artery and renal pedicle through the Morison space and performing rapid pedicle control via en-bloc ligation of the renal pedicle (14). In 2019, Yang et al. described a renal hilar dissection technique for laparoscopic partial and radical nephrectomy that offered early vascular control. In this technique, renal artery is reached via direct access to the renal hilum through the posterior aspect of the kidney immediately after entering the retroperitoneal space. The researchers named this technique “three-step method” and proposed it as a safe and practical technique (15). Zhang et al. developed a similar technique for retroperitoneal laparoscopic PN, which involved full exposure of the tumor via dissections followed by renal artery access through the ureter and the superior-lateral aspect of the kidney (5). Nouralizadeh et al. argued that by rotating the kidney 180 degrees on the horizontal axis, the renal pedicle can be controlled more easily (16). The common feature of these three techniques and our technique is that all four of them prioritize the control of the renal artery by accessing the renal hilum through the posterior aspect of the kidney. However, our technique, unlike the others, involves accessing the kidney through the superior-dorsal-lateral aspect rather than the lateral or inferior-lateral aspect of the kidney, thus prioritizing direct and prompt access to the renal artery. Accordingly, DERVACT-Line and DERVACT-Triangle, which were introduced within this technique, may allow the implementation of this technique in a more systematic way. Additionally, DERVACT was developed based on open PN by taking into account the clinics with no opportunities for laparoscopic PN or those with no such experience.

In our study, the operative time was calculated by excluding the duration of ischemia in order to reduce the effect of the complexity of the renal mass and the duration of enucleation. As a result, the mean operative time was calculated as 64 min in the DERVACT group as opposed to 84 min in the group that underwent standard PN, which indicates that DERVACT reduced the operative time by approximately 20 min. Yang et al. evaluated patients that underwent laparoscopic PN and reported the mean operative time as 88 min (15). In contrast, Zapala et al. and as 174 min by Pereira et al. reported the mean operative time in patients undergoing

open PN as 100-120 min and 174 min, respectively (17, 18). These findings indicate that the mean operative times in our study, even when the durations of ischemia were included, were shorter than those reported in the literature. This difference could be attributed to the fact that all the procedures were performed by the same surgical team that had 10 years of experience in PN.

A previous meta-analysis evaluated the outcomes of three studies and reported the rate of intraoperative complications in patients undergoing open PN as 4.9% (19). Similarly, another study reported this rate as 5.3% (20). In our study, however, intraoperative vascular complications occurred in only 3.7% (n=7) of 187 patients that underwent open PN, including six (6.3%) patients in the standard PN group and one (1.1%) patient in the DERVACT group. However, this difference was statistically insignificant ($p=0.059$). Considering that only vascular complication rates were calculated in the present study, our complication rates seem to be consistent with those reported in the literature.

Our study had several important limitations. First, the study had a retrospective design and a small patient population. Second, the time interval between skin incision and pedicle control could not be recorded due to the retrospective nature of the study. Finally, the study introduced a technique for open PN, which is used rarely when compared to the laparoscopic or robotic techniques.

In conclusion, DERVACT is a simple, time-saving, and safe procedure that can be used in clinics with no opportunities for robotic-laparoscopic partial nephrectomy or in cases requiring NSS.

Conflict of interest

All authors declare that, there is no conflicts of interest in connection with this paper

Acknowledgments

Many thanks to Dr. Meltem Guman for her drawings and her support to the study.

References

1. Campbell S, Uzzo RG, Allaf ME, Bass EB, Cadeddu JA, Chang A, Clark PE, Davis BJ, Derweesh IH, Giambarrresi L, Gervais DA, Hu SL, Lane BR, Leibovich BC, Pierorazio PM. Renal Mass and Localized Renal Cancer: AUA Guideline. *J Urol*. 2017;198(3):520-529. doi: 10.1016/j.juro.2017.04.100.
2. Kletscher BA, Lauvetz RW, Segura JW. Nephron-sparing laparoscopic surgery: techniques to control the renal pedicle and manage parenchymal bleeding. *J Endourol*. 1995;9(1):23-30. doi: 10.1089/end.1995.9.23.
3. Kenney PA, Wotkowicz C, Libertino JA. Contemporary Open Surgery of the Kidney. *Campbell-Walsh Urology*. 2012; 2: 1567-8.
4. Leslie S, Goh AC, Gill IS. Partial nephrectomy--contemporary indications, techniques and outcomes. *Nat Rev Urol*. 2013;10(5):275-83. doi: 10.1038/nrurol.2013.69.
5. Russo P. Open partial nephrectomy. Personal technique and current outcomes. *Archivos espanoles de urologia*. 2011; 64(7),

571–593.

6. Azhar RA, Metcalfe C, Gill IS. Anatomic partial nephrectomy: technique evolution. *Curr Opin Urol.* 2015 Mar;25(2):95-9. doi: 10.1097/MOU.000000000000140.
7. Minervini A, Campi R, Lane BR, De Cobelli O, Sanguedolce F, Hatzichristodoulou G, et al. Impact of Resection Technique on Perioperative Outcomes and Surgical Margins after Partial Nephrectomy for Localized Renal Masses: A Prospective Multicenter Study. *J Urol.* 2020;203(3):496-504. doi: 10.1097/JU.0000000000000591.
8. Zhang C, Wang F, Shi X, Guo F, Wang H, Yang Y, et al. Direct Lateral Access to Renal Artery During Transperitoneal Laparoscopic Partial Nephrectomy: Surgical Technique and Comparative Outcomes. *Urology.* 2018; 120:120-124. doi: 10.1016/j.urology.2018.07.014.
9. Standring S. *The Anatomical Basis of Clinical Practice.* 39th edition. New York, NY, USA: Elsevier, Churchill Livingstone, Gray's anatomy. 2005; pp. 1271–4.
10. Ficarra V, Novara G, Secco S, Macchi V, Porzionato A, De Caro R, et al. Preoperative aspects and dimensions used for an anatomical (PADUA) classification of renal tumours in patients who are candidates for nephron-sparing surgery. *Eur Urol.* 2009;56(5):786-93. doi: 10.1016/j.eururo.2009.07.040.
11. Porpiglia F, Terrone C, Cracco C, Renard J, Musso F, Grande S, et al. Direct access to the renal artery at the level of treitz ligament during left radical laparoscopic transperitoneal nephrectomy. *Eur Urol.* 2005;48(2):291-5. doi: 10.1016/j.eururo.2005.03.024.
12. Porpiglia F, Renard J, Billia M, Morra I, Scoffone C, Cracco C, et al. Left laparoscopic radical nephrectomy with direct access to the renal artery: technical advantages. *Eur Urol.* 2006;49(6):1004-10. doi: 10.1016/j.eururo.2006.02.038.
13. Porpiglia F, Terrone C, Cracco C, Cossu M, Grande S, Musso F, et al. Early ligation of renal artery during radical laparoscopic transperitoneal nephrectomy: description of standard technique and direct access. *J Endourol.* 2005;19(6):623-6; discussion 626-7. doi: 10.1089/end.2005.19.623.
14. Tunc L, Canda AE, Polat F, Onaran M, Atkin S, Biri H, et al. Direct upper kidney pole access and early ligation of renal pedicle significantly facilitates transperitoneal laparoscopic nephrectomy procedures: Tunc technique. *Surg Laparosc Endosc Percutan Tech.* 2011;21(6):453-7. doi: 10.1097/SLE.0b013e31823badc1.
15. Yang F, Zhou Q, Li X, Xing N. The methods and techniques of identifying renal pedicle vessels during retroperitoneal laparoscopic radical and partial nephrectomy. *World J Surg Oncol.* 2019;17(1):38. doi: 10.1186/s12957-019-1580-1.
16. Nouralizadeh A, Ziaee SA, Basiri A, Simforoosh N, Abdi H, Mahmoudnejad N, Kashi AH. Transperitoneal laparoscopic partial nephrectomy using a new technique. *Urol J.* 2009;6(3):176-81.
17. Zapala P, Dybowski B, Miazek N, Radziszewski P. Open partial nephrectomy for entirely intraparenchymal tumors: a matched case-control study of oncologic outcome and complication rate. *Int Braz J Urol.* 2017;43(2):209-215. doi: 10.1590/S1677-5538.IBJU.2016.0040.
18. Pereira J, Renzulli J 2nd, Pareek G, Moreira D, Guo R, Zhang Z, et al. Perioperative Morbidity of Open Versus Minimally Invasive Partial Nephrectomy: A Contemporary Analysis of the National Surgical Quality Improvement Program. *J Endourol.* 2018;32(2):116-123. doi: 10.1089/end.2017.0609.
19. Wu Z, Li M, Liu B, Cai C, Ye H, Lv C, et al. Robotic versus open partial nephrectomy: a systematic review and meta-analysis. *PLoS One.* 2014;9(4):e94878. doi: 10.1371/journal.pone.0094878.
20. Ghani KR, Sukumar S, Sammon JD, Rogers CG, Trinh QD, Menon M. Practice patterns and outcomes of open and minimally invasive partial nephrectomy since the introduction of robotic partial nephrectomy: results from the nationwide inpatient sample. *J Urol.* 2014;191(4):907-12. doi: 10.1016/j.juro.2013.10.099.