

Karın Ağrısı COVID-19'un Tek Şikayeti Olabilir; Olgu Sunumu ve Güncel Literatürün Gözden Geçirilmesi

Abdominal Pain May Be the Only Complaint of COVID-19; Case Report and Review of the Current Literature

👤 Aysın Kılınç Toker¹, 👤 İlhami Çelik², 👤 Abdullah Gür³, 👤 İbrahim Toker⁴

¹Attending Physician of Infectious Disease and Clinical of Microbiology. Kayseri City Hospital, Department of Infectious Disease and Clinical of Microbiology / Kayseri, Turkey.

²Professor of Infectious Disease and Clinical of Microbiology. Kayseri City Hospital, Department of Infectious Disease and Clinical of Microbiology / Kayseri, Turkey.

³Attending Physician of Anesthesiology and Reanimation. Kayseri City Hospital, Department of Anesthesiology and Reanimation / Kayseri, Turkey.

⁴Attending Physician of Emergency Medicine. Kayseri City Hospital, Department of Emergency Medicine / Kayseri, Turkey.

ÖZ

Amaç: Yeni koronavirüs dünya çapında hızla yayılmış ve uluslararası bir pandemiye neden olmuştur. Ateş, öksürük ve nefes darlığı COVID-19'un (koronavirüs hastalığı 2019) karakteristik belirtileri olarak kabul edilmektedir. Gastrointestinal semptomlar daha az görülmesine rağmen, büyük ölçüde göz ardı edilen semptomlar arasındadır. Bu olgu sunumunda acil servise sadece karın ağrısı ile başvuran bir erkek hastayı sunmayı amaçladık.

Olgu sunumu: 70 yaşında erkek hasta, dört gündür olan karın ağrısı şikayeti ile acil servise başvurdu. Hastanın karın ağrısı göbek çevresinde ve kolik vasıflı idi. Batın muayenesinde göbek çevresinde yaygın hassasiyet olan hastanın defans veya ribaundu yoktu. Hastanın abdominal BT'si (bilgisayarlı tomografi) normal olarak değerlendirildi. Ancak abdominal BT'de, akciğer bazalinde COVID-19 için tipik BT bulguları mevcuttu. Yatış sırasındaki ilk RT-PCR (gerçek zamanlı ters transkripsiyon polimeraz zincir reaksiyonu) testi negatif olan hastanın 48 saat sonraki testi pozitifti.

Sonuç: Çalışmamız, hekimlerinin COVID-19'un atipik prezentasyonları konusunda tetikte olması gerektiğini vurgulamaktadır.

ABSTRACT

Aim: The new coronavirus spread rapidly around the world, causing an international emergency pandemic. Fever, dry cough, and shortness of breath are considered the characteristic signs of COVID-19 (coronavirus disease 2019). Although gastrointestinal symptoms are less common, they are among the symptoms of COVID-19 that are largely ignored. In this case report, we aimed to present a male patient who applied to the emergency department with only abdominal pain.

Case report: A 70-year-old male patient was admitted to the emergency department with a complaint of abdominal pain four days prior. The patient had abdominal pain that had been around the umbilicus and colic for the previous four days. Abdominal examination showed widespread tenderness around the umbilicus but no defences or rebounds. The abdominal CT (computed tomography) results were considered normal. But on the abdominal CT, there were typical CT findings on the lung base for COVID-19. The RT-PCR (real-time reverse transcription-polymerase chain reaction) tests at admission and 48 hours later were negative and positive, respectively.

Conclusion: Our study emphasizes that physicians should be alert to atypical presentations of COVID-19.

Sorumlu Yazar/Corresponding Author: İbrahim Toker
Kayseri City Hospital, Department of Emergency Medicine / Kayseri,
Turkey.

e.mail: ibrahimtoker9@gmail.com

Tel: +90 352 315 77 00

Geliş tarihi/Received: 13.05.2021
Kabul tarihi/Accepted: 23.07.2021

Introduction

COVID-19 disease started in December 2019 in Wuhan, China, and spread to more than 200 countries, with approximately 180 million confirmed cases and over 3.9 million deaths worldwide of June 2021(1,2). Although COVID-19 does not yet have symptoms that distinguish it from other viral respiratory infections, the most prevalent symptoms in the general population are fever (98%), cough (76%), shortness of breath (55%), muscle aches (35%), and fatigue (40%)(3).

COVID-19 pneumonia, characterized by fever, cough, shortness of breath, and bilateral infiltrates in lung imaging. However, other symptoms, such as upper respiratory symptoms, myalgia, diarrhea, and smell or taste disturbances, are also common. Although dyspnea occurs a few days after the onset of initial symptoms suggests COVID-19, no specific clinical feature can reliably differentiate COVID-19 from other viral respiratory infections(3).

Recent studies describe the clinical features of COVID-19 in hospitalized populations. In the study that involved 138 patients hospitalized with COVID-19 pneumonia in Wuhan, the most common clinical features at the onset of the disease were fever (99%), fatigue (70%), dry cough (59%), anorexia (40%), myalgia (35%), dyspnea (31%), and expectoration (27%)(4). Accompanying respiratory symptoms, up to 20 % of patients reported digestive symptoms such as abdominal pain, nausea, vomiting, and diarrhea(4,5).

Doctor Sylvain-Nguyen, a geriatrician at the Lausanne University Hospital, explained the atypical symptoms of elderly COVID-19 patients as follows: changes in the patient's normal state, delirium, falling, fatigue, drowsiness, hypotension, dysphagia, syncope, diarrhea, nausea, vomiting, abdominal pain, and loss of smell and taste(6). It is essential to include uncommon symptoms in the literature due to the risk of overlooking patients who present with atypical symptoms(7). Since the disease's pathophysiology is not fully understood, atypical symptoms other than respiratory tract symptoms can cause a delay in the diagnosis of the patients(8).

In parallel with the increase in the number of patients, the number of patients presenting with atypical clinical signs and symptoms has also increased. We present a male patient admitted to the emergency department with a complaint of abdominal pain then diagnosed with COVID-19.

Case report

A 70-year-old male was admitted to the hospital with abdominal pain that had been around the umbilicus and colic for the previous four days. Abdominal pain was reflected in

his back and chest. The patient had stable vital signs in the emergency department. There were no other complaints, such as fever and cough; however, the patient stated that he had occasional shortness of breath. On physical examination, the skin was warm, and there were rales in the lung auscultation. Abdominal examination showed widespread tenderness around the umbilicus but no defenses or rebounds. Other physical examinations were normal on admission. The patient's body temperature was measured at 38.5 °C. The patient's test results were as follows: the white blood cell count was 5300/mm³, neutrophil count 3700/mm³, lymphocyte count 1370/mm³, hemoglobin 15.3 g/dL, C-reactive protein 106 mg/dL, lactate dehydrogenase 328 U/dL, ferritin 1028 mg/dL, D-dimer 1040 µg/dL, and fibrinogen 7190 mg/dL. The abdominal CT results were considered normal. But we found bilateral and peripheral ground-glass opacities lung base in the abdominal CT scans. In thorax CT, infiltrations were observed in the diffuse ground-glass density in both lungs' peripheral areas, but they were more prominent on the left lung (Figure 1). The stool analyses (microscopic examination, culture) of the patient were normal, who described the diarrhoea attacks that occasionally occurred. During hospitalization, levofloxacin (IV 2X500mg) and enoxaparin (subcutaneous, 40 mg) were started. Despite an increased oxygen supply during the follow-up, the patient, whose saturation was 90%, was taken to the intensive care unit (ICU). The RT-PCR tests of the nasopharyngeal swab samples taken for SARS-CoV-2 testing at admission and 48 hours later were negative and positive, respectively. Favipiravir treatment was started for the patient. After five days of favipiravir treatment, the patient's general condition improved, oxygen saturation with nasal oxygen reached 98%, and body temperature was 36.7 °C.

Discussion

Atypical COVID-19 clinical presentations result in delays in diagnosing and treating the disease. No significant symptoms, such as cough or shortness of breath, were observed in the patient's first presentation described in this case report.

Fever, dry cough, and shortness of breath are considered the characteristics symptoms of COVID-19 caused by the new coronavirus. Recent studies mentioned another common but overlooked symptom: stomach upset. In a multicenter study with 204 confirmed COVID-19 patients in China, it was found that almost half of the patients admitted to the hospital with digestive symptoms, such as anorexia, diarrhea, vomiting, and abdominal pain. It was reported that seven (3%) of these patients presented only

with digestive symptoms, i.e., without respiratory symptoms(9).

Studies have reported that the rate of detection of gastrointestinal tract symptoms in patients with COVID-19 is gradually increasing(10). In a comprehensive study in China, 5% of 1099 patients with COVID-19 had nausea, and vomiting was reported in 3.8%. In that study, it was found that viral pneumonia never developed in 8.9% of patients(10,11). In the same study, 157 of 877 COVID-19 patients had no radiographic or computed tomography (CT) abnormalities(11). In a study of 23 patients with non-specific gastrointestinal symptoms, 17 of these patients found to have typical lung base findings above the abdominal CT scans without suspected COVID-19 were later shown to be COVID-19-positive(12). Montazeri et al. (13) suggested that more care should be taken in patients with only gastrointestinal symptoms for early patient detection and isolation.

One study that examined systematic reviews and meta-analyses, eleven retrospective cohort studies, and six case studies reported that cough, a key diagnostic symptom, was observed in two-thirds of cases and was unreliable. On the other hand, fever was identified as the most common symptom for mild and moderate COVID-19 cases, generally defined as patients without pneumonia, ARDS, or ICU acceptance, but anosmia may be a stronger predictor. Also, in this study, it was reported that there was insufficient evidence about which symptoms quickly distinguished mild and moderate cases from severe cases(14).

Ai et al. (15) reported that 30% of all patients had negative RT-PCR results, while these patients had typical chest CT findings for COVID-19. Also, about half of these patients were considered a high probability for COVID-19. In our case, although the first RT-PCR result was negative for COVID-19, typical thorax CT findings for COVID-19 were present.

Conclusion

Atypical presentations of COVID-19 have been described, but their frequency is unknown. Our study emphasizes that healthcare professionals must be vigilant about the atypical presentations of COVID-19.

Informed Consent: Written informed consent was obtained from patient who participated in this study.

Conflict of Interest: No conflict of interest was declared by the authors.

Financial Disclosure: The authors declared that this study has received no financial support.

Presentation(s) or Awards at a meeting: None Declared
Author contributions: AKT and AG managed the patient. AKT, İT and AG followed the patient. AKT reviewed the literatures. AKT, İT and İÇ wrote the draft. All authors revised and approved the final version of the manuscript.

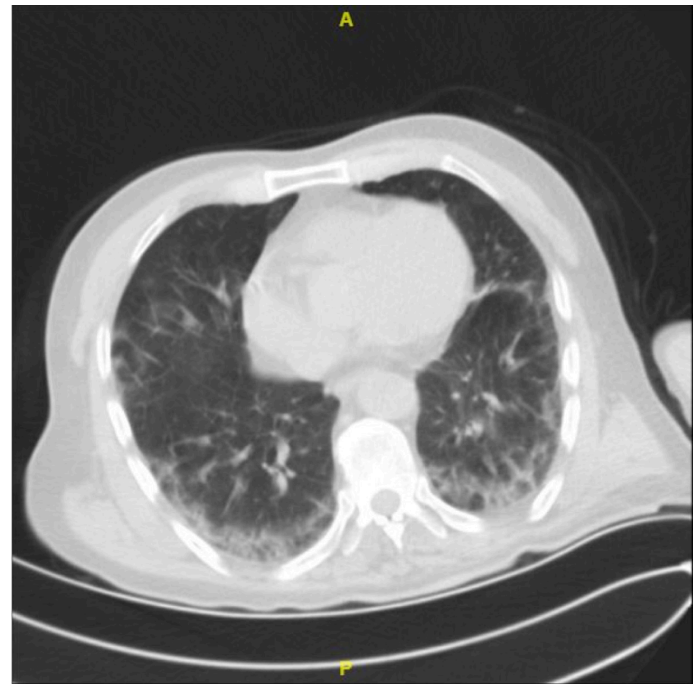


Figure 1: CT thorax scan of the patient while emergency admission

References

1. Zhou F, Yu T, Du R, et al. Clinical course and risk factors for mortality of adult inpatients with COVID-19 in Wuhan, China: a retrospective cohort study. *Lancet Lond Engl.* 2020 28;395(10229):1054–62.
2. World Health Organization. COVID-19 Weekly Epidemiological Update-29 June 2021.
3. Coronavirus disease 2019 (COVID-19): Epidemiology, virology, clinical features, diagnosis, and prevention - UpToDate. Available from: <https://www.uptodate.com>
4. Wang D, Hu B, Hu C, et al. Clinical Characteristics of 138 Hospitalized Patients With 2019 Novel Coronavirus-Infected Pneumonia in Wuhan, China. *JAMA.* 2020 Mar 17;323(11):1061-1069.
5. Chen N, Zhou M, Dong X, et al. Epidemiological and clinical characteristics of 99 cases of 2019 novel coronavirus pneumonia in Wuhan, China: a descriptive study. *Lancet Lond Engl.* 2020 15;395(10223):507–13.
6. Nguyen S, Major K, Cochet C, et al. COVID-19 infection in the elderly in Frenchspeaking Switzerland: an inventory

of beliefs, convictions and certainties [Internet]. *Rev Med Suisse* 2020;16: 835-8

7. Kim J, Thomsen T, Sell N, Goldsmith AJ. Abdominal and testicular pain: An atypical presentation of COVID-19. *Am J Emerg Med.* 2020;38(7):1542.e1-1542.e3.

8. Gao QY, Chen YX, Fang JY. 2019 Novel coronavirus infection and gastrointestinal tract. *J Dig Dis.* 2020 Mar;21(3):125–6.

9. Pan L, Mu M, Yang P, et al. Clinical Characteristics of COVID-19 Patients With Digestive Symptoms in Hubei, China: A Descriptive, Cross-Sectional, Multicenter Study. *Am J Gastroenterol.* 2020 May;115(5):766-773.

10. Sellevoll HB, Saeed U, Young VS, et al. Acute abdomen as an early symptom of COVID-19. *Tidsskr Nor Laegeforen.* 2020 Mar 31;140(7). English, Norwegian.

11. Guan W, Ni Z, Hu Y, et al. Clinical Characteristics of Coronavirus Disease 2019 in China. *N Engl J Med* 2020; 382:1708-1720

12. Dane B, Brusca-Augello G, Kim D, Katz DS. Unexpected Findings of Coronavirus Disease (COVID-19) at the Lung Bases on Abdominopelvic CT. *AJR Am J Roentgenol.* 2020 April 22;1–4.

13. Montazeri M, Maghbouli N, Jamali R, Sharifi A, Pazzoki M, Salimzadeh A, et al. Clinical Characteristics of COVID-19 Patients with Gastrointestinal Symptoms. *Arch Iran Med.* 2021 Feb 1;24(2):131–8.

14. Michelen M, Jones N, Stavropoulou C. In patients of COVID-19, what are the symptoms and clinical features of mild and moderate cases?. *The Centre for Evidence-Based Medicine CEBM* 2020.

15. Ai T, Yang Z, Hou H, et al. Correlation of Chest CT and RT-PCR Testing in Coronavirus Disease 2019 (COVID-19) in China: A Report of 1014 Cases. *Radiology.* 2020 February 26;200642.