

Case Report

## Mesenter artery thrombosis despite effective oral anticoagulation treatment

Muammer KARAKAYALI<sup>1,\*</sup>, Mahmut YESİN<sup>2</sup>

<sup>1</sup>Department of Cardiology, Kars Harakani State Hospital, Kars, Turkey

<sup>2</sup>Department of Cardiology, Acibadem Healthcare Group, Istanbul, Turkey

Received: 05.06.2021

Accepted/Published Online: 21.06.2021

Final Version: 01.01.2022

### Abstract

An 87-year-old woman was admitted to our emergency department with palpitation and fatigue 5 days ago. The patient with electrocardiography (ECG) Atrial Fibrillation (AF) has been treated with low molecular weight heparin and 5 mg / day warfarin for 5 days. After the fifth day of treatment the patient was admitted to the emergency department again with diffuse abdominal pain. On her physical examination there was generalized tenderness in the abdomen with no rebound. Blood biochemistry revealed elevated white blood cells and INR parameter was normal as 2.96. ECG showed atrial fibrillation. Abdominal computed tomographic angiography revealed a thrombotic appearance in SMA. Surgical intervention was offered to the patient, but she had refused to get a surgery. Afterwards, endovascular intervention to the SMA was planned. She had had an acute cardiac arrest and the patient had died. Our patient treated with heparin and warfarin for five days after the diagnosis of AF and developed acute SMA thromboembolism leading to acute mesenteric ischemia, although the INR value was in the therapeutic range. It is rare for acute mesenteric ischemia to occur beneath optimal anticoagulation therapy. In conclusion, acute mesenteric ischemia should be kept in mind in patients with normal INR values in case of severe abdominal pain.

**Keywords:** acute mesenteric ischemia, atrial fibrillation, thromboembolism, warfarin

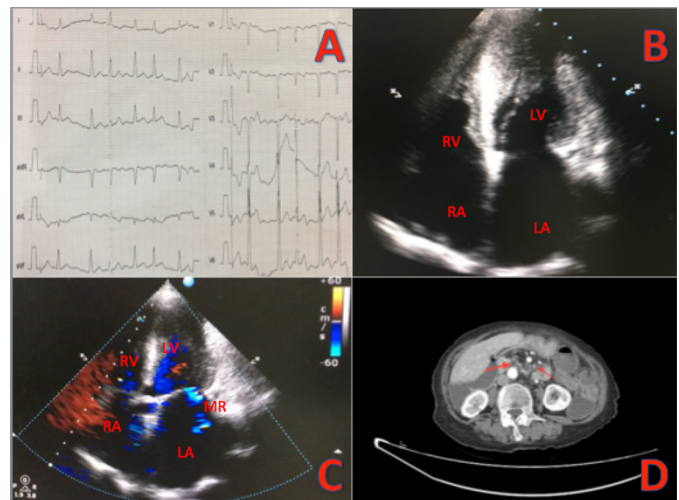
### 1. Introduction

Acute mesenteric ischemia has a high mortality rate due to delayed and prolonged diagnostic procedures (1). In this case, we presented an acute mesenteric ischemia due to superior mesenteric artery (SMA) thromboembolism despite optimal anticoagulation treatment in a patient with atrial fibrillation (AF).

### 2. Case Report

An 87-year-old woman was admitted to our emergency department with palpitation and fatigue five days ago. The patient with electrocardiography (ECG) Atrial Fibrillation (AF) has been treated with low molecular weight heparin and 5 mg / day warfarin for 5 days. After the fifth day of treatment the patient was admitted to the emergency department again with diffuse abdominal pain. On her physical examination there was generalized tenderness in the abdomen with no rebound. Her blood pressure was measured as 100-60 mmHg and she had tachycardia with 120 bpm. Blood biochemistry revealed elevated white blood cells and INR parameter was normal as 2.96. ECG showed atrial fibrillation (Fig. 1A). On echocardiographic evaluation she had normal left ventricular systolic function, mild mitral regurgitation, moderate tricuspid regurgitation, elevated estimated systolic pulmonary artery pressure as 45 mmHg, left ventricular concentric hypertrophy (Fig. 1B-C). Abdominal computed tomographic angiography revealed a thrombotic appearance in SMA as shown in Fig.

1D. Surgical intervention was offered to the patient, but she had refused to get a surgery. Afterwards, endovascular intervention to the SMA was planned. While the patient had been transferred to the catheterization laboratory, she had had an acute cardiac arrest. Despite the cardiopulmonary resuscitation, the patient had died.



**Fig. 1.** A, ECG shows atrial fibrillation, B, apical four chamber view of echocardiography, C, Echocardiography shows mild mitral regurgitation, D, abdominal CTA shows SMA thrombus (shown with red arrow) (LA: left atrium, LV: left ventricle, RA: right atrium, RV: right ventricle, MR: mitral regurgitation)

\*Correspondence: muammer-28@hotmail.com

### 3. Discussion

Acute mesenteric ischemia is a potentially fatal disease. It requires emergency surgery especially for patients with signs of intestinal necrosis such as bloody diarrhea, abdominal rebound and tenderness. However, some studies have shown that percutaneous revascularization has a good clinical outcome (2-3). Our patient treated with heparin and warfarin for 5 days after the diagnosis of AF and developed acute SMA thromboembolism leading to acute mesenteric ischemia, although the INR value was in the therapeutic range. It is rare for acute mesenteric ischemia to occur beneath optimal anticoagulation therapy. It is well known that the development of acute mesenteric ischemia in patients with AF is often seen in patients not receiving anticoagulant therapy. As in our case, we think that it is a noteworthy issue to develop thromboembolism despite optimal anticoagulation. In conclusion, acute mesenteric ischemia should be kept in mind in patients with normal INR values in case of severe abdominal pain.

### Conflict of interest

The author(s) declared no potential conflicts of interest with respect to the research, authorship, and/or publication of this article.

### Acknowledgments

None to declare.

### Funding

The authors received no financial support for the research, authorship, and/or publication of this article.

### References

1. Renner P, Kienle K, Dahlke MH, Heiss P, Pfister K, Stroszczyński C, et al. Intestinal ischemia: current treatment concepts. *Langenbecks Arch Surg.* 2011;396(1):3-11. doi: 10.1007/s00423-010-0726-y. Epub 2010 Nov 12. PMID: 21072535.
2. Popovič P, Kuhelj D, Bunc M. Superior mesenteric artery embolism treated with percutaneous mechanical thrombectomy. *Cardiovasc Intervent Radiol.* 2011; 34 Suppl 2: S67-9. doi: 10.1007/s00270-010-9921-z. Epub 2010 Jun 23. PMID: 20574794.
3. Cortese B, Limbruno U. Acute mesenteric ischemia: primary percutaneous therapy. *Catheter Cardiovasc Interv.* 2010;75(2):283-5. doi: 10.1002/ccd.22261. PMID: 19795499.