

The Prevalence of Taurodontism in a North Anatolian Dental Patient Subpopulation

Fatih Çakici¹, Yasin Atakan Benkli², Elif Bahar Çakici¹

Received: 17 February 2015 accepted: 10 April 2015/ published online: 17 April 2015
© Ordu University Institute of Health Science, Turkey, 2015

Abstract

Objective: The aim of this study was to determine the prevalence of taurodontism in a north Anatolian dental patient subpopulation, considering factors such as dental localization.

Methods: We designed a descriptive study evaluated of panoramic radiography of 1044 patients who presented to our Endodontic Services of Dentistry Faculty, Ordu University, in the city of Ordu in the north of Turkey. All the data (age and sex) were obtained from Turcasoft software (Samsun, Turkey). Patients who were less than 15 years at the time of the radiographic examination, records with poor quality radiographs and records with radiographs of only primary teeth were excluded.

To minimize the variability in the present study, the examinations were carried out jointly by the first two authors of the article over approximately one month. The taurodontism classification of Shifman was used. At the end of the study, the data were assessed statistically using SPSS 16.0 software (SPSS Inc., Chicago, IL).

Results: In this study, 3813 molar teeth of 936 patients were assessed. Taurodontism was present in 622 (16%) of these teeth. In 410 (66%) cases, the taurodontism affected the maxilla, and it affected the mandibles in 212 (34%) cases. Taurodontism occurred in 75 (12%) first molar teeth, 266 (43%) second molar teeth and 281 (45%) third molar teeth.

Conclusion: Taurodontism was a frequent anomaly in a north Anatolian dental patient subpopulation. The frequency of this anomaly may vary in different ethnic groups.

Key words: Taurodontism, epidemiology, enlarged pulp chamber

¹Department of Endodontics, Faculty of Dentistry, Ordu University, Ordu, Turkey

²Department of Orthodontics, Faculty of Dentistry, Ordu University, Ordu, Turkey

Address for correspondence/reprints:

Asst. Prof. Dr. Yasin Atakan Benkli
Department of Orthodontics, Faculty of Dentistry,
Ordu University, Ordu, Turkey
Business telephone number: 00904522121286
Fax number: +90.4522121289
E-mail address: yasinbenkli@gmail.com

Introduction

Taurodontism can be defined as one of the most important abnormalities in tooth morphology. It is characterized by vertically elongated, extremely large pulp chambers, apical displacement of the pulpal floor and bifurcation/trifurcation of the roots (Durr et al., 1980; MacDonald-Janowski and Li, 1993). A taurodont tooth looks like a normal tooth clinically. However, despite a normal crown size, extension of the rectangular pulp chamber into the elongated body of the tooth, shortened roots and root canals and displacement of furcation are observed radiographically (Terezhalmay, 2001).

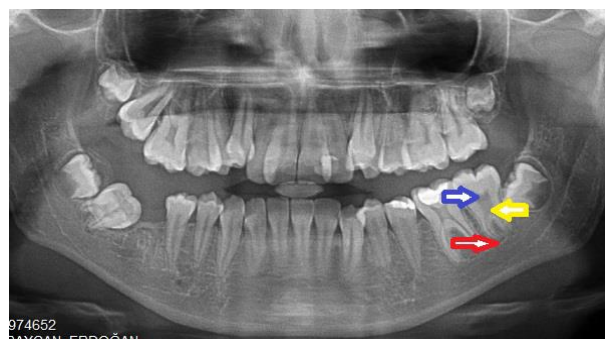
The aim of this study was to determine the prevalence of taurodontism in a north Anatolian dental patient subpopulation, considering factors such as dental localization.

Materials and Methods

In this retrospective study, we evaluated panoramic radiographs of 1044 patients who presented to our Endodontic Services of Dentistry Faculty, Ordu University, in the city of Ordu in the north of Turkey between May 2013 and September 2013. All the data (age and sex) were obtained from Turcasoft software (Samsun Turkey). Patients who were less than 15 years at the time of the radiographic examination, records with poor quality radiographs and records with radiographs of only primary teeth were excluded. The final number of patients included in the study was 936 (545 females and 391 males aged 15 to 65 years, with a mean age of 36 years).

Diagnostic Criteria

To minimize the variability in the present study, the examinations were carried out jointly by the first two authors of the article (an assistant professor from the Department of Endodontics and an assistant professor from the Department of Orthodontics) over approximately one month. Throughout the study, in case of disagreement between the first two authors as to the outcome of an examination, the assessment of a third author (an assistant professor in the Department of Endodontics) was accepted. Cases where the three authors could reach no consensus were excluded from the study. The taurodontism classification of Shifman et al. (Shifman and Chanannel, 1978) was used. According to this classification, point A is the lowest point at the occlusal end of the pulp chamber, and point B is the highest point at the apical end of the pulp chamber. X = the distance from A to B/distance from A to the apex of the longest root. A value of 'X' between 20 and 29.9% signifies hypo-taurodontism, a value between 30 and 39.9% signifies meso-taurodontism and a value between 40 and 75% signifies hyper-taurodontism (Figure 1). At the end of the study, the data were assessed statistically using SPSS



16.0 software (SPSS Inc., Chicago, IL).

Figure 1. A taurodont tooth. Blue arrow is point A (the lowest point at the occlusal end of the pulp chamber), yellow arrow is point B (the highest point at the apical end of the pulp chamber), red arrow is the apex of the longest root.

In this study, 3813 molar teeth of 936 patients (58% were female and 42% were male) were assessed. Taurodontism was present in 622 (16%) of these teeth. In 410 (66%) cases, the taurodontism affected the maxilla, and it affected the mandibles in 212 (34%) cases (Table 1).

Taurodontism occurred in 75 (12%) first molar teeth (56 cases of hypo-taurodontism, 17 cases of meso-taurodontism and two cases of hyper-taurodontism), 266 (43%) second molar teeth (193 cases of hypo-taurodontism, 46 cases of meso-taurodontism and 27 cases of hyper-taurodontism) and 281 (45%) third molar teeth (152 cases of hypo-taurodontism, 77 cases of meso-taurodontism and 52 cases of hyper-taurodontism) (Table 2).

Table 1. Prevalence of taurodontism according to localization

	First molar teeth	Second molar teeth	Third molar teeth
Upper jaw	55	185	170
Lower jaw	20	81	111

Table 2. Prevalence of taurodontism according to type of teeth .

	Hypotaur odontism	Mesotaur odontism	Hypertauro dontism
First molar teeth	56	17	2
Second molar teeth	193	46	27
Third molar teeth	152	77	52

Discussion

The material used in this study consisted of the orthopantomographs of patients who were between 15 and 65 years and visited the clinic of the Endodontic Department at the Faculty of Dentistry, Ordu University, Ordu, Turkey. The orthopantomographs of all patients who visited the faculty for the first time were. The dental faculty provides dental services to a patient population from numerous parts of the city and its surroundings. However, the sample does not represent a random sample of the Turkish population. Therefore, it is not possible to extrapolate the results to the general population.

In a study of a Chinese adult population conducted, MacDonald-Jankowski et al. (1993) found that the prevalence of taurodontism in 1093 teeth of 196 patients was 21.7% in patient. Another study reported that the prevalence was 48% in 150 patients and 18.8% in 1027 teeth in a Senegalese black adult population (Sarr et al., 2000). In a study of an adult population in Northern Sweden, the prevalence of taurodontism was 0.3% in 739 patients (Backman and Wahlin, 2001). In a study conducted in Turkey, Çelikoğlu et al. (Çelikoğlu et al., 2010) found that the prevalence of taurodontism was 4.5% in 1324 patients. In our study of 936 patients and 3813 teeth, taurodontism was found in 16% (622 teeth) of the teeth.

The application of root canal treatment to a tooth with taurodontism is a very difficult operation for practitioners because of the vertically elongated and wide pulp chambers, apical displacement of the pulpal floor and root canal entrances, differences in the root canal configuration and the possibility of extra canals. There are two different ideas about the access cavity in root canal treatment in cases of taurodontism (Tsesis, 2003). According to Shifman et al. (Shifman and Buchner, 1976) the canal entrances can be found easily because the pulpal floor is not influenced from reactional dentine. Conversely, Durr et al. (1980) suggested that the displacement of root canal entrances presents a difficulty during instrumentation and filling the root canals. In addition, they reported that it is difficult to remove all the necrotic pulp residue from the pulp chamber due to its high volume. In addition, the high volume of the pulp chamber makes it difficult to remove necrotic pulp residue.

Therefore, more time and effort are needed for irrigation. Another study reported that the ultrasonic irrigation method with NaOCl (2.5%) was more effective in removing necrotic pulp residue (Prakash, 2005). Modified filling methods have been recommended for filling root canals when the pulp chamber of taurodont teeth has a complex anatomy (Jafarzadeh et al., 2008). One study recommended that the lateral compaction method should be used to fill root canals, and the vertical compaction method should be employed to fill the pulp chamber (Jafarzadeh et al., 2008). With a view to prosthetic treatment, post-placement is not recommended for the reconstruction of a taurodont tooth (Tsesis, 2003). A taurodont tooth offers a favourable prognosis from a periodontal point of view because there is no furcation involvement until after significant destruction of periodontal tissue (Shifman and Buchner, 1976).

Conclusion

Taurodontism was a frequent anomaly in a north Anatolian dental patient subpopulation. The frequency of this anomaly may vary in different ethnic groups. To determine the prevalence of taurodontism in the Turkish population, additional studies are needed with greater numbers of patients.

Informed Consent: Written informed consent was obtained from patients who participated in this study.

Peer-review: Externally peer-reviewed.

Author Contributions: Concept FC, EBC; Design FC; Supervision FC, YAB; Materials – FC, YAB; Data Collection and/or Processing – FC, YAB; Analysis and/or Interpretation – FC, EBC; Literature Review – FC, EBC; Writing - FC; Critical Review – FC, YAB, EBC.

Conflict of Interest: No conflict of interest was declared by the authors.

Financial Disclosure: The authors declared that this study hasn't received any financial support.

References

- Backman B, Wahlin YB. Variations in number and morphology of permanent teeth in 7-year-old Swedish children. *Int J Paediatr Dent.* 2001; 11(1): 11-7.
- Çelikoğlu M, Miloğlu Ö, Öztekin Ö, Kamak H, Kazancı F, Oktay H. The Frequency of Taurodontism in an East Anatolian Orthodontic Patient Population. *Türkiye Klinikleri J Dental Sci* 2010; 16(3): 214-7.
- Durr DP, Campos CA, Ayers CS. Clinical significance of taurodontism. *J Am Dent Assoc.* 1980;100(3):378-81.
- Jafarzadeh H, Azarpazhooh A, Mayhall JT. Taurodontism: a review of the condition and endodontic treatment challenges. *Int Endod J.* 2008; 41(5): 375-88.
- MacDonald-Jankowski DS, Li TT. Taurodontism in a young adult Chinese population. *Dentomaxillofac Radiol.* 1993; 22(3): 140-4.
- Prakash R, Vishnu C, Suma B, Velmurugan N, Kandaswamy D. Endodontic management of taurodontic teeth. *Indian J Dent Res.* 2005; 16(4): 177-81.
- Sarr M, Toure B, Kane AW, Fall F, Wone MM. [Taurodontism and the pyramidal tooth at the level of the molar. Prevalence in the Senegalese population 15 to 19 years of age]. *Odontostomatol Trop.* 2000; 23(89): 31-4.
- Shifman A, Buchner A. Taurodontism. Report of sixteen cases in Israel. *Oral Surg Oral Med Oral Pathol.* 1976; 41(3): 400-5.
- Shifman A, Chananel I. Prevalence of taurodontism found in radiographic dental examination of 1,200 young adult Israeli patients. *Community Dent Oral Epidemiol.* 1978; 6(4): 200-3.
- Terezhalmay GT, Riley CK, Moore WS. Clinical images in oral medicine and maxillofacial radiology. Taurodontism. *Quintessence Int.* 2001; 32(3): 254-5.
- Tsesis I, Shifman A, Kaufman AY. Taurodontism: an endodontic challenge. Report of a case. *J Endod.* 2003; 29(5): 353-5.