











To cite this article: Kose A, Altunisik Toplu S, Gonultas F, Koc C, Yakupogullari Y, Otlu B, Turkmen Samdanci E, Yasar S, Yilmaz S, Bayindir Y. Clinical presentation, diagnosis and management of herpes simplex virus viremia in liver transplant recipients. Turk J Clin Lab 2021; 3: 265-272.

■ Original Article

Clinical presentation, diagnosis and management of herpes simplex virus viremia in liver transplant recipients

Karaciğer nakli alıcılarında herpes simpleks virüs viremisinin tanısı, klinik görünüşleri ve tedavi yönetimi

Adem KOSE^{1*} , Sibel ALTUNISIK TOPLU¹ , Fatih GONULTAS² , Cemalettin KOC² , Yusuf YAKUPOGULLARI³ , Baris OTLU³ , Emine TURKMEN SAMDANCI⁴ , Seyma YASAR⁵ , Sezai YILMAZ⁶ , Yasar BAYINDIR¹ 

¹Inonu University, Faculty of Medicine, Department of Infectious Diseases and Clinical Microbiology, Malatya/TURKEY

²Inonu University, Faculty of Medicine, Department of Liver Transplantation Institute and General Surgery, Malatya/TURKEY

³Inonu University, Faculty of Medicine, Department of Medical Microbiology, Malatya/TURKEY

⁴Inonu University, Faculty of Medicine, Department of Pathology, Malatya /TURKEY

⁵Inonu University, Faculty of Medicine, Department of Biostatistics, and Medical Informatics, Malatya /TURKEY

⁶Inonu University, Faculty of Medicine, Department of Liver Transplantation Institute and General Surgery, Malatya /TURKEY

Abstract

Aim: We aimed to evaluate the clinical variations, possible risk factors and results of diagnostic procedures in liver transplant (LT) recipients who suffered from Herpes Simplex Virus (HSV) viremia in the post-transplant period, despite Cytomegalovirus (CMV) prophylaxis.

Material and methods: The data of 1100 LT recipients were evaluated retrospectively. HSV DNA RT-PCR detected in blood and vesicular fluid samples of the patients with active painful mucocutaneous vesicular lesions and patients with organ involvement who had biopsy and confirmed HSV viremia were included in the study. The 110 recipients diagnosed with HSV viremia were included.

Results: In 110 recipients, total 130 HSV viremia episodes were observed over sixty months. HSV viremia rate was 11.8%. Of the 130 HSV episodes, 120 (92.3%) were mucocutaneous form of the disease. In 10 cases, there was a specific organ involvement. HSV-1 was detected in all of viremia episodes. Sixty-four (49.2%) episodes developed six months after the LT, 41 (31.5%) episodes developed between the 1st and 6th months after LT, and 25 (20.3%) episodes were observed within the first postoperative month. All episodes were treated successfully with different antiviral therapy modalities.

Conclusion: Despite CMV prophylaxis performed, HSV viremia may be occurred as a wide range of clinical presentation in LT recipients. It can be seen at any time point after the LT. HSV DNA RT-PCR from serum samples may not be sufficient for diagnosis of viremia, therefore the analysis of the vesicular fluid or the biopsy from the organs may be necessary for supporting the diagnosis.

Key words: Liver transplantation; recipients; herpes simplex virus; viremia; acyclovir

Corresponding Author*: Adem Kose, Inonu University, Faculty of Medicine, Department of Infectious Diseases and Clinical Microbiology, Malatya/TURKEY

E-mail: adem.kose@inonu.edu.tr

ORCID: 0000-0002-1853-1243.

Received: 19.06.2021 accepted: 23.07.2021

Doi: 10.18663/tjcl.954392

Öz

Amaç: Karaciğer nakli (LT) alıcılarında, Sitomegalovirüs (CMV) profilaksisine rağmen nakil sonrası dönemde gelişen Herpes simpleks virüsü (HSV) viremisinin klinik varyasyonlarını, olası risk faktörlerini, tanı prosedürlerini ve sonuçlarını değerlendirmeyi amaçladık.

Gereç ve Yöntemler: 1100 karaciğer nakli alıcısının verileri geriye dönük olarak değerlendirildi. Çalışmaya aktif ağırlı mukokutanöz veziküler lezyonları olan hastaların kan ve veziküler sıvı örneklerinde saptanan HSV DNA RT-PCR ve doku biyopsisi yapılan ile HSV viremisi doğrulanan ve organ tutulumu bulguları olan hastalar dahil edildi. HSV viremisi tanısı alan 110 karaciğer nakli alıcısı tespit edildi.

Bulgular: 110 alıcıda altmış ay boyunca toplam 130 HSV viremi atağı gözlemlendi. HSV viremisi oranı %11,8 idi. 130 HSV atağının 120'si (%92,3) hastalığın mukokutanöz formu idi. 10 olguda spesifik bir organ tutulumu vardı. Tüm viremi ataklarında HSV-1 saptandı. Karaciğer naklinden altı ay sonra 64 (%49,2) atak gelişti, Karaciğer nakli sonrası birinci ve altıncı aylar arasında 41 (%31,5) atak gelişti ve postoperatif ilk ayda 25 (%20,3) atak gözlemlendi. Tüm ataklar farklı antiviral tedavi yöntemleri ile başarılı bir şekilde tedavi edildi.

Sonuç: Yapılan CMV profilaksisine rağmen, HSV viremisi, karaciğer nakli alıcılarında geniş bir klinik yelpazede ortaya çıkabilir. Serum örneklerinden alınan HSV DNA RT-PCR'in viremi tanısı için her zaman yeterli olmayabilir, bu nedenle tanıyı desteklemek için veziküler sıvının analizi veya organlardan biyopsi yapılması gerekebilir.

Anahtar Kelimeler: Karaciğer nakli; alıcılar; herpes simpleks virüsü; viremi; asiklovir

Introduction

Viral infections are a serious threat for the liver transplant (LT) recipients in the post-transplantation period; among these Herpes Simplex Virus (HSV) is the second most common viral pathogen after Cytomegalovirus (CMV) [1]. HSV-1 and HSV-2 belong to the alpha-herpes group containing linear, double-stranded deoxy-ribonucleic acid (DNA), forming infections on mucocutaneous surfaces, central nervous system and visceral organs [2].

Viral shedding is observed more frequently in solid organ transplant (SOT) recipients compared to immunocompetent individuals. However, it is also more common than the severe clinical manifestations of HSV [3]. In LT recipients, the most common source of HSV viremia is asymptomatic individuals; but it can also sometimes be transmitted through contact with symptomatic individuals with active lesions on mucocutaneous surfaces. However, HSV viremia can also rarely present as primary infection in LT recipients who have never encountered the virus before [4]. Immunosuppressive treatment is the main cause of reactivation of HSV viremia; and also increases the risk of latent infection all of which are frequently observed between the 1st and 6th months following LT [5]. Mucocutaneous involvements are the most common form of clinical presentation, but they can also emerge as

pneumonia, encephalitis and esophagitis [6]. The guidelines do not recommend routine screening to detect the presence of HSV. However, HSV DNA real-time polymerase chain reaction (RT-PCR) can be studied from blood and vesicular fluid samples if the recipient has active herpetic lesions and in the presence of unexplained cytopenia combined with high liver function tests [7]. The gold standard method for diagnosis is viral culture, but it is expensive and requires longer time. Therefore, HSV DNA RT-PCR testing has currently replaced viral culture and direct fluorescent antibody (DFA) tests. The sensitivity of HSV DNA RT-PCR testing is four-times higher than viral culture for the diagnosis of mucocutaneous lesions [8]. In all current guidelines, while recommending to use only prophylaxis against CMV to prevent the development of viral infections after SOTs, routine prophylaxis for HSV is not recommended [9]. However, antiviral therapies (valganciclovir) used in CMV prophylaxis also have little antiviral activity against HSV-1 and 2. HSV reactivation rates were approaching 75% before universal prophylaxis was used in LT recipients; but these rates decreased significantly after the CMV prophylaxis entered routine practice [10]. Although there are several studies or case series for HSV viremia in the literature, high-volume studies are lacking.

The present study aims to evaluate the clinical presentation, potential risk factors for developing HSV viremia and results of diagnostic procedures in 110 LT recipients who developed viremia in the post-LT period in our Liver Transplant Institute, despite receiving CMV prophylaxis.

Materials and Methods

Study Cohort and Design

We required that at least one year follow up data of the LT recipients to be available in order to be included in the study for evaluation. Patients older than 18 years that had received LT in our institute who have a complete follow up data available were included for this study. Patients who were transplanted in other centers but came to us for a follow up program, pediatric patients and patients whose data were not available were excluded from the study. The data of patients who were retrospectively reviewed from our hospital's patient registration database. Ethical approval was obtained from the Inonu University non-interventional ethics committee (approval no: 2020/292). The necessary permissions were taken from the Liver Transplantation Institute. In total 1100 LT patients were evaluated between 01 July 2013-2019. The demographic data including, age, gender, clinical data including the cause of end stage liver diseases (ESLD), type of comorbidities, the postoperative course and the observed complications and finally operative data including the type of graft, model for end stage liver disease (MELD) were included for analysis in our study.

Diagnosis of patients with HSV infection

In case of high clinical suspicion, HSV-DNA PCR was studied from serum and vesicular fluid samples of the patients with HSV viremia who have active tender mucocutaneous involvement. If organ involvement is suspected, mucocutaneous biopsies are obtained in order to confirm the diagnosis by RT-PCR. Furthermore, if the affected organ was accessible by endoscopy, endoscopic biopsies had been performed for both direct fluorescent antibody detection and HSV-DNA PCR. In patients with organ involvement, skin and endoscopic biopsy were performed and HSV DNA RT-PCR was studied on the biopsy materials. In addition, HSV DNA RT-PCR was studied on cerebrospinal fluid (CSF) sample when central nervous system (CNS) involvement was suspected but plasma sample resulted as negative for HSV-DNA RT PCR.

Pathological studies

Endoscopic esophageal biopsy was performed in one patient diagnosed with herpes esophagitis. A buccal mucosal biopsy was performed in another patient having findings of diffuse vesicular stomatitis and diagnosed with disseminated form.

Pathologic evaluation includes standard hematoxylin-eosin staining for cytopathic effects of the virus. Typical microscopic characteristics if HSV infections are ulceration on the surface of the epithelial surfaces and the fragmented adjacent squamous epithelial cell are observed (Figure 1). The typical cytopathic effects are nuclear enlargement, multinucleation and intranuclear inclusion that are scattered in the epithelial cells in the ulcerated area. Immunohistochemical analysis is performed to confirm the presence of HSV antigens in these areas of cytopathic effect (Figure 2).

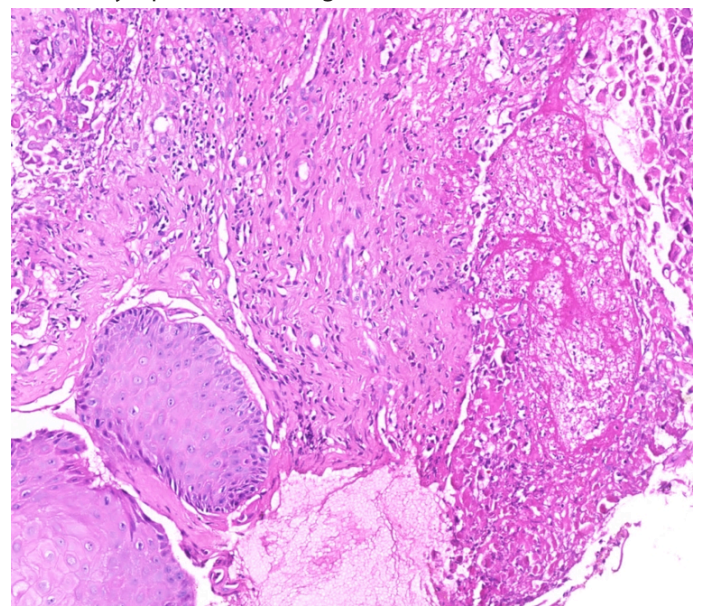


Figure 1: Squamous epithelial fragment (right side) is seen adjacent to the ulcerated (left side) oral mucosa. H&E x5.

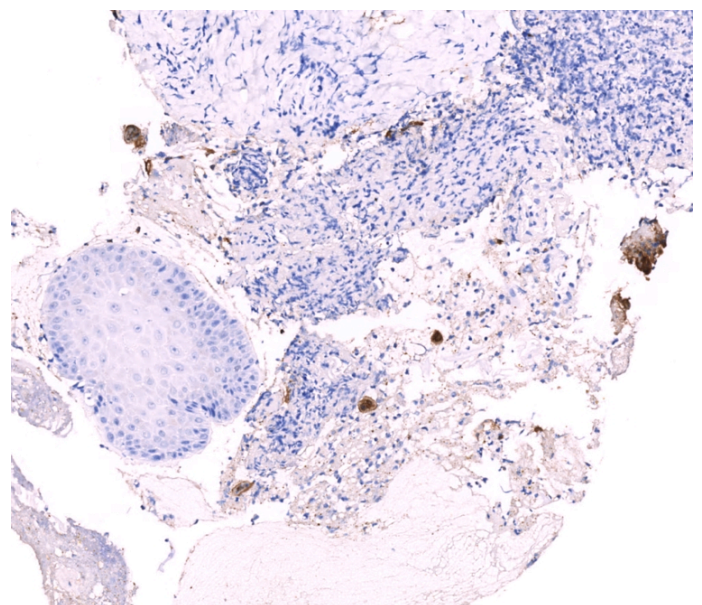


Figure 2: Two cells positively stained with HSV-1 antibody in the area of the ulcer (brown staining). HSV antibody x5.

Management of HSV infection episodes

Oral treatment with valganciclovir 2 g twice daily or acyclovir 400 mg five times a day was preferred for cases with a single lesion and abnormal liver function tests. Intravenous acyclovir 5 mg/kg three times daily was applied to cases with signs of organ involvement or disseminated cases with normal renal function tests. In addition, intravenous acyclovir 10 mg/kg three times daily was applied to one case with signs of encephalitis [11]. The doses and duration to antiviral treatments were retrospectively analyzed from infectious diseases consultation records, and daily treatment order forms of the patients.

Microbiological Studies

HSV genome was extracted from the clinical samples with using EZ1 DNA extraction kit (Qiagen, Hilden, Germany). Nucleic acid amplification was performed with artus HSV 1/2 QS-RGQ kit (Qiagen, Hilden, Germany) in Rotor Gene-Q device (Qiagen, Hilden, Germany). The real-time PCR kit that was used in this study was CE certificated, and the manufacturer reported that it had the lowest limit of detection as 57.2 copy/ml (95%CI: 39 to 95 copy/ml).

Statistical Analyses

Data were given as median (min-max) and count (percent). Compliance with the normal distribution was done with the Kolmogorov-Smirnov test. Continuous and categorical variables compared using Mann-Whitney U test, Pearson chi-square test, Yate's corrected chi-square test, Fisher exact chi-square test. Multivariate logistic regression analysis was applied for odds ratio estimations and determination of independent risk factors. A $p < 0.05$ was considered statistically significant. IBM SPSS Statistics 26.0 program was used in the analysis.

Results

The mean age of the patients was 47.8 ± 13.7 years. Seven hundred fifty-four (68.55%) patients were male and 346 (31.45%) were female. In total, 983 (89.36%) patients received living donor LT and 117 (10.64%) patients received deceased donor. Fifty-two (4.72%) patients had to be re-transplanted. Hepatocellular cancer was present in 183 (16.63%) patients. Fifty-one (4.63%) patients received Anti-thymocyte globulin (ATG) and pulse prednisolone treatment (1 g/day, three day) due to acute rejection. In 61 (5.54%) patients' chronic rejection developed. The etiologies of ESLD are summarized in Table 1.

Table 1: The etiologies of ESLD

The etiologies of ESLD	Number (n)	Percentage (%)
HBV	403	36.64
Cryptogenic reasons	280	25.48
Other reasons (HBV+HCV, HCC, hydatid cyst, primary biliary cirrhosis, etc...)	101	9.18
HCV	78	7.09
HBV+HDV	55	5.00
Budd-Chiari syndrome	53	4.81
Alcoholic hepatitis	40	3.63
Autoimmün hepatitis	33	3.00
Toxic hepatitis (drug-induced, mushroom, etc.)	29	2.63
Wilson disease	28	2.54
Total	1100	100

ESLD: End stage liver disease. HBV: Hepatit B Virus, HCV: Hepatit C Virus, HDV: Hepatit D Virus

As a result of the statistical analyzes performed, advanced age, presence of acute rejection, pulse prednisolone (1 g/day, three day) and ATG therapies, presence of chronic rejection, and source of donor were statistically significant for developing HSV viremia ($p < 0.05$). Our results showed that the risk of developing HSV viremia increases 1.021 times for every 1-unit increase in age ($p=0,006$; CI: (1,006-1,035)). The presence of acute rejection episodes and need for pulse prednisolone and ATG therapies increased the risk of HSV viremia by 172,752 times ($p < 0,001$; CI: (59,982-497,537)). In the presence of chronic rejection, the risk of HSV viremia increases 2,947 times ($p=0,004$; CI: (1,421-6,114)). The variables such as; gender, etiology of ESLD, presence of re-transplantation, hepatocellular cancer and concomitant infections (pneumonia, surgical site infection, urinary tract infection and sepsis, etc.) did not have statistical significance. The identified potential risk factors for HSV viremia are summarized in Table 2.

A total of 2160 HSV DNA RT-PCR tests (at least one, at most twenty times) were performed on plasma samples and 2080 (96.3%) were negative. Eighty tests were performed to (3.7%) 60 patients which gave positive results. Fifty-three of these 60 patients had mucocutaneous diseases, specific organ involvements or disseminated infections. HSV DNA RT-PCR from vesicular fluid was studied simultaneously with plasma samples from 60 patients and 50 cases were resulted in a positive. A buccal biopsy was performed in one disseminated case, and an endoscopic esophageal biopsy was performed in one patient, HSV DNA RT-PCR test was performed on the biopsy tissue samples and were resulted as positive. In one case

with signs of encephalopathy, HSV DNA RT-PCR test on CSF simultaneously with plasma sample was positive. In addition, orolabial herpetic lesions were detected in 57 patients with negative HSV DNA RT-PCR test results from plasma samples, but HSV DNA RT-PCR tests studied from simultaneous vesicular fluid samples of these patients were positive. The positive predictive value of HSV DNA RT-PCR test was calculated as 88.3% and the negative predictive value was 92.37 % in vesicular fluid samples in patients diagnosed with HSV viremia. Total 130 viremia episodes developed in the 110 (57 plus 53) of the 1100 recipients. Of the 130 HSV viremia episodes, 120 (92.3%) were occurred with mucocutaneous lesions. Ten patients were emerged in specific organ involvement and

disseminated course. HSV-1 was detected in all of viremia episodes, HSV-2 was not detected at all. Only one viremia episode developed in 92 patients and more than one episode (at least two, at most eight) were observed in 18 patients. Sixty-four (49.2%) viremia episodes were observed after the sixth months, 41 (31.5%) attacks between the first and sixth months, and 25 (20.3%) attacks within the first 30 days after the LT. HSV viremia rate was calculated as 11.8% in all of the recipients. All viremia episodes have been successfully treated with different antiviral therapy modalities. Diagnostic procedures, HSV DNA RT-PCR results, clinical manifestations, distribution of the HSV viremia episodes according to post-transplant periods and applied treatment modalities were given in Table 3.

Table 2: The identified possible risk factors for HSV viremia episodes

PARAMETERS		HSV viremia episodes		p value
		Negative Count (Percent)	Positive Count (Percent)	
Gender	Male	672a (68,36%)	82a (70,09%)	0,704
	Female	311a (31,64%)	35a (29,91%)	
The sources of donor	Living donor	96a (9,77%)	22b (18,80%)	0,003
	Cadaveric donor	887a (90,23%)	95b (81,20%)	
The reasons of ESLD	HBV	360a (37,00%)	41a (35,04%)	0,073
	Cryptogenic reasons	245a (25,18%)	33a (28,21%)	
	Other reasons HBV+HCV, HCC, hydatid cyst, etc...)	100a (10,28%)	7a (5,98%)	
	HCV	62a (6,37%)	15a (12,82%)	
	HBV+HDV	47a (4,83%)	7a (5,98%)	
	Budd-Chiari syndrome	45a (4,62%)	6a (5,13%)	
	Alcoholic hepatitis	36a (3,70%)	0a (0,00%)	
	Autoimmune hepatitis	27a (2,77%)	5a (4,27%)	
	Toxic hepatitis (drug-induced, mushroom, etc.)	26a (2,67%)	2a (1,71%)	
	Wilson disease	25a (2,57%)	1a (0,85%)	
The presence of re-transplantation	No	40a (4,07%)	9a (7,69%)	0,119
	Yes	943a (95,93%)	108a (92,31%)	
The presence of hepatocellular cancer	No	166a (16,89%)	17a (14,53%)	0,606
	Yes	817a (83,11%)	100a (85,47%)	
The presence of acute rejection	No	979a (99,59%)	70b (59,83%)	<0,001
	Yes	4a (0,41%)	47b (40,17%)	
The presence of chronic rejection	No	933a (94,91%)	105b (89,74%)	0,038
	Yes	50a (5,09%)	12b (10,26%)	
Pulse prednisolone treatment (1 g/day, three day)	No	979a (99,59%)	70b (59,83%)	<0,001
	Yes	4a (0,41%)	47b (40,17%)	
Anti-thymocyte globulin treatment	No	979a (99,59%)	70b (59,83%)	<0,001
	Yes	4a (0,41%)	47b (40,17%)	
The presence of concomitant bacterial infections	No	884a (89,93%)	100a (85,47%)	0,185
	Yes	99a (10,07%)	17a (14,53%)	
Ages	Median (min-max)	Median (min-max)		
		48 (0-74)	52 (20-71)	0,003

Table 3: Diagnostic procedures, HSV DNA RT-PCR results, clinical manifestations, distribution of the HSV viremia episodes according to post-transplant periods and applied treatment modalities.

Diagnostic procedures and HSV DNA PCR results	Number (n)	Percentage (%)
Total HSV DNA PCR in plasma samples	2160	100
Negative HSV DNA PCR test results	2080	96.3
Positive HSV DNA PCR test results	80	3.7
Positive predictive value of HSV DNA PCR	-	88.3
Negative predictive value of HSV DNA PCR	-	92.37
Number of patients with HSV DNA PCR test positive result	60	-
• Patients with HSV DNA PCR test plasma+/vesicular fluid-	7	-
• Patients with HSV DNA PCR test plasma+/vesicular fluid+	50	45.5
• Patients with HSV DNA PCR test plasma+/endoscopic esophageal biopsy+	1	0.9
• Patients with HSV DNA PCR test plasma+/buccal mucosal biopsy+	1	0.9
• Patients with HSV DNA PCR test plasma+/CSF+	1	0.9
Patients with HSV DNA PCR test blood-/vesicular fluid+	57	51.8
Patients developing HSV viremia	110	100
Total number of HSV viremia episodes	130	-
The rate of patients with HSV viremia (110/1100)	-	10.0
The rate of HSV viremia episode (130/1100)	-	11.8
Clinical manifestations (n=147)		
Mucocutaneous involvements	120	92.3
• Herpes labialis	80	61.5
• Oral herpes	28	21.5
• Nasolabial herpes	12	9.3
Disseminated infection	8	6.1
Herpetic encephalitis	1	0.8
Herpetic esophagitis	1	0.8
Distribution of the HSV attacks according to post-transplant periods		
Period between 0-1 months	25	20.3
Period between 1-6 months	41	31.5
Period after 6 months	64	49.2
Applied treatment modalities of HSV viremia episodes (n=147)		
Valacyclovir 2x2 g (only 24 hours)	20	15.4
Acyclovir 5x400 mg po (7-10 days)	28	21.5
Acyclovir 3x5 mg/kg/day iv (10-14 days)	82	63.1

Discussion

In this study, we evaluated the potential risk factors for developing HSV viremia in 1100 LT recipients in the post-transplant period, despite appropriate CMV prophylaxis. The results of diagnostic procedures and clinical presentations of HSV viremia episodes in LT recipients were evaluated. To our knowledge, this is the first study that is a single-center high-volume study, which evaluates the of HSV viremia in LT recipients.

The potential risk factors for developing viral infections are age, gender, body mass index (BMI), cause of ESLD, presence comorbidities, MELD score, intraoperative (the amount of transfused erythrocyte suspension) and postoperative conditions [need Continuous Venous-Venous Hemofiltration (CVVH), presence of septic shock] in the LT recipients .[11] In our

current study, we found that advanced age, presence of acute rejection, need for pulse prednisolone (1 g/day, three day) and ATG therapies, presence of chronic rejection, and the source of donor that is transplanted may play a role for developing HSV viremia. The risk of developing HSV viremia increases 1.021 times for every 1-unit increase in ages, 172,752 times in the presence of acute rejection-pulse prednisolone (1g/day, three days)-ATG therapies, 2,947 times in the presence of chronic rejection.

HSV viremia is often diagnosed with clinical findings. HSV DNA RT-PCR is usually preferred because it is the most sensitive test for the diagnosis and can be studied from many sample types, including blood, vesicular fluid, respiratory secretions and CSF [12]. HSV DNA RT-PCR is crucial for the diagnosis of encephalitis, but it is not recommended to be routinely studied

for the detection of mucocutaneous lesion [13]. In our study, we were studied HSV DNA RT-PCR test on plasma and vesicular fluid (as possible) in all the patients if cytopenia, elevated liver enzymes and having mucocutaneous lesion were present. HSV DNA RT-PCR positivity from plasma is not sufficient for the definitive diagnosis of HSV infection. Therefore, in our study tissue biopsy was performed in two cases with suspected visceral organ involvement and HSV DNA RT-PCR was studied. Similarly, this test was studied from plasma and CSF in a case with signs of encephalitis.

Our results showed that HSV viremia rate was 11.8% in LT recipients. Busch et al. in a six - year retrospective study involving 530 LT recipients found that 126 viral infection episodes were determined in the first three months after LT [14]. The most common of all was CMV (54.3%) and the second was HSV-1 (22.5%) infections. Furthermore, Martin-Gandul et al. showed that 2781 patients with different organ transplants, showed that the incidence of HSV infection developed in the first, third and sixth years after transplantation that varied according to transplanted organ types in 2781 solid organ transplant recipients [15]. They reported that HSV episode rates were 9.4% for heart, 8.4% for liver, 6.5% for kidney and 1.8% for lung transplant recipients, and the incidence of HSV infection was 28.9 cases per 1000 people. The incidence of HSV infection one year after transplantation was 4.6% and 12.3% in patients with and without antiviral prophylaxis. It was found that the first HSV infection episode was seen nearly on 66 days after the LT. In a study with 98 patients who underwent pancreas and kidney transplantation by Netchiporouk et al. , it was reported that the incidence of HSV infection was 10% and 80% of the attacks developed in the first two years, and the highest incidence was 40% which was in the postoperative first month [16].

A study conducted by Lakeman et al. involving 54 patients diagnosed who had herpes encephalitis, showed that in CSF, HSV DNA RT-PCR positive predictive and negative predictive values were 95% and 98%; respectively [17]. Moreover, Jazeron et al. reported that HSV DNA RT-PCR performed on biopsy material had a positive predictive and negative predictive values of 66.7% and 96%; respectively in 53 patients with herpes esophagitis [18]. In our current study, the positive and negative predictive values were 88.3% and 92.37%; respectively in vesicular fluid samples. These values were considered to be compatible with the results obtained in similar studies in the literature above mentioned.

Clinical findings of the HSV viremia may range from limited mucocutaneous involvement to disseminated infections

involving visceral organs and the CNS [19]. The clinical course may be more severe and insidious in LT recipients; additionally, the response to the antiviral therapy is slower [20]. Although mucocutaneous involvements are usually asymptomatic, diffuse mucocutaneous lesions may occur and, if progressive, may extend to the esophagus or lung [21]. In our study, we detected the mucocutaneous involvement in 92.3% of the patients, disseminated disease were in 6.1% of the patients, Also, it was observed that majority of the patients who developed more than one viremia episode had acute and/or chronic rejection. While HSV viremia episodes were observed more frequently in the first month after LT in recipients who experienced an acute rejection episode that required intensive immunosuppressive treatment, in recipients with uneventful postoperative clinical course, HSV viremia episodes were more common after the sixth postoperative month. We had seen that the highest incidence in the term of after postoperative six months.

Most transplant centers prefer to initiate early treatment including nucleoside analogues (oral acyclovir, valaciclovir or famciclovir) for the treatment of limited mucocutaneous involvement in the immunocompromised patient; and usually, continue the treatment until the lesions are completely recovered or for a minimum of 5-7 days. Wider lesions can be treated with 5-10 mg/kg intravenous acyclovir 3 times a day [22]. If the patient has disseminated disease, visceral or central nervous system involvement, the therapy should be started promptly at a minimum dose of 10 mg/kg intravenously. Most clinicians prefer to administer the therapy for 14-21 days in disseminated diseases [23]. Before starting antiviral therapy, the dose of immunosuppressive drugs should be reduced or even completely discontinued in patients diagnosed with a life-threatening disseminated disease. In this study, first of all, we reduced or completely discontinued the doses of all immunosuppressive therapies in patients with signs of disseminated disease. Then, all of the episodes were successfully treated with different antiviral therapy modalities, and all of the patients had fully recovered without complications.

The retrospective design of the study is the major limitation of the present study. It precludes our capacity to reach all the data required for the analysis in our study. Therefore, in this study the effects of different immunosuppression protocols applied after LT on HSV viremia episodes could not be examined. Second, we could not reach to serological test results of most of the donors and recipients before LT. For this reason, the conclusions that can be deduced from our results should be approached with caution.

Conclusion

Despite CMV prophylaxis performed, HSV viremia may be occurred as a wide range of clinical presentation in LT recipients. It can be seen at any time point after the LT. HSV DNA RT-PCR from serum samples may not be sufficient for diagnosis of viremia, therefore the analysis of the vesicular fluid or the biopsy from the organs may be necessary for supporting the diagnosis. If early therapy initiated, the results may be satisfactory. However, more comprehensive multicenter studies are needed in LT recipients.

Declaration of conflict of interest

The authors received no financial support for the research and/or authorship of this article. There is no conflict of interest

References

1. Zuckerman R, Wald A, AST Infectious Diseases Community of Practice. Herpes simplex virus infections in solid organ transplant recipients. *Am J Transplant.* 2009; 9: 104-7.
2. Whitley RJ, Roizman B. Herpes simplex virus infections. *Lancet.* 2001; 357: 1513-8.
3. Greenberg MS, Friedman H, Cohen SG, et al. A comparative study of herpes simplex infections in renal transplant and leukemic patients. *J Infect Dis* 1987; 156: 280-7.
4. Zuckerman RA, Limaye AP. Varicella-zoster virus (VZV) and herpes simplex virus (HSV) in solid organ transplant patients. *Am J Transplant* 2013; 13: 55-66.
5. Jenkins FJ, Rowe DT, Rinaldo CR Jr. Herpesvirus Infections in Organ Transplant Recipients. *Clin Diagn Lab Immunol.* 2003; 10: 1-7.
6. Mossad SB. Management of Infections in Solid Organ Transplant Recipients. *Infect Dis Clin North Am.* 2018; 32: 13-4.
7. Fishman JA. Overview: cytomegalovirus and the herpesviruses in transplantation. *Am J Transplant.* 2013; 13: 1-8.
8. Singh A, Preiksaitis J, Ferenczy A, Romanowski B. The laboratory diagnosis of herpes simplex virus infections. *Can J Infect Dis Med Microbiol.* 2005; 16: 92-8.
9. Wilck MB, Zuckerman RA, AST Infectious Diseases Community of Practice. Herpes simplex virus in solid organ transplantation. *Am J Transplant.* 2013; 13: 121-7.
10. Lee DH, Zuckerman RA, AST Infectious Diseases Community of Practice. Herpes simplex virus infections in solid organ transplantation: Guidelines from the American Society of Transplantation Infectious Diseases Community of Practice. *Clin Transplant.* 2019; 33: 13526.
11. van Hoek B, de Rooij BJ, Verspaget HW. Risk factors for infection after liver transplantation. *Best Pract Res Clin Gastroenterol.* 2012; 26 :61-72.
12. Singh A, Preiksaitis J, Ferenczy A, Romanowski B. The laboratory diagnosis of herpes simplex virus infections. *Can J Infect Dis Med Microbiol.* 2005; 16: 92-8.
13. Wald A, Huang ML, Carrell D, Selke S, Corey L. Polymerase chain reaction for detection of herpes simplex virus (HSV) DNA on mucosal surfaces: comparison with HSV isolation in cell culture. *J Infect Dis.* 2003; 188 :1345-51.
14. Busch CJ, Siegler BH, Werle H, et al. Risk factors for early viral infections after liver transplantation. *Langenbecks Arch Surg.* 2018; 403 :509-19.
15. Martin-Gandul C, Stampf S, Hequet D, et al. Preventive strategies against cytomegalovirus and incidence of alpha-herpesvirus infections in solid organ transplant recipients: a nationwide cohort study. *Am J Transplant.* 2017; 17 :1813-22.
16. Netchiporouk E, Tchervenkov J, Paraskevas S et al. Evaluation of herpes simplex virus infection morbidity and mortality in the pancreas and kidney-pancreas transplant recipients. *Transplant Proc.* 2013; 45 :3343-7.
17. Lakeman FD, Whitley RJ. Diagnosis of herpes simplex encephalitis: application of polymerase chain reaction to cerebrospinal fluid from brain-biopsied patients and correlation with disease. National Institute of Allergy and Infectious Diseases Collaborative Antiviral Study Group. *J Infect Dis.* 1995; 171 :857-63.
18. Jazeron JF, Barbe C, Frobert E et al. Virological diagnosis of herpes simplex virus 1 esophagitis by quantitative real-time PCR assay. *J Clin Microbiol.* 2012; 50 :948-52.
19. Fishman JA, Issa NC. Infection in organ transplantation: risk factors and evolving patterns of infection. *Infect Dis Clin North Am.* 2010; 24: 273-83.
20. Linde A. The importance of specific virus diagnosis and monitoring for antiviral treatment. *Antiviral Res.* 2001; 51 :81-94.
21. Hirschi S, Biondini D, Ohana M, et al. Herpes simplex virus 2 hepatitis in a lung transplant recipient: a diagnostic challenge. *Transpl Infect Dis.* 2015; 17 :904-8.
22. Razonable RR. Management of viral infections in solid organ transplant recipients. *Expert Rev Anti Infect Ther.* 2011; 9 :685-700.
23. Abad CL, Razonable RR. Treatment of alpha and beta herpesvirus infections in solid organ transplant recipients. *Expert Rev Anti Infect Ther.* 2017; 15 :93-110.