





# Oncological and Functional Outcomes of Supracricoid Partial Laryngectomy

Mustafa Caner Kesimli<sup>1</sup> , Eren Yılmaz<sup>2</sup> , İbrahim Yağcı<sup>1</sup> , İsmet Aslan<sup>3</sup> 

<sup>1</sup>Istinye University School of Medicine, Department of Otolaryngology, Head and Neck Surgery, Istanbul, Turkey

<sup>2</sup>Istanbul Gelisim University, Faculty of Health Sciences, Istanbul, Turkey

<sup>3</sup>Istanbul University School of Medicine, Department of Otolaryngology, Head and Neck Surgery, Istanbul, Turkey

**ORCID ID:** M.C.K. 0000-0003-1675-0394; E.Y. 0000-0002-5349-9699; İ.Y. 0000-0003-2039-8362; İ.A. 0000-0001-5144-1832

**Citation:** Kesimli MC, Yilmaz E, Yagci I, Aslan I. Oncological and functional outcomes of supracricoid partial laryngectomy. Tr-ENT 2021;31(3):75-80. <https://doi.org/10.26650/Tr-ENT.2021.970267>

## ABSTRACT

**Objective:** The aim of this study is to review the oncological outcomes of T1-T4 glottic or supraglottic tumor patients who underwent supracricoid partial laryngectomy in our clinic.

**Material and Methods:** A total of 43 patients with laryngeal squamous cell carcinoma who underwent supracricoid partial laryngectomy between January 2014 and December 2016 in the Otorhinolaryngology Department of Istinye University Hospital were retrospectively analyzed. Postoperative data of these patients regarding surgical margin, nasogastric feeding tube removal time, decannulation time, postoperative radiotherapy, local regional recurrence, and distant metastases were recorded.

**Results:** Cricohyoidoepiglottopexy was applied to 16 patients by preserving both arytenoids and applied to 7 patients with a single arytenoid; Cricohyoidopexy was applied to 14 patients with both arytenoids preserved, and 6 patients were treated with a single arytenoid.

The five-year survival was compared for Cricohyoidopexy/Cricohyoidoepiglottopexy with single arytenoid to double arytenoid preservation and found to be 80%-76% ( $p=0.56$ ). The mean 5-year survival was 88% in the post-operative radiotherapy group, and 86% in the non- radiotherapy group. The study compared patients with Cricohyoidopexy/Cricohyoidoepiglottopexy with a single arytenoid to those with double arytenoid preservation; the mean decannulation time was  $54.23\pm 34.12$  to  $35.62\pm 27.08$  ( $p=0.05$ ). Postoperative radiotherapy prolonged the decannulation time ( $51.16\pm 38.5$  versus  $32.68\pm 20.1$ ;  $p=0.043$ ). The duration of nasogastric tube placement in the Cricohyoidopexy/Cricohyoidoepiglottopexy with a single arytenoid group was  $50.3\pm 14.3$  and double arytenoid preservation was  $35.17\pm 32.9$  ( $p=0.088$ ). Nasogastric tube removal time was  $53.29\pm 50.2$  in the post-operative radiotherapy group and was  $30.24\pm 16.8$  in patients who did not receive post-operative radiotherapy ( $p=0.040$ ).

**Conclusion:** Supracricoid partial laryngectomy with Cricohyoidoepiglottopexy and Cricohyoidopexy had satisfactory oncological outcomes, and laryngeal function was preserved by rebuilding the neolarynx.

**Keywords:** Partial laryngectomy, Head and neck carcinoma, Cricohyoidopexy, Cricohyoidoepiglottopexy, Supracricoid laryngectomy

## INTRODUCTION

The larynx is an important organ in the upper airway with three main functions: speaking, breathing and swallowing. Anatomically, it is divided into three regions: the supraglottic larynx, the glottis, and the subglottic region (1).

Laryngeal cancers are the most common malignant tumors of the upper airway and most commonly originate from the glottic region (1, 2). More than 98% of laryngeal malignancies are well-differentiated squamous cell carcinomas; only 2% are chondrosarcomas, leiomyosarcomas, and melanomas (3).

There are various surgical and nonsurgical oncological options in the treatment of laryngeal cancers (4). It has been reported that organ preservation strategies based on the combination of chemotherapy and radiotherapy (RT) achieve oncological results similar to surgery, but they cause significant toxic effects (4, 5). In addition, the oncological results of chemoradiation protocols are not as good as surgery, and the functional results are poor in cases of invasion of the cartilage of the larynx or in bulky tumors (6).

In recent years, surgical treatment of laryngeal cancer has shifted from radical (total laryngectomy [TL]) to more

**Corresponding Author:** Mustafa Caner Kesimli **E-mail:** canerkesimli@gmail.com

**Submitted:** 16.07.2021 • **Revision Requested:** 18.10.2021 • **Last Revision Received:** 19.10.2021 • **Accepted:** 19.10.2021 • **Published Online:** 04.11.2021



This work is licensed under Creative Commons Attribution-NonCommercial 4.0 International License.

conservative surgical techniques (partial laryngectomies) in selected patients (7). Local control and survival rates are similar (1, 7). The most important advantage of partial laryngectomy is the preservation of the functions of the larynx, which provides a better quality of life (normal speech and swallowing and the absence of a permanent tracheostomy) (8, 9).

One of these conservative procedures, supracricoid partial laryngectomy (SCPL), was first described by Majer and Rieder in 1951 (10). Resection includes both true and false vocal cords, the paraglottic space, and the entire thyroid cartilage. If necessary, the epiglottis and pre-epiglottic space and a complete arytenoid cartilage can be included in the resection. The reconstruction is called cricothyroidopexy (CHP) if it is performed with 5 sutures that firmly join the cricoid to the hyoid bone, or cricothyroidoepiglottopexy (CHEP) if it is sutured with the epiglottis preserved (10).

SCPL is a partial laryngectomy technique that allows safe resection of selected T1-T4 glottic or supraglottic tumors. The aim of this study is to review the oncological outcomes of patients who underwent SCPL in our clinic.

## MATERIAL AND METHODS

A total of 43 patients with laryngeal squamous cell carcinoma (LSCC) who underwent SCPL between January 2014 and December 2016 in the Otorhinolaryngology Department of Istinye University Hospital were retrospectively analyzed.

Pathological diagnosis was confirmed by preoperative biopsy in all patients.

Once LSCC was diagnosed, a multidisciplinary team of ENT, oncologists, radiotherapists, and radiologists discussed the diagnosis and treatment alternatives with patients and their families to make a decision. Tumor location and size, extent of tumor invasion, and regional lymph node metastases were assessed by preoperative examinations including contrast-enhanced magnetic resonance imaging and laryngoscopy. Age, gender, smoking, alcohol consumption, TNM stages, and pathology type were documented. Postoperative data of these patients regarding surgical margin, nasogastric feeding tube removal time, decannulation time, postoperative radiotherapy, local regional recurrence, and distant metastases were recorded. Tumor stages were determined according to TNM classification, which was determined according to the 8th edition of the American Joint Committee on Cancer (AJCC) (11).

This research was conducted according to the Declaration of Helsinki for Biomedical Research Involving Human Subjects (WMA; 1997) and was approved by the ethics committee of Istinye University Hospital (2017-KAEK-120)/ 2/2021.G-70). All participants gave written consent after being informed about the procedures and purpose of the study.

## Operations

All patients were treated with CHEP and CHP based on their preoperative assessment, and operated on by the same

surgical team according to the technique previously described. Surgical margins of all laryngeal specimens were examined by pathologists.

## Postoperative care

Nasogastric feeding tube (NGT) and temporary tracheostomy were applied to all patients at surgery. Air humidification was provided with a tracheostomy cannula in all patients and the cannula was cleaned daily. Nutrition of the patients was started with NGT on the first postoperative day. Swallowing exercises were performed first with solid foods, then with liquids on the 20<sup>th</sup> day after surgery. The feeding tube was removed when normal oral feeding was deemed satisfactory. When normal breathing without shortness of breath was maintained for at least 48 hours, the tracheostomy was closed. Postoperative complications were recorded, and related treatments were applied to these patients. Local recurrence, regional recurrence, locoregional recurrence, and distant metastases were recorded and necessary treatments were conducted for these patients.

## Statistical analyses

For statistical analysis, the IBM SPSS Statistics version 21 software package was used. Data are presented as median and range or interquartile range (IQR). The Mann-Whitney test was used to compare continuous variables. The Kaplan-Meier Method (log rank test) was used to calculate the unadjusted survival rate. A p value of less than 0.05 was considered the threshold for statistical significance.

## RESULTS

Our study included 43 patients. CHEP was applied to 16 patients by preserving both arytenoids and applied to 7 patients with a single arytenoid; CHP was applied to 14 patients with both arytenoids preserved, and 6 patients were treated with a single arytenoid. The youngest patient was 32 years old; the oldest patient was 94 years old (32-94/mean 62.4±11.69). 39 patients were male and 4 were female. Simultaneous neck dissection was performed in 38 of the patients. Post-operative radiotherapy (RT)/chemotherapy was applied to 18 patients. The number of patients and adjuvant treatment status (CT/RT) are given in Table 1, and the demographic and clinical data of the patients are given in Table 2.

**Table 1. Number of patients and adjuvant treatment status (KT/RT)**

	RT/KT +	RT/KT -	Total
CHP	9	5	14
CHEP	5	11	16
A-CHP	3	3	6
A-CHeP	1	7	7
<b>Total</b>	<b>17</b>	<b>26</b>	<b>43</b>

CHP: Cricothyroidopexy; CHEP: cricothyroidoepiglottopexy; A-CHP: cricothyroidopexy with preservation of one arytenoid; A-CHeP: cricothyroidoepiglottopexy with preservation of one arytenoid

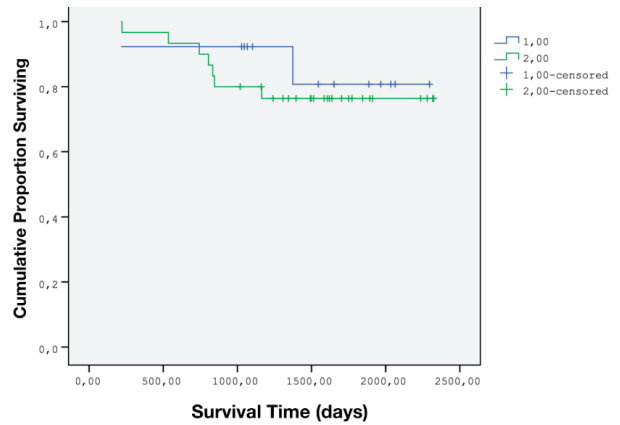
**Table 2. Demographics and clinical characteristics of 43 patients.**

	Mean	Range
Age	62,4	32-94
	n	%
<b>Sex</b>		
Male	39	90,7
Famale	4	9,3
<b>Drinking</b>		
+	10	23,3
-	33	76,7
<b>Smoking</b>		
+	41	95,3
-	2	4,7
<b>Stage</b>		
Early	14	32,5
T2N0	14	32,5
Advanced	29	67,5
T2N1	3	7
T2N2b	3	7
T3N0	7	16,3
T3N1	4	9,3
T3N2b	6	14
T4N0	5	11,6
T4N2a	1	2,3
<b>Neck Dissection</b>		
+	38	88,4
-	5	11,6

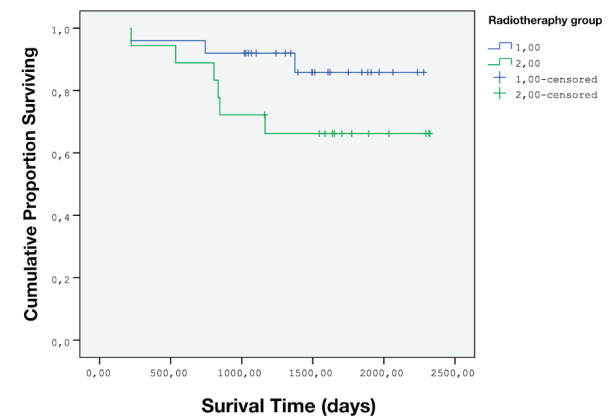
When the five-year survival rate was examined, no significant difference was observed between the patients who underwent CHP/CHEP with single arytenoid and patients with double arytenoid preservation (80%-76%;  $p=0.56$ ) (Figure 1). The mean 5-year survival rate was 88% in the post-operative RT group, and 86% in the non-RT group (Figure 2).

All patients were decannulated, except for one patient who underwent CHP. The earliest postoperative decannulation time was 20 days and the latest was 140 days (mean 41 days). In patients who underwent CHP/CHEP with a single arytenoid compared to those with double arytenoid preservation, the mean decannulation time was  $54.23\pm34.12$  to  $35.62\pm27.08$  ( $p=0.05$ ) (Figure 3). Postoperative radiotherapy prolonged the decannulation time ( $51.16\pm38.5$  versus  $32.68\pm20.1$ ;  $p=0.043$ ) (Figure 4).

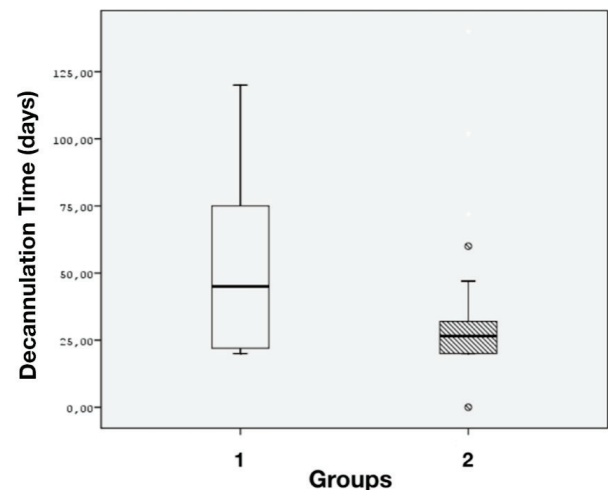
All patients started oral feeding, except for 2 patients, and PEG was opened. NGT removal time was 19 days at the earliest and 110 days at the latest (mean 32). The duration of nasogastric



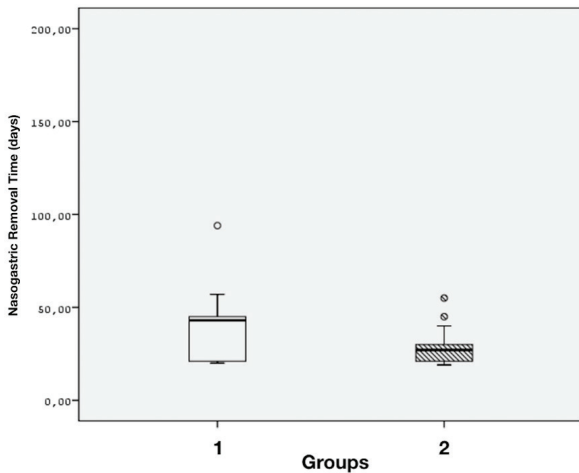
**Figure 1. Kaplan-Meier analysis of disease-specific survival in patients with single arytenoid to double arytenoid preservation. (1- Single arytenoid, 2- Double arytenoid)**



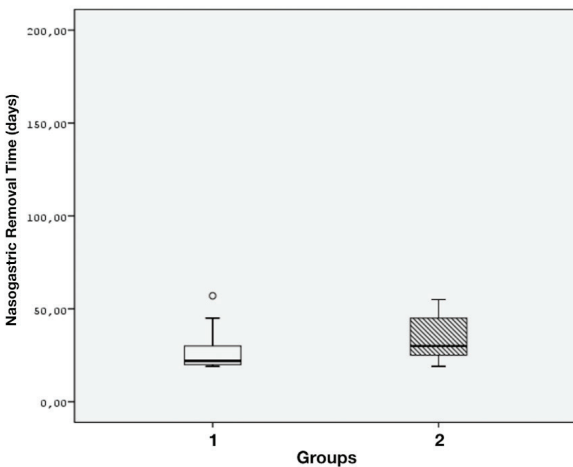
**Figure 2. Kaplan-Meier analysis of disease-specific survival in patients with single arytenoid to double arytenoid preservation. (1- Radiotherapy group, 2- Non-Radiotherapy group)**



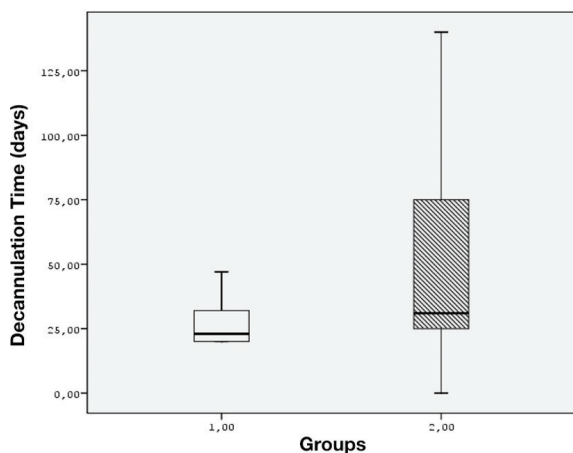
**Figure 3. Comparison of decannulation time between single arytenoid to double arytenoid preservation (1- Single arytenoid, 2- Double arytenoid)**



**Figure 4. Comparison of nasogastric removal time between single arytenoid to double arytenoid preservation (1- Single arytenoid, 2- Double arytenoid)**



**Figure 6. Comparison of nasogastric removal time between post-operative radiotherapy group to non-radiotherapy group. (1- Non-radiotherapy group, 2- Radiotherapy group)**



**Figure 5. Comparison of decannulation time between post-operative radiotherapy group to non-radiotherapy group. (1- Non-radiotherapy group, 2- Radiotherapy group)**

tube placement was relatively longer in the CHP/CHP with a single arytenoid group than double arytenoid preservation ( $50.3 \pm 14.3$  versus  $35.17 \pm 32.9$ ,  $p=0.088$ ) (Figure 5).

NGT removal time was  $53.29 \pm 50.2$  in the post-operative radiotherapy group and  $30.24 \pm 16.8$  in patients who did not receive post-operative RT ( $p=0.040$ ) (Figure 6).

Of the patients who were operated on, 14 were in the early stage (I-II) and 29 were in the late stage (III-IV).

The mean follow-up period was 62.9 months; 9 patients died during this period. Of these, 3 died due to lung carcinoma, 2 due to myocardial infarction, 3 due to locoregional recurrence, and 1 due to distant organ metastasis.

**DISCUSSION**

The treatment of laryngeal cancer aims to increase survival while maintaining quality of life as much as possible. While total laryngectomy offers the best results in terms of oncological safety, there are aspects that negatively affect the quality of life such as the presence of permanent tracheotomy and loss of voice. Therefore, it is important to apply larynx-sparing procedures in locally advanced cases (10, 12, 13). Radiation therapy alone, concomitant chemoradiotherapy, transoral laser surgery, and supracricoid laryngectomy are generally used in the treatment of early and selected locally-advanced laryngeal cancers with the advantage of preserving laryngeal function (14-17). Appropriate patient selection seems to be the most important factor for the technique to have good oncological and functional results. The functional capacity of the patient and the lesion should be examined in detail.

SCPL is one of the organ-preserving treatment options commonly used in the treatment of glottic and supraglottic laryngeal cancer. It has been shown to have reliable oncological results in many studies in the literature (18-21). In the literature, the 5-year local control rates vary between 71% and 95.7%. Five-year overall survival is 65%-95% (19, 21-30). Larynx preservation rate after SCPL is approximately 85%, and TL is applied in approximately 10% of patients for functional or oncological reasons (24, 26). In the follow-up of the patients in the study, TL operation was not needed in any of the patients. However, 3 patients died due to lung carcinoma, 2 patients due to myocardial infarction, 3 patients due to locoregional recurrence, and 1 patient due to distant organ metastasis.

Wang et al. found that in their series, the mean decannulation time was 41 days and the decannulation rate was 97.6%. Decannulation was achieved in nearly all patients, with the average time to decannulation being  $20 \pm 11.52$  days in CHP patients and  $28 \pm 8.92$  days in CHP (21). In the series of Pelini et al. the tracheostomy tube was removed in 75 (91%) of 82 patients between 6 and 180 days (mean 19.3 days) after surgery (30). In our series, all patients were decannulated, except for one patient who underwent CHP. The earliest postoperative decannulation time was 20 days and the latest was 140 days (mean 41 days).

NGT removal time varies between 15 and 70 days, according to the literature (17, 31-33). Wang et al. reported the mean nasogastric tube removal time as 18 days in CHEP patients and 25 days in CHP patients (21). Although this is compatible with the literature, the factors affecting NGT run time include the fact that the patients in our series are in the late stages of disease and that the frequency of postoperative RT is high.

Early or late complications can be seen in the follow-up after SCPL operation. In the early period, local complications such as abscess, wound infection, hematoma, bleeding, opening of pehial sutures and related laryngocutaneous fistula formation, respiratory complications due to bronchopulmonary infection, and laryngeal stenosis are seen. Pneumonia due to aspiration can be seen because of swallowing disorders. In the late period, stenosis and airway problems may occur due to laryngeal membrane, residual false cord or arytenoid edema. In laryngeal membrane formation, laser resection is useful in opening the obstruction. Severe stenosis due to granulation tissue may be seen in some patients. Other late complications are subglottic stenosis due to tracheostomy and anterior synechia due to pehial opening (34). One patient in our series had diffuse subcutaneous emphysema in the early postoperative period and was treated. No late complications were observed in any of the patients.

In conclusion, this study comprehensively analyzed 43 glottic and supraglottic laryngeal carcinoma patients and demonstrated that patients treated with CHEP and CHP had satisfactory oncological outcomes, and laryngeal function was preserved by rebuilding the neolarynx. Laryngeal carcinoma should be treated with the intent of organ-sparing, and our reliable data indicate that the SCPL can serve as a standard procedure for adequate tumor resection and function preservation for selected patients with T1-T4 glottic and supraglottic carcinomas.

**Ethics Committee Approval:** This research was conducted according to the Declaration of Helsinki for Biomedical Research Involving Human Subjects (WMA; 1997) and was approved by the ethics committee of Istinye University Hospital (2017-KAEK-120)/ 2/2021.G-70).

**Informed Consent:** All participants gave written consent after being informed about the procedures and purpose of the study.

**Peer-Review:** Externally peer-reviewed.

**Author Contributions:** Conception/Design of Study- C.K., E.Y., İ.Y.; Data Acquisition- E.Y.; Data Analysis/Interpretation- C.K.; Drafting Manuscript- C.K., E.Y., İ.Y.; Critical Revision of Manuscript- İ.A.; Final Approval and Accountability- C.K., E.Y., İ.Y., İ.A.

**Conflict of Interest:** Authors declared no conflict of interest.

**Financial Disclosure:** Authors declared no financial support.

## REFERENCES

- Steuer CE, El-Deiry M, Parks JR, Higgins KA, Saba NF. An update on larynx cancer. *CA Cancer J Clin* 2017;67(1):31-50.
- American Cancer Society. Facts & Figures 2019: US Cancer Death Rate has Dropped 27% in 25 Years. *Am Cancer Soc* 2019;2019:2015-7.
- Ciolofan MS, Vlăescu AN, Mogoantă CA, Ioniță E, Ioniță I, Căpitănescu AN, et al. Clinical, Histological and Immunohistochemical Evaluation of Larynx Cancer. *Curr Health Sci J* 2017;43(4):367-375.
- Gallo A, Manciooco V, Simonelli M, Pagliuca G, D'Arcangelo E, De Vincentis M. Supracricoid partial laryngectomy in the treatment of laryngeal cancer: univariate and multivariate analysis of prognostic factors. *Arch Otolaryngol Neck Surg* 2005;131(7):620-5.
- Lefebvre JL. Laryngeal preservation in head and neck cancer: multidisciplinary approach. *Lancet Oncol* 2006;7(9):747-55.
- Pfister DG, Laurie SA, Weinstein GS, Mendenhall WM, Adelstein DJ, Ang KK, et al. American Society of Clinical Oncology clinical practice guideline for the use of larynx-preservation strategies in the treatment of laryngeal cancer. *J Clin Oncol* 2006;24(22):3693-704.
- Weinstein GS, El-Sawy MM, Ruiz C, Dooley P, Chalian A, El-Sayed MM, et al. Laryngeal preservation with supracricoid partial laryngectomy results in improved quality of life when compared with total laryngectomy. *Laryngoscope* 2001;111(2):191-9.
- Schindler A, Favero E, Nudo S, Albera R, Schindler O, Cavalot AL. Long-term voice and swallowing modifications after supracricoid laryngectomy: objective, subjective, and self-assessment data. *Am J Otolaryngol* 2006;27(6):378-83.
- Gillespie MB, Brodsky MB, Day TA, Lee F, Martin-Harris B. Swallowing-related quality of life after head and neck cancer treatment. *Laryngoscope* 2004;114(8):1362-7.
- Majer H, Rieder W. Technique de laryngectomie permettant de conserver la permeabilite'respiratoire la cricohyoïdo-pexie. *Ann Otolaryngol Chir Cervicofac* 1959;76:677-83.
- Edge SB, Edge SB. *AJCC Cancer Staging Manual* 8th Ed. Springer; 2017.
- Nakayama M, Laccourreye O, Holsinger FC, Okamoto M, Hayakawa K. Functional organ preservation for laryngeal cancer: past, present and future. *Jpn J Clin Oncol* 2012;42(3):155-60.
- Pfister DG, Ang KK, Brizel DM, Burtness BA, Busse PM, Caudell JJ, et al. National Comprehensive Cancer Network. Head and neck cancers, version 2.2013. Featured updates to the NCCN guidelines. *J Natl Compr Canc Netw*. 2013;11(8):917-23. doi: 10.6004/jnccn.2013.0113. Erratum in: *J Natl Compr Canc Netw* 2013;11(12):1458.
- Caicedo-Granados E, Beswick DM, Christopoulos A, Cunningham DE, Razfar A, Ohr JP et al. Oncologic and functional outcomes of partial laryngeal surgery for intermediate-stage laryngeal cancer. *Otolaryngol Head Neck Surg* 2013;148(2):235-42.
- Forastiere AA, Goepfert H, Maor M, et al. Concurrent chemotherapy and radiotherapy for organ preservation in advanced laryngeal cancer. *N Engl J Med* 2003;349(22):2091-8.
- Department of Veterans Affairs Laryngeal Cancer Study Group. Induction Chemotherapy plus Radiation Compared with Surgery plus Radiation in Patients with Advanced Laryngeal Cancer. *N Engl J Med* 1991;324(24):1685-90.
- Ambrosch P. The role of laser microsurgery in the treatment of laryngeal cancer. *Curr Opin Otolaryngol Head Neck Surg* 2007;15(2):82-8.

18. Laccourreye H, Laccourreye O, Weinstein G, Menard M, Brasnu D. Supracricoid laryngectomy with cricothyroidopexy: a partial laryngeal procedure for selected supraglottic and transglottic carcinomas. *Laryngoscope* 1990;100(7):735-41.
19. Pinar E, Imre A, Calli C, Oncel S, Katilmis H. Supracricoid partial laryngectomy: analyses of oncologic and functional outcomes. *Otolaryngol Neck Surg* 2012;147(6):1093-8.
20. Wang PW, Abedini MR, Yang LX, Ding AA, Figeys D, Chang JY, et al. Gelsolin regulates cisplatin sensitivity in human head-and-neck cancer. *Int J Cancer* 2014;135(12):2760-9.
21. Wang Y, Li X, Pan Z. Analyses of functional and oncologic outcomes following supracricoid partial laryngectomy. *Eur Arch Oto-Rhino-Laryngology* 2015;272(11):3463-8.
22. Soudry E, Marmor Y, Hazan A, Marx S, Sadov R, Feinmesser R. Supracricoid partial laryngectomy: an alternative to total laryngectomy for locally advanced laryngeal cancers. *J Laryngol Otol* 2008;122(11):1219-23.
23. Enver N, Şahin A, Yumusakhuylu A, Sahin-Yilmaz A, Oysu C. Oncologic Results of Supracricoid Laryngectomy: Results From Two Tertiary Centers. *Acta Oncol Turc* 53(3):504-10.
24. Sánchez-Cuadrado I, Castro A, Bernáldez R, Del Palacio A, Gavilán J. Oncologic outcomes after supracricoid partial laryngectomy. *Otolaryngol Neck Surg* 2011;144(6):910-4.
25. Scola B, Fernández-Vega M, Martínez T, Fernández-Vega S, Ramirez C. Management of cancer of the supraglottis. *Otolaryngol Neck Surg* 2001;124(2):195-8.
26. Gonçalves AJ, Bertelli AAT, Malavasi TR, Kikuchi W, Rodrigues AN, Menezes MB. Results after supracricoid horizontal partial laryngectomy. *Auris Nasus Larynx* 2010;37(1):84-8.
27. Deganello A, Gallo O, De Cesare JM, Ninu MB, Gitti G, de' Campora L, et al. Supracricoid partial laryngectomy as salvage surgery for radiation therapy failure. *Head Neck* 2008;30(8):1064-71.
28. Lewin JS, Hutcheson KA, Barringer DA, May AH, Roberts DB, Holsinger FC, et al. Functional analysis of swallowing outcomes after supracricoid partial laryngectomy. *Head Neck* 2008;30(5):559-66.
29. Park J-O, Joo Y-H, Cho K-J, Kim N-G, Kim M-S. Functional and oncologic results of extended supracricoid partial laryngectomy. *Arch Otolaryngol Neck Surg* 2011;137(11):1124-9.
30. Pellini R, Manciooco V, Spriano G. Functional outcome of supracricoid partial laryngectomy with cricothyroidopexy: radiation failure vs previously untreated cases. *Arch Otolaryngol Neck Surg* 2006;132(11):1221-5.
31. Cho KJ, Joo YH, Sun D II, Kim MS. Supracricoid laryngectomy: oncologic validity and functional safety. *Eur Arch oto-rhino-laryngology* 2010;267(12):1919-25.
32. Szyfter W, Leszczyńska M, Wierzbicka M. Outcome after supracricoid laryngectomies in the material of ENT Department, Poznan University of Medical Sciences. *Eur Arch oto-rhino-laryngology* 2011;268(6):879-83.
33. Saito K, Araki K, Ogawa K, Shiotani A. Laryngeal function after supracricoid laryngectomy. *Otolaryngol Neck Surg* 2009;140(4):487-92.
34. Decotte A, Woisard V, Percodani J, Pessey J-J, Serrano E, Vergez S. Respiratory complications after supracricoid partial laryngectomy. *Eur Arch oto-rhino-laryngology* 2010;267(9):1415-21.