



Case Report

Rapidly growing pregnancy tumor

A. Pinar Sümer^a, N. Tuba Telcioğlu^b, Mahmut Sümer^b

^a Department of Oral Diagnosis and Radiology, Dentistry Faculty, Ondokuz Mayıs University, Samsun, Turkey

^b Department of Oral and Maxillofacial Surgery, Dentistry Faculty, Ondokuz Mayıs University, Samsun, Turkey

ARTICLE INFO

Article History

Received 03 / 03 / 2010

Accepted 01 / 04 / 2010

* Corresponding Author:

A. Pinar SUMER

Department of Oral Diagnosis and

Radiology, Dentistry Faculty,

Ondokuz Mayıs University,

Samsun, Turkey

e-mail: psumer1970@yahoo.com

ABSTRACT

Pregnancy tumor is a benign tumor-like growth that occurs in pregnant women. It usually appears on the anterior maxillary gingiva as a single pedunculated mass with a smooth surface and red color. The pregnancy tumor is histologically similar to a pyogenic granuloma but it is a distinct lesion on the basis of etiology, biologic behavior, and treatment protocol. In this report, a rapidly growing pregnancy tumor in a 27-year-old female in the third trimester of pregnancy was described. This case suggests that the pregnant women with a history of pregnancy tumor require special attention for possible enlargement of this lesion.

J. Exp. Clin. Med., 2009; 26:139-141

Key Words :

Pregnancy Tumor

Pyogenic Granuloma

Pregnancy

Granuloma Gravidarum

Gingival Overgrowth

Oral Cavity

© 2009 OMU All rights reserved

1. Introduction

Pregnancy tumor is a benign tumor-like growth that occurs in pregnant women. It usually appears as a red or reddish purple lesion on the anterior maxillary gingiva that bleeds easily (Daley et al., 1991; Steelman and Holmes, 1992). It is typically single but may be multiple, and may grow rapidly (Daley et al., 1991). The pregnancy tumor usually occurs during the second or third month of pregnancy (Macleod and Soames, 1987), but might also appear later in the pregnancy (Stelman and Holmes, 1992).

The pregnancy tumor is clinically and histopathologically identical to pyogenic granuloma (Laskaris, 2003). It is usually located on the gingiva in pregnant women related to increased hormone levels and an exaggerated inflammatory response of the gingiva to local factors (Stelman and Holmes, 1992; Laskaris, 2003).

The pregnancy tumor can resolve spontaneously

after parturition. Surgical excision preferably postpartum if the granuloma persists. During pregnancy, it can be removed under local anesthesia if it causes discomfort (Daley et al., 1991; Laskaris, 2003).

This report presents a case of a rapidly growing pregnancy tumor in a 27-year-old female in the third trimester of pregnancy.

2. Case report

A 27-year-old female in the 8th month of pregnancy referred to our clinic with a swelling on the left anterior mandible. The patient's medical and family history was noncontributory. Extraoral examination revealed no abnormalities. Intraoral examination revealed a gingival enlargement on the lingual aspect of the mandibular left side, between the left lateral incisor and the first premolar (Fig. 1). Clinically, no dental caries, plaque or calculus was observed. The lesion is painless and the patient has

no complaint during speech and mastication. The lesion was clinically diagnosed as a pregnancy tumor. As it did not pose any significant clinical problems and was

asymptomatic, no surgical removal of the lesion was performed. The patient was informed about the lesion and called for control after parturition.

17 days after the first examination, the patient presented with a large reddish purple mass on the lingual side of the mandible included the floor of the mouth (Fig. 2). The lesion was interfered her speech and mastication. On intraoral examination, it was observed that the pregnancy tumor enlarged rapidly, and decided to remove it surgically. A complete surgical excision was then carried out. Histopathologic examination confirmed our clinical diagnosis, showing edematous, highly vascular granulation tissue (Fig. 3). Healing occurred uneventfully and no recurrence was observed.

3. Discussion

Clinically, the pregnancy tumor appears as a single pedunculated mass with a smooth surface and red color (Laskaris, 2003). It is histologically similar to a pyogenic granuloma but it is a distinct lesion on the basis of etiology, biologic behavior, and treatment protocol (Daley et al., 1991; Cawson and Odell, 2002). During pregnancy estrogen and progesterone levels rise, which create an enhanced tissue response to chronic low-grade irritation (plaque, calculus, irregular dental restorations) in the oral cavity (Tervahartiala and Ainamo, 1989; Steelman and Holmes, 1992). There is a case report of the resolution of a pregnancy tumor in a 16 year-old woman (Stelman and Holmes, 1992). The patient was given a thorough dental prophylaxis and oral hygiene instructions and the tumor had resolved fourth week after parturition. Therefore, maintenance of oral hygiene and regular follow-up appointments should be recommended for pregnant women to prevent or lessen the severity of oral complications associated with pregnancy (Stelman and Holmes, 1992). In the present case, although the patient already had good oral hygiene, the pregnancy tumor was enlarged rapidly and became a very large mass that included the floor of the mouth.

A case of two pregnancy tumors in the same individual during two consecutive pregnancies was described by Oettinger-Barak et al., (2006). In that case despite preventive periodontal treatment the lesion continued to grow, similar to the present case.

In most cases, the pregnancy tumor resolves spontaneously after parturition, and therefore asymptomatic lesions should not be excised during pregnancy. If the lesion causes significant functional or esthetic problems, surgical removal should be considered (Daley et al., 1991). However, without removal of the inciting trauma, the lesion may recur (MacLeod and Soames, 1987; Daley et al., 1991). In the present case, the pregnancy tumor was removed surgically during the second visit of the patient.

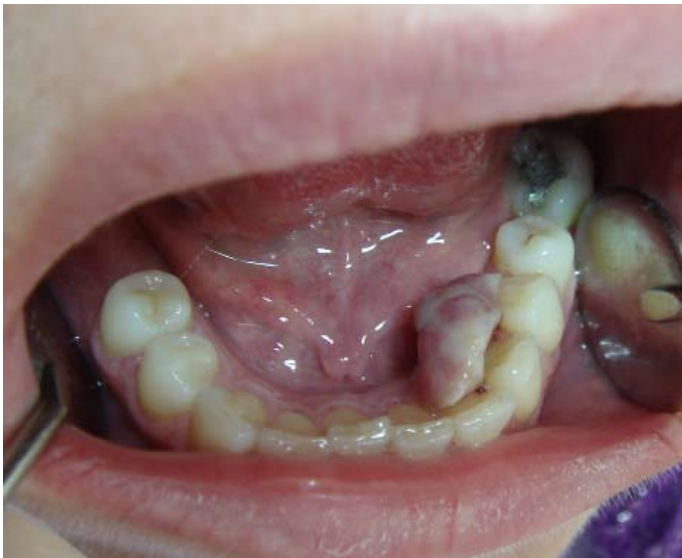

Fig. 1: At initial presentation, a gingival enlargement at the mandibular left side

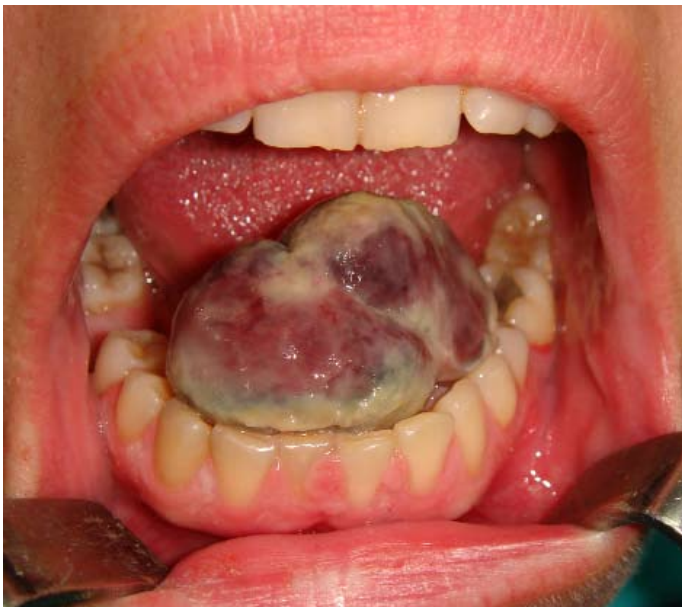

Fig. 2: 17 days after the first examination, a large mass on the lingual side of the mandible included the floor of the mouth

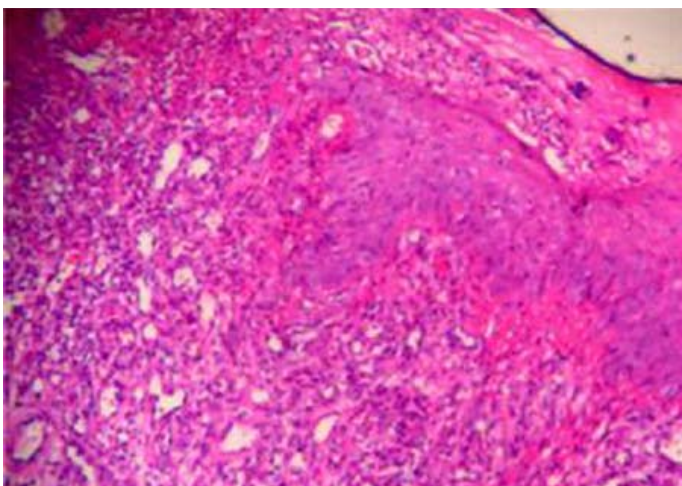


Fig. 3: Histologic section showing edematous, highly vascular granulation tissue

A rapidly growing pregnancy tumor in a 27-year-old female in the third trimester of pregnancy was described. This case suggests that the pregnant women with a history of pregnancy tumor require special attention for possible enlargement of this lesion.

REFERENCES

- Cawson, R.A., Odell, E.W., 2002. *Cawson's essentials of oral pathology and oral medicine*. 7th ed. Churchill Livingstone.
- Daley, T.D., Nartey, N.O., Wysocki, G.P., 1991. Pregnancy tumor: an analysis. *Oral Surg. Oral Med. Oral Pathol.* 72, 196-199.
- Laskaris, G., 2003. *Color atlas of oral diseases*. 3rd ed. Thieme Stuttgart New York.
- Macleod, R.I., Soames, J.V., 1987. Epulides: A clinicopathological study of a series of 200 consecutive lesions. *Br. Dent. J.* 163, 51-53.
- Oettinger-Barak, O., Machtei, E.E., Ofer, B.I., Barak, S., Peled, M., 2006. Pregnancy tumor occurring twice in the same individual: Report of a case and hormone receptors study. *Quintessence Int.* 37, 213-218.
- Steelman, R., Holmes, D., 1992. Pregnancy tumor in a 16-year-old: Case report and treatment considerations. *J. Clin. Pediatr Dent.* 16, 217-218.
- Tervahartiala, B., Ainamo, J., 1989. The development during pregnancy of pyogenic granulomas superimposed upon a congenital hemangioma: a case report. *J. Periodontol.* 6, 358-361.