



Case Report

Goltz syndrome (Focal Dermal Hypoplasia) with exuberant fat herniations, syndactyly, papillomas, skin defects, eye involvement and false positive anti HIV serology

Günseli Şefika Pancar, Nilgün Şentürk, Fatma Aydın, Levent Yıldız, M. Tayyar Cantürk, Ahmet Yaşar Turanlı

Departments of Dermatology and Pathology, Medical Faculty, Ondokuz Mayıs University, Samsun, Turkey

ARTICLE INFO

Article History

Received 27 / 10 / 2010

Accepted 24 / 11 / 2010

* Correspondence to:

Fatma Aydın

Department of Dermatology, Medical Faculty, Ondokuz Mayıs University, Kurupelit, Samsun, Turkey
e-mail: bennet@myynet.com

ABSTRACT

Goltz Syndrome (Focal Dermal Hypoplasia) is a rare congenital mesoectodermal dysplasia with multisystemic involvement. It was first described by Goltz in 1962 and more than 200 cases reported worldwide (Leite et al., 2005). Skin lesions are characterized by atrophic, hyperpigmented linear or reticulated macules, multiple mucocutaneous papillomas, fat herniations or fat tumors. Besides the skin, other structures frequently involved are the skeletal system, eyes, teeth, hair, nails and central nervous system (Kanitakis et al., 2003). The association between Goltz syndrome and anti-HIV serology was not found in the literature. We report 32 year-old woman with typical cutaneous lesions of Goltz Syndrome associated with false positive anti-HIV serology and secondary infertility.

J. Exp. Clin. Med., 2010; 27:123-125

Key Words :

Goltz Syndrome

Anti-HIV Serology

Genodermatose

Cutaneous Lesions

Secondary Infertility

Eye Involvement

© 2010 OMU All rights reserved

1. Case Report

A 32 year old woman was evaluated for facial dysmorphism, poikilodermic skin lesions, multiple verrucous and papillomatous lesions of the perivulvar region, short stature and kyphoscoliosis causing functional and esthetic discomfort.

In her history, she had one abortus in the past, since then she could not become pregnant and had been followed up because of the secondary infertility. She was the seventh child of the non relative parents. She has five sisters and a brother all of whom were healthy. She also had three sisters died of unknown aetiology when they were under age of five.

On physical examination she had sparse hair, recession of the frontal hair line and patchy areas of cicatricial alopecia with facial asymmetry. The right mandible was hypoplastic and the nasal bridge was narrow with a broad tip and unilateral notching of right ala nasi, she had low set ears and a triangular-shaped face due to the hypoplastic right orbital region, micrognathia and microdentia.

She had anophthalmia on the right side. Her right eye was enucleated at another hospital with an unknown

reason. The eyelids were irregularly shaped and could not be closed completely. Ophthalmologic examination of the left eye revealed choroid coloboma (Fig. 1).

Her teeth were hypoplastic, anodontic, irregularly spaced, inclined to decay and upper incisors were notched. Multiple milimetric papillomas on the gingiva were noticed. Examination of the lower extremity revealed partial syndactyly between the different toes of right and left feet.

Cutaneous examination showed multiple atrophic, pigmented linear streaks and poikiloderma on the trunk and extremities along the lines of blaschko and telangiectasias with atrophic depressions observed on the back of the patient (Fig. 2). Soft yellowish, lipomatous nodules projecting through localized areas of skin atrophy were noticed on shoulders -flanks and legs .

Histologic examination of the papillomatous inguinal lesion showed acanthosis and papillomatosis overlaid by thickened, partially parakeratotic stratum corneum. Also lipomatous nodule of the infrapatellar zone demonstrated a significant decrease in thickness of epidermis and the presence of adipose tissue in the mid-dermis where collagen fibers were less and thinner than

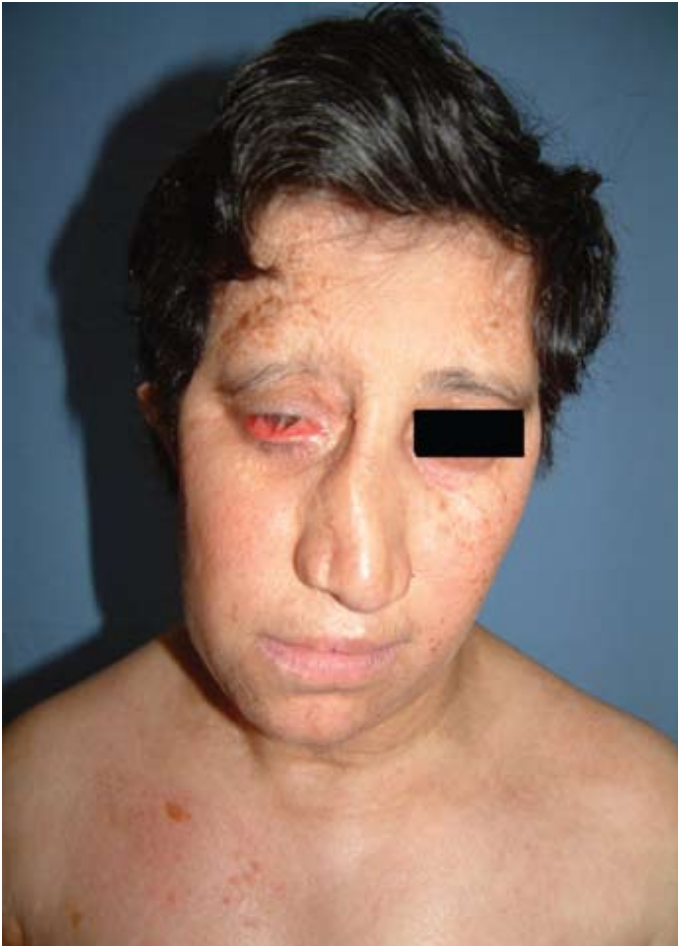

Fig. 1: Anophthalmia on the right side. Her right eye was enucleated. The eyelids were irregularly shaped. Ophthalmologic examination of the left eye revealed choroid coloboma

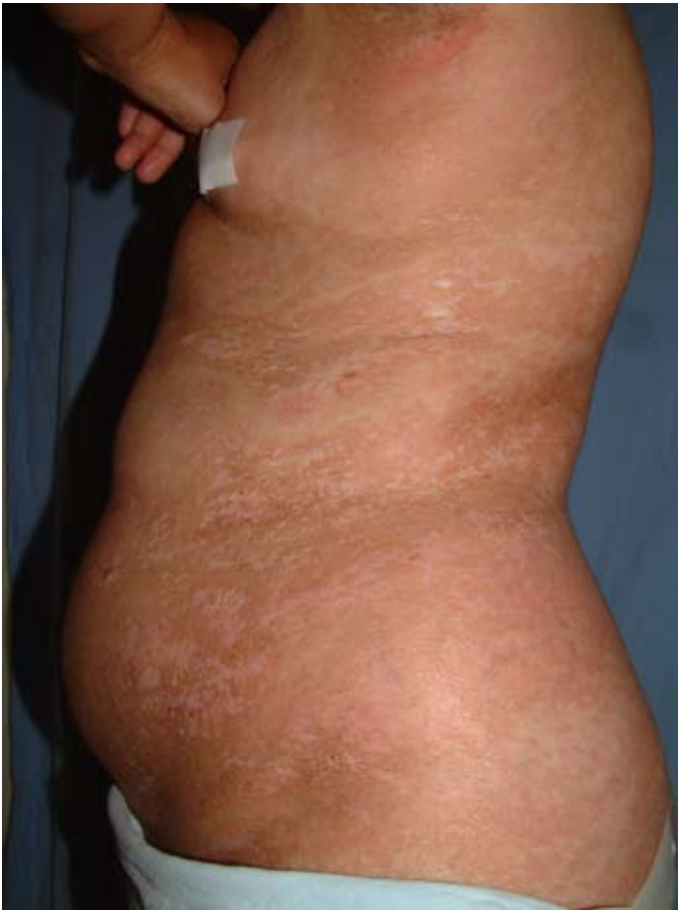

Fig. 2: Atrophic, pigmented linear streaks and poikiloderma on the trunk and extremities along the lines of blaschko and telangiectasias with atrophic depressions

the ones at the normal skin biopsies (Fig. 3). Repeated HIV serologies were positive but confirmation test with Western Blot was negative.

Radiologic examination revealed prominent osteoporosis. Pelvic ultrasound scan didn't reveal any abnormality. Histerosalphingography was chosen by ginecologists but the patient did not accept the process.

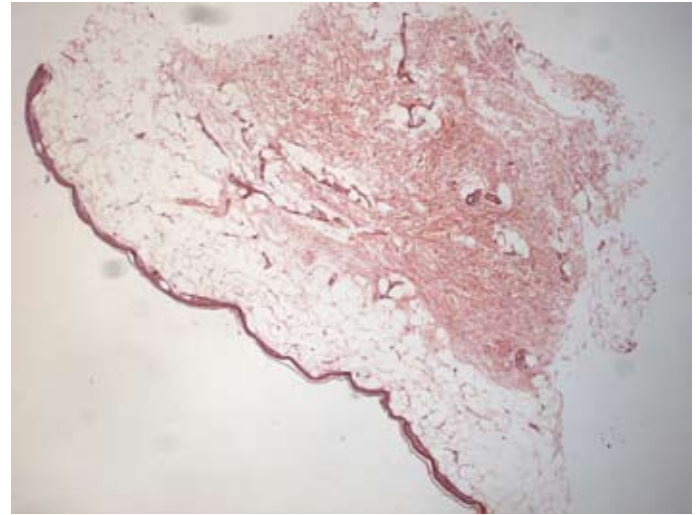


Fig. 3: Mature adipose tissue located in mid-dermis

2. Discussion

For the present case, presence of unaffected parents suggests sporadic mutations in X chromosome of one of the mother's germ line cells (Van Den Vayner, 2002).

The most common symptoms of Goltz syndrome are skin defects including linear atrophic hypo or hiperpigmented patches with telangiectasias following the lines of Blaschko and skeletal abnormalities.

The skin lesions contain soft yellowish nodules where subcutaneous fat is present within the dermis. These nodules were the herniation of adipose cells through dermal defects and nodules will become lipomatous tumors (Miranda et al., 2005). This finding has been referred to as "fat herniation" and reported in more than %50 of cases.

Histologic examination of biopsy specimens revealed thinned collagen bundles and occupation of dermis by adipose tissue. Thus, these pathogenic implications are believed to be the result of abnormal collagen synthesis of incompetent dermal fibroblasts. Buchener and Itin observed reduction of dermal collagen type IV, where as Lee et al found no evidence of such reduction.

Patients are also prone to the development of verrucous-appearing papillomas (lips, perianal area, vulvar region, oral mucosa, larynx and toes). Sixty percent of individuals have hypoplasia or aplasia of the digits, syndactyly, missing phalanges or typical claw-hand or claw-foot deformity.

Ten to fifteen percent of patients have osteopathia striata, which are longitudinal linear densities of the metaphysis of the long bones as well as scoliosis are sometimes seen. About 40% of patients have unilateral or bilateral microphthalmia or anophthalmia with vascular

defects, colobomas of the iris, retina and optic nerve and corneal opacities. These factors may be the cause of the removal of our patient's right eye.

Patients with Goltz Syndrome have characteristic facial dysmorphism; the face is asymmetric and triangular in shape. Patients also have sparse hair, with regions of alopecia and dental abnormalities.

False positive ELISA test results for HIV viruses can be caused by alloantibodies (transfusions, transplantation, pregnancy, autoimmune disorders, malignancies) and

infections of HTLV-1, HTLV-2, Leukemia, Lenti Viruses or Bovine Virus (Silverstein et al., 2004). Due to our patient's negative history, Goltz Syndrome may be another cause of false positive serology.

Being aware of clinical findings can be helpful when establishing the diagnosis of this rare syndrome, false positive serology and secondary infertility may be the part of this syndrome caused by unknown reasons.

REFERENCES

- Kanitakis, J., Souillet, A.L., Butnaru, C., et al. 2003. Melanocyte stimulation in Focal Dermal Hypoplasia with unusual pigmented skin lesions: A histologic and immunohistochemical study. *Pediatr. Dermatol.* 20, 249-253.
- Miranda, S.B., Delmaestro, D., Bertoli, R., et al. 2005. Focal Dermal Hypoplasia with exuberant fat herniations and skeletal deformities. *Pediatr. Dermatol.* 22, 420-423.
- Leite, J.C.L., Faermann, R., Stein, N.R., et al. 2005. Focal dermal hypoplasia associated with split sternum-Goltz syndrome. *Clin. Dysmorphol.* 14, 37-39.
- Silverstein, D.M., Aviles, D.H., Vehaskari, V.M. 2004. False-positive human immunodeficiency virus antibody test in a dialysis patient. *Pediatr. Nephrol.* 19, 547-549.
- Van den Veyver, I.B. 2002. Microphthalmia with linear skin defects (MLS), Aicardi, and Goltz syndromes: are they related X-linked dominant male-lethal disorders? *Cytogenet Genome Res.* 99, 289-296.