



A case of sacrococcygeal neuroblastoma

Fatih Suna^a, Tugce Bozkurter^b, Murat Elli^{*c}, Burak Tander^b, Ayhan Dağdemir^c, Meltem Ceyhan^d

^aDepartment of Pediatrics, School of Medicine, Ondokuz Mayıs University, Samsun, Turkey

^bDepartment of Pediatric Surgery, School of Medicine, Ondokuz Mayıs University, Samsun, Turkey

^cDepartment of Pediatric Oncology, School of Medicine, Ondokuz Mayıs University, Samsun, Turkey

^dDepartment of Radiology, School of Medicine, Ondokuz Mayıs University, Samsun, Turkey

ARTICLE INFO

ABSTRACT

Article History

Received 31 / 05 / 2012

Accepted 23 / 06 / 2012

Neuroblastoma is the most common extracranial solid tumor of childhood. Sacrococcygeal neuroblastomas are reported to be rare. The authors report a case of a well-differentiated neuroblastoma case, detected in a 4-month-old male during routine pediatric evaluation and totally resected by surgery.

J. Exp. Clin. Med., 2013; 30:75-77

* Correspondence to:

Murat Elli

Department of Pediatric Oncology,

School of Medicine,

Ondokuz Mayıs University,

Samsun, Turkey

e-mail: ellimurat@yahoo.com

Keywords:

Childhood

Neuroblastoma

Pelvic

Sacrococcygeal

Tumor

Teratoma

© 2013 OMU

1. Introduction

Neuroblastoma (NBL) is a tumor derived from the primitive neural crest cells and seen at the adrenal medulla and sympathetic ganglia. It is the most common extracranial solid tumor. The most common site of origin during infancy is the abdomen, especially the surrenal glands (Brodeur, 2006). Pelvic neuroblastomas are rather rare. Herein, we are presenting a 4-month-old male NBL case who was referred with a sacral mass.

2. Case report

During the routine pediatric evaluation of a 4-month-old male, an ecchymotic protuberance was noticed at the sacral region which was present since birth. The ecchymosis had regressed by the time but the protuberance did not. Physical examination revealed a 5x5 cm soft tissue mass on sacrum. The skin covering the lesion had blue-purple color change.

Findings of a neurologic examination and the other systems examinations were normal. In addition, laboratory studies revealed no hematologic abnormalities. Levels of tumor markers such as carcinoembryonic antigen and alphafetoprotein were normal.

Lumbosacral vertebral column MRI revealed a smooth, lobulated, 5x6x6 cm soft tissue mass, starting from the presacral compartment at the sacrococcygeal region, surrounding the coccyx, spreading from nearby the distal part of the coccyx and reaching forth the subcutaneous tissue, in close relation with the neural foramens at the coccygeal level, showing heterogenous contrast pattern (Fig.1a-c).

The preoperative diagnosis of the patient was teratoma. After being separated from the sacrococcygeal joint level, the lesion was totally excised all together with coccyx and the intrapelvic part. There appeared rosette formation on microscopic examination and the tumor cells were chromogranin

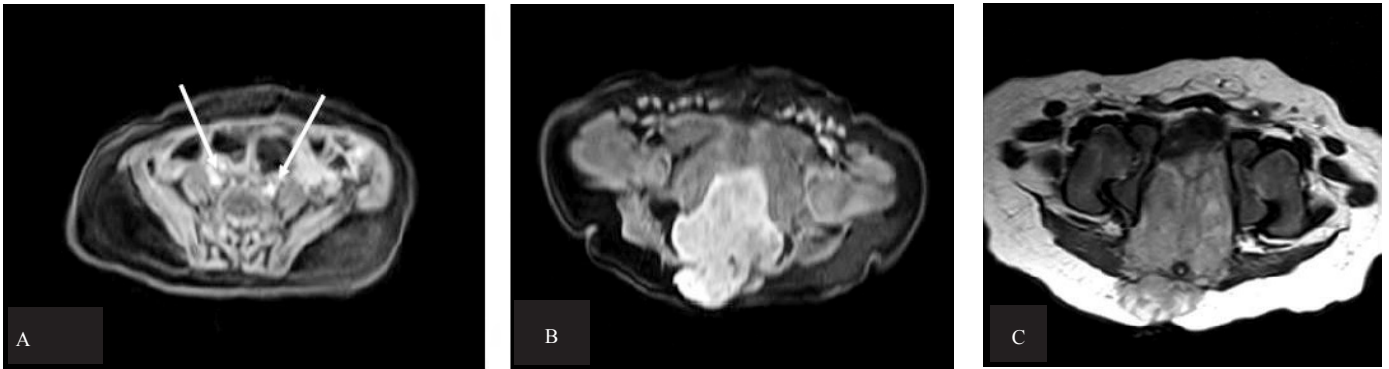

Fig. 1. A: The T1-weighted MR images show that the tumor does not exist at aortic bifurcation level (A) (White long arrows=right and left iliac arteries), starting from lower levels extending down to the coccyx (B) and having heterogeneous signal intensity. C: A 5x6x6 cm soft tissue mass, starting from the presacral compartment at the sacrococcygeal region, surrounding the coccyx, spreading from the pelvic cavity anteriorly and reaching the subcutaneous tissue anteriorly, displacing the urinary bladder and rectum on T2 weighted series.

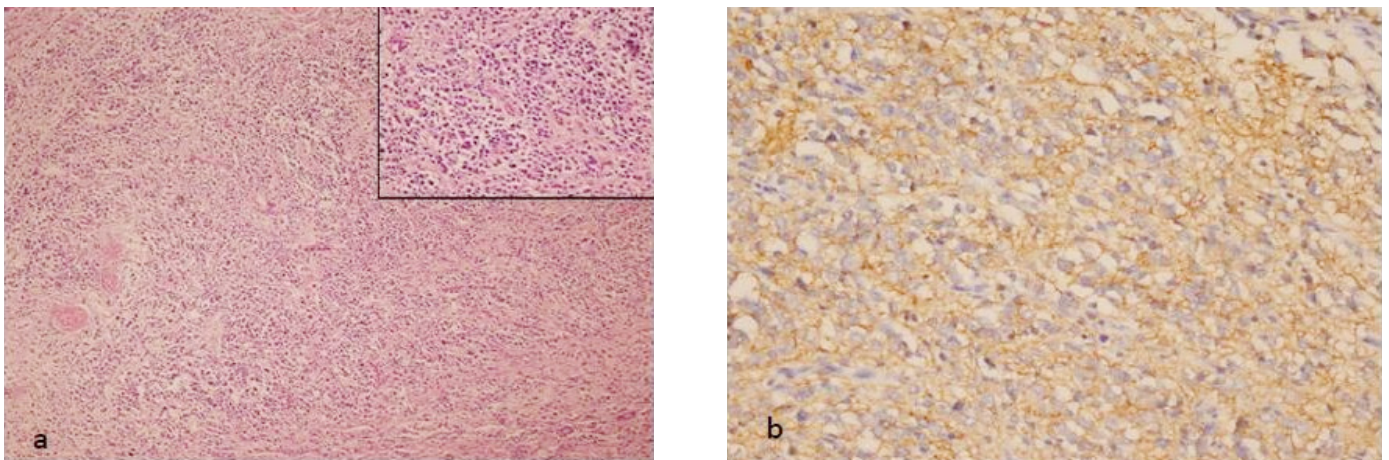


Fig. 2. a: The tumoral growth made up of small, atypical cells with hyperchromatic nuclei and eosinophilic cytoplasm, embedded within the fine fibrillar matrix (neurophil). (H&E, x100 ve x400); b: The synaptophysin positivity of the tumor cells on immunohistochemistry. (DAB, x400).

and synaptophysin positive on immunohistochemistry. So the tumor was interpreted as well-differentiated neuroblastoma (Fig. 2a, b). No n-myc amplification was detected on cytogenetic assay. Following the pathology report, the vanilmandelic acid (VMA) and homovanilic acid (HVA) levels were evaluated and found to be normal.

Being younger than 1-years of age, the tumor having well-differentiated type, tumor having no n-myc amplification and being removed totally were all good prognostic factors in our pelvic neuroblastoma case. The patient has not received any medicating for the last three years, he has no signs or symptoms of recurrence. He has shown the normal neuro-motor development appropriate to his age.

3. Discussion

Neuroblastoma accounts for approximately 7.5% of all childhood malignancies (Crucetti et al., 2000). Prevalance is 1 in every 7000 live birth. Neuroblastoma is commonly seen at 0-4 years and the mean age of diagnosis is 22 months. 36-40% of cases are younger than 1 year, whereas 89% is younger than five years and 98% is younger than ten years of age (Shusterman and George, 2006). The tumor is seen mostly in the first month of the life.

Neuroblastomas are tumors of the sympathetic chain or any sympathetic ganglia. Most primary tumors occur in the abdomen (65%), and half of the tumors occur in the adrenal gland. Other common places are thorax, neck and pelvis.

Pelvic sites of origin accounts for 2-6% of all solid NBs and the primary site of origin is unknown in 1% (Knoedler, 1989; Crucetti, 2000; Brodeur, 2006).

Neuroblastomas of the pelvis are calculated to account for 0.25% of all neonatal neoplasms (Crucetti, 2000; Massad, 1986). A few cases were reported in the literature. D'Alessio et al. (2006) reported a case of pelvic (presacral) cystic NBL in a 2-month-old boy. Tanaka et al. (2005) reported a case of neonatal neuroblastoma mimicking Altman type III sacrococcygeal teratoma. Watanabe et al. (2008) described a case of a 2-month-old girl with large presacral NB. And also Unal et al. (2010) reported a case of malignant transformation of an unresected sacrococcygeal teratoma to neuroblastoma in a 6-years-old girl. The symptoms of neuroblastoma arising from the sacral region may include abdominal distention and urinary retention. Our patient had no symptoms, the sacral mass was detected during routine pediatric evaluation.

The differential diagnosis should be defined clearly preoperatively especially for sacral cystic neuroblastomas. Teratomas, cystic lymphangiomas, meningomyeloceles and chordomas may arise from this region in infants. But today computed tomography and magnetic resonance imaging helps in diagnosis (Tanaka et al., 2005; D'Alessio et al., 2006; Watanabe et al., 2008).

Urine VMA and HVA levels are reported to be normal or slightly higher than normal in the literature diagnosis (Tanaka et al., 2005; D'Alessio et al., 2006; Watanabe et al., 2008). In

our case, following the pathology report, the VMA and HVA levels were evaluated and found to be normal. Preoperative studies were not performed because the preoperative diagnosis of the patient was teratoma.

The mortality rate of pelvic neuroblastomas is quite low even if the tumor is incompletely resected. Unfortunately morbidity related to the tumor bulk pressure and probable

postoperative neurologic deficits are rather high (35%) as well (Knoedler et al., 1989). Our patient has shown normal neuro-motor development appropriate to his age.

We suggest that neuroblastoma should be considered in the differential diagnosis of infantile sacrococcygeal tumors even if they are asymptomatic and urinary levels of VMA and HVA should be examined.

REFERENCES

- Brodeur, G.M., Maris, J.M., 2006. Neuroblastoma In: Pizzo, P.A., Poplack, D.G. eds. Principles and Practice of Pediatric Oncology 5th ed. Philadelphia: Lippincott-Roven. 233-970.
- Crucetti, A., Kiely, E.M., Spitz, L., Drake D.P., Pritchard, J., Pierro, A., 2000. Pelvic neuroblastoma: Low mortality and high morbidity. *J. Pediatr. Surg.* 35, 724-728.
- D'Alessio, A., Piro, E., Beretta, F., Abati, L., Brugnoli, M., Assi, A., Luksch, R., 2006. Presacral cystic neuroblastoma: Case Report and review of the literature. *J. Pediatr. Hematol. Onc.* 28, 534-536.
- Knoedler, C.J., Kay, R., Knoedler, J.P. Sr., Wiig, T.H., 1989. Pelvic neuroblastoma. *J. Urol.* 141, 905-907.
- Massad, M., Slim, M.S., Mansour, A., Dabbous, I., Firzli, S., Issa, P., 1986. Neuroblastoma: Report on a 21-year experience. *J. Pediatr. Surg.* 2, 388-391.
- Shusterman, S., George, R.E., 2009. Neuroblastoma. In: Orkin, S.H., Fisher, D.E., Look AT et al. eds. *Oncology of Infancy and Childhood*. 1st ed. Philadelphia: Saunders Elsevier. 509-540.
- Tanaka, K., Kanai, M., Yosizawa, J., Yamazaki, Y., 2005. A case of neonatal neuroblastoma mimicking Altman type III sacrococcygeal teratoma. *J. Pediatr. Surg.* 40, 578-580.
- Unal, E., Koksall, Y., Toy, H., Gunel, E., Acikgozoglul, S., 2010. Neuroblastoma arising from an unresected sacrococcygeal teratoma in a child. *J. Pediatr. Hematol. Onc.* 32, 233-235.
- Watanabe, M., Komuro, H., Kaneko, M., Hori, T., Tatekawa, Y., Kudo, Sa., Urita, Ya., Inoue, S., Minami, M., Sugano, M.A., 2008. Rare case of presacral cystic neuroblastoma in an infant *J. Pediatr. Surg.* 43, 1376-1379.