



Eosinophilic granuloma causing pathological fracture of the clavicle: A pediatric case report

Alper Çıraklı^{a*}, Birol Gülman^a, Sevgi Çıraklı^b, Ali Varlı^a, Serdar Ulusoy^a

^aDepartment of Orthopedics and Traumatology, Faculty of Medicine, Ondokuz Mayıs University, Samsun, Turkey

^bDepartment of Pediatrics, Faculty of Medicine, Ondokuz Mayıs University, Samsun, Turkey

ARTICLE INFO

ABSTRACT

Article History

Received 26 / 05 / 2013

Accepted 24 / 06 / 2013

* Correspondence to:

Alper Çıraklı

Department of Orthopedics and Traumatology, Faculty of Medicine,

Ondokuz Mayıs University,

Samsun, Turkey

e-mail: alperomu@gmail.com

Langerhans cell histiocytosis is a disease which has different localization and systemic types. Eosinophilic granuloma is a benign form with isolated bone involvement. Patients are generally aged below 10 years (range 5-20 years) and major complaint is progressive pain. Rarely, patients may present with a pathological fracture. The area of involvement is generally long flat bones. The prognosis is good and it may recover spontaneously. Treatment and monitoring of the patient remains controversial. The treatment choices are radiotherapy, chemotherapy and steroid injection with curettage and grafting. The case presented here is about a pediatric patient with a rarely seen pathological fracture of the clavicle and was treated with curettage and grafting.

J. Exp. Clin. Med., 2013; 30: 257-259

Keywords:

Child

Clavicle

Eosinophilic granuloma

Pathological fracture

© 2013 OMU

1. Introduction

Eosinophilic granuloma is a variant of langerhans cell histiocytosis with benign bone involvement (Alexiou et al., 2009). The disease is generally seen at male children whose ages are below 10 years old (Basmaci and Hasturk, 2011). Lesions are generally single and involve long blade bones (Verbist et al., 1998). It may cause pain and rarely pathological fractures. The treatment and monitoring of these lesions, which may recover spontaneously, is still controversial. The case is presented in this paper of rarely seen eosinophilic granuloma which caused a pathological fracture of the clavicle and was treated with curettage and grafting.

2. Case report

A 13-year old male presented in our clinic with complaints of pain in the left shoulder. The history revealed that the pain had been ongoing for approximately two months, severe pain and a clicking sound had developed while he was playing basketball.

In the physical examination of the patient there was

swelling in the left shoulder, pain during palpation and limited shoulder movements. The neuromotor and vascular examination of the left upper extremity was normal. There was nothing in the patient's medical history or familial history related to lesions.

In the radiological examinations of the patient, there was a lytic appearance on the direct radiograph due to expansion in the distal part of the left clavicle (Fig. 1). In the magnetic resonance imaging (MRI) and computerised tomography (CT) examinations, there was cortical bone destruction and periosteal reaction with peritumoural oedema in the soft tissue surrounding the mass which was thought to be malignancy (Figures 2, 3, 4, 5). No involvement was observed in other parts of the body from systemic scans made with thorax CT, brain MRI, bone survey and positron emission tomography (PET). Laboratory test results were within normal limits. For an evaluation of bone and soft tissue tumours as there was isolated involvement, a needle biopsy was taken for an initial diagnosis of Ewing Sarcoma. The pathology results reported langerhans cell histiocytosis so curettage and grafting was

applied to the patient (Fig. 6). Pathological examination of the curettage material confirmed langerhans cell histiocytosis. The patient is healthy now and he continues to his school with ongoing follow-up.

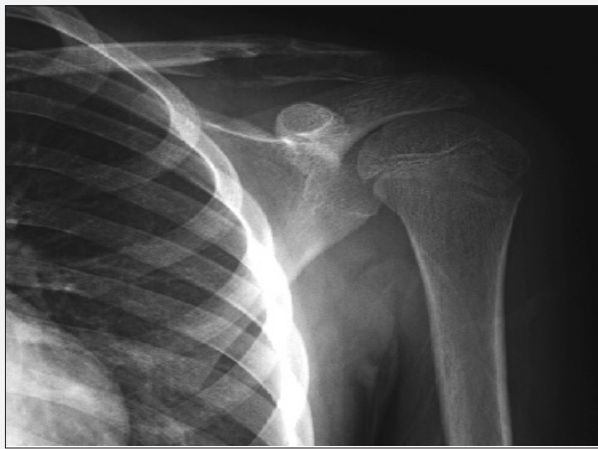

Fig. 1. Lytic lesion causing expansion in the distal clavicle

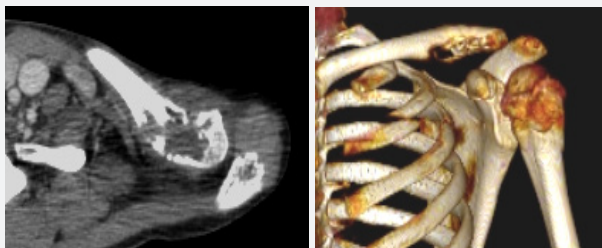

Fig. 2-3. Cortical destruction in the bone seen on axial slice CT and 3-dimensional CT

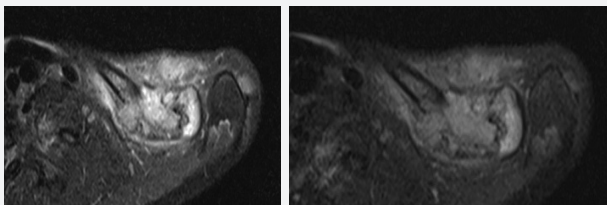


Fig. 4-5. Cortical destruction in the bone and the effect of peritumoral oedema on the surrounding soft tissue seen on axial slice MRI

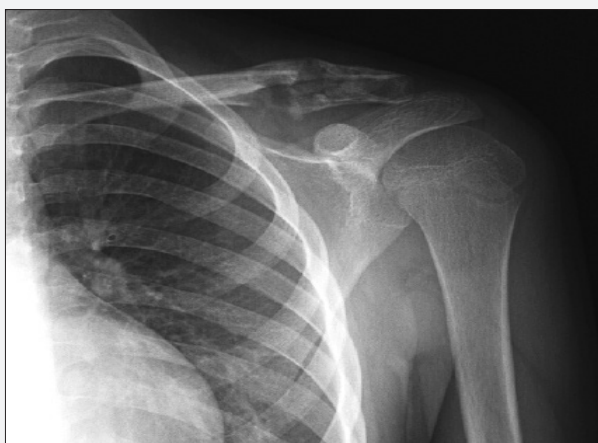

Fig. 6. Recovery can be seen to have started in the lesion area following grafting.

3. Discussion

Langerhans cell histiocytosis is a disease with three subgroups of eosinophilic granuloma, Hand-Schüller-Christian Disease and Letterer-Siwe Syndrome (Tural et al., 2004). The most commonly encountered (60%-80%) and benign form is eosinophilic granuloma. The other two subgroups are generally known as histiocytosis-X (Tural et al., 2004).

Eosinophilic granuloma is generally seen in males aged below 10 years (range 5-20 years) (Basmacı and Hastürk, 2011). The complaints are generally of progressive pain and rarely patients may present with a pathological fracture. There may be accompanying symptom of fever. Generally long blade bones are involved (skull, rib, iliac wing) (Verbist et al., 1998). Involvement of the vertebrae may be seen. Although it is generally seen in the form of a single focus, a rate of 28% multiple focus lesions may be seen in children (Albright et al., 1999). The case presented here was a 13-year old male with isolated clavicular involvement. Differentiates of this case that is developing pathological fracture, which is rarely seen.

Although the etiology has not yet been fully clarified, autoimmune diseases and inflammatory processes have been held responsible. An impairment which develops in the regulation of the immune system has been thought to cause lesions (Albright et al., 1999). In the case presented here, there was no pathology which led to the lesion.

In radiographic examinations, irregular destruction with expansion in the bone, periosteal reaction, lobular contours and oedema in the surrounding soft tissue may be seen. But these findings may be seen in malign tumours and they are not specific to eosinophilic granuloma (Smith et al., 1988). In this respect, as for other tumours, an accurate diagnosis is made by biopsy. In the case presented here, as the radiological findings were oriented towards malignancy, a biopsy was made with an initial diagnosis of Ewing Sarcoma to establish an accurate diagnosis. The lesion forms from a destructive accumulation of histiocytes in the medullar layer of the bone (Tural et al., 2004). In the pathology, the appearance of langerhans cells is pathognomonic. In addition, eosionophils, lymphocytes, fibroblasts and foam cells may be found but these are not pathognomonic (Basmacı and Hastürk, 2011). In the pathological examination of the case presented here, the lesion was observed to be formed from langerhans cells.

The prognosis is good and there may even be spontaneous recovery. Therefore, the treatment and monitoring of the disease are still controversial. The treatment choices are radiotherapy, chemotherapy and steroid injection with curettage and grafting. In this case curettage and grafting were applied both to confirm diagnosis and to accelerate recovery. As there was no systemic or multiple involvement, radiotherapy and chemotherapy were not administered.

Eosinophilic granuloma should be diagnosed quickly as it can be confused with malign lesions such as ewing sarcoma or osteomyelitis. Therefore, although it can spontaneously recover, in respect of confirming diagnosis, eradicating pain and accelerating recovery, curettage and grafting can be considered for useful treatment.

REFERENCES

- Albright, A.L., Pollack, I.F., Adelson, P.D., 1999. Principles and practice of pediatric neurosurgery. Thieme, New York-Stuttgart. 453.
- Alexiou, G.A., Mpairamidis, E., Sfakianos, G., Prodromou, N., 2009. Cranial unifocal langerhans cell histiocytosis in children. *J. Pediatr. Surg.* 44, 571-574.
- Basmacı, M., Hastürk, A.S., 2011. Eozinofilik granüloma: Radyolojik ve klinik değerlendirme. *Türk Nöroşirürji Dergisi.* 21, 262-264.
- Smith, J., Yuppa, F., Watson, R.C., 1988. Primary tumors and tumor-like lesion of the clavicle. *Skeletal Radiol.* 17, 235.
- Tural, S., Karasu, A., Ofloğlu, O., Bayındır, Ç., Toplamaoğlu, H., 2004. Oksipital kemikte eozinofilik granülom: Olgu sunumu. *Düşünen adam.* 17, 59-61.
- Verbist, B., Geusens, E., Brys, P., Verslegers, I., Samson, I., Sciot, R., Baert, A.L., 1998. Langerhans cell histiocytosis of the clavicle: A case report. *Eur. Radiol.* 8, 1357-1358.