



Valproic acid- induced early diagnosed encephalopathy

Recep Demir*, Lütfi Özel, İdris Kocatürk, Gökhan Özdemir, Hızır Ulvi

Department of Neurology, Faculty of Medicine, Ataturk University, Erzurum, Turkey

ARTICLE INFO

ABSTRACT

Article History

Received 19 / 09 / 2013

Accepted 25 / 10 / 2013

* Correspondence to:

Recep Demir
Department of Neurology,
Faculty of Medicine, Ataturk University,
Erzurum, Turkey
E-mail: demirmoro@gmail.com

Valproic acid-induced encephalopathy is a rarely seen but serious complication that may lead to death. It can be completely treated if early diagnosis is made and valproic acid (VPA) is discontinued. It is clinically presented as consciousness changes that range from sleepiness to lethargy and coma, focal or bilateral neurological findings, seizure, vomiting, and slow waves on electroencephalography (EEG). An 18 year old female patient presented to our polyclinic for the follow up of epilepsy. Her neurological examination was normal. The patient complained of headache. EEG showed disordered background activity at both hemispheres with symmetric delta activity at a frequency of 3-4 Hz, along with sharp paroxysms lasting 1-2 seconds. After discontinuation of the drug, EEG video monitoring showed a decrease in the sharp paroxysms the day after the drug. On the fourth day, the EEG returned to normal. We conclude that encephalopathy can be early diagnosed with EEG in VPA users.

J. Exp. Clin. Med., 2013; 30:385-387

Keywords:

Electroencephalography
Encephalopathy
Epilepsy
Valproic acid

© 2013 OMU

1. Introduction

Valproic acid (VPA) is an antiepileptic drug used for the treatment of generalized and partial seizures in adults and children. It can also be used to treat bipolar depression, psychoaffective disorders, neuropathic pain and migraines (Löscher, 1999). Valproic acid-induced encephalopathy (VAE) is a rare complication and can result in death if not diagnosed early (Kay et al., 1986). VAE can be accompanied by deterioration of consciousness, focal neurological findings, ataxia, cognitive slowness, vomiting and seizures. In electroencephalography (EEG), diffuse slowing and occasionally triphasic waves can be seen at the delta and theta frequency above irregular background activity. When VPA was discontinued, EEG changes and clinical findings returned to normal (Segura-Buruna et al., 2006).

We present a case without any neurological deficit whose EEG showed VAE with distinct diffuse slowness.

2. Case

An 18-year-old female patient presented to our polyclinic

for the follow up epilepsy. The patient complained of headache. She had experienced first seizure seven months after her birth. The patient's main complaint was absence seizures which occurred four or five times a day. She had also experienced generalized tonic-clonic convulsions with loss of consciousness only three times until now. The patient had been diagnosed as epilepsy two years ago and VPA 500 mg twice a day was prescribed. The family history was unremarkable. Fifteen days ago, the patient consulted her neurologist due to a new generalized tonic-clonic seizure. The doctor increased VPA dose to 750 mg per day. The patient had no complaints other than headache when she applied to our department ten days later. In the physical examination, she was conscious, oriented, and cooperative and her pupils were isochoric, with normal light and cornea reflexes. There was no pathological reflex in the whole body. Cranial magnetic resonance imaging of the patient was normal. In the laboratory examination, the hemogram, routine biochemistry, and ammonia level were in the normal range. The level of VPA in the blood was high as 130 µg/ml (normal laboratory values: 50-100 µg/ml). The

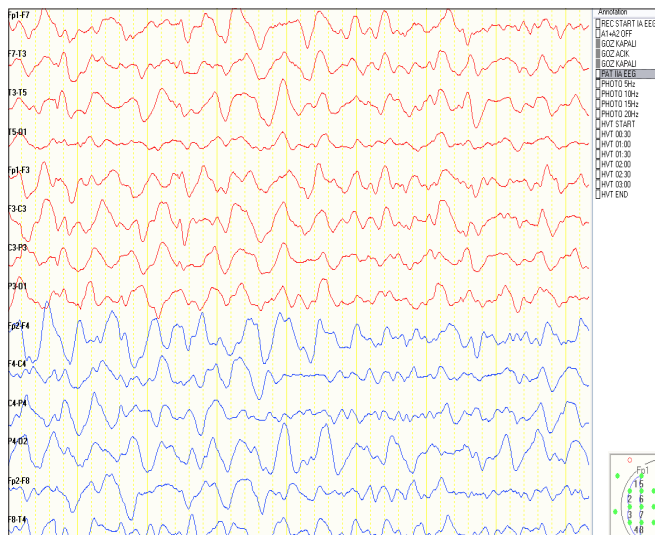


Fig. 1a. Diffuse slowing with delta and theta frequency

EEG showed that the background activity at both hemispheres was disordered. There was also symmetric delta activity at a frequency of 3- 4 Hz, along with sharp paroxysms which lasted 1-2 seconds (Fig. 1a). Diazepam-induced EEG showed no change (Fig. 1b). VAE was suspected, and the drug was discontinued. The patient was monitored with an EEG video on the same day. On the first day of drug cessation, the slow waves and sharp paroxysms on the EEG decreased. No convulsion occurred during hospitalization. On the fourth day, the EEG had returned to normal (Fig. 1c). As the patient experienced no more seizures, the patient was discharged with suggestions for follow up after two weeks. On the follow up, lamotrigine was initiated due to recurrence of absence seizures.

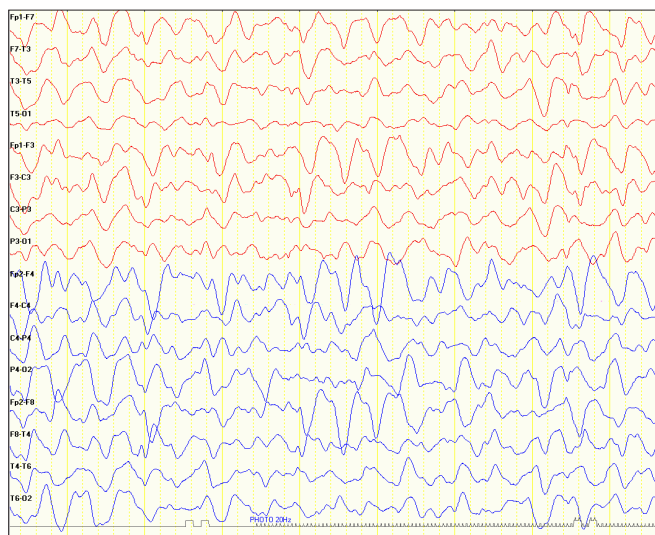


Fig. 1b. Diazepam-induced electroencephalography

3. Discussion

Our case is the first case diagnosed as VAE with EEG anomalies but without a neurologic deficit. Our patient was conscious and cooperative. Her neurological examination was normal. EEG was requested because the patient had experienced a seizure three days earlier. Following diffuse slowing of the EEG waves, laboratory parameters including complete blood count, biochemical analyses, arterial blood gas measurement and MRI were used to determine the potential presence of metabolic disorders, liver and kidney

impairment, or electrolyte imbalance. But there was no disturbance other than VAE to explain the pathological waves in EEG.

The early diagnosis of VAE is valuable to avoid deaths. Polat et al. previously presented three cases of VAE. They observed nausea, vomiting, deterioration of consciousness, slowness of the background rhythm on EEG, and an increase in the serum ammonia level in two of the cases. They reported that the liver enzyme levels and serum VPA levels were normal and that all the symptoms resolved after discontinuation of the drug (Polat et al., 2010). Another case series reported that patients diagnosed with VAE recover fully following the discontinuation of the drug (Hawkes et al., 2001). Clinically, VAE has been reported to be accompanied by changes in consciousness ranging from confusion to lethargy and coma, ataxy, vomiting, focal neurological deficits, low fever, and seizures. Increases in the VPA dose can also result in these symptoms (O'Neil et al., 2002). In VAE, seizure is an extreme sign which generally occurs with unconsciousness. In our patient, we think that the reason of generalized tonic-clonic convulsion was her routine disease, but headache may be due to VAE.

The pathophysiology of VAE has not been fully explained. Although hyperammonemia induced by impairment of the liver and kidney has been emphasized as the principal cause, the excessive number of cases with high serum ammonia levels being normal suggests that the basic mechanism might be linked to neurotransmitters (Sobaniec-Lotowska et al., 1996).

No relationship has been determined between the daily dose of VPA and VAE. Hence, serum VPA levels of those with VAE are within normal limits. Additionally, no relationship has been determined between the high serum ammonia levels and the clinical severity of the symptoms (Verotti et al., 2002). In our patient, the serum VPA level was high and the serum ammonia level was normal.

Symmetric delta and theta activity on EEG, rare frontal intermittent rhythmic delta activity and triphasic waves have been reported in patients with severe encephalopathy (Segura-Buruna et al., 2006). Ulker et al. found delta activity at the 2- 3 Hz frequency in an EEG of a patient with VAE (Ulker et al., 2004). Diffuse slowing on the EEG and occasional generalized triphasic waves were observed in a

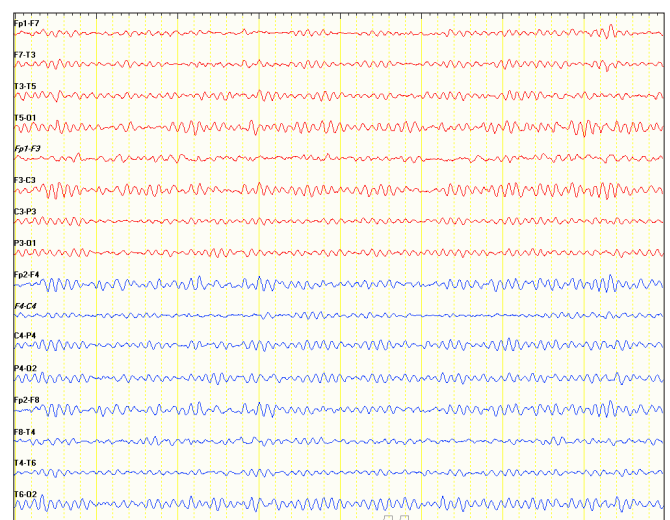


Fig. 1c. Normal electroencephalography signs on the fourth day

case report of VPE (McCall and Bourgeois, 2004). The EEG of our patient also displayed disordered background activity at both hemispheres, symmetric delta activity at the 3- 4 Hz frequency, and occasional sharp paroxysms which lasted 1- 2 seconds.

On the fourth day following the discontinuation of VPA, the

patient's, EEG returned normal. The patient was discharged, with suggestions for follow-up. We conclude that, in the early phase of VAE, clinicians can catch the patient with an EEG without any neurologic abnormality but just headache. Discontinuation of the drug may treat these patients before symptoms occur.

REFERENCES

- Hawkes, N.D., Thomas, G.A.O., Jurewich, A., Williams, O.M., Hillier, C.E., McQueen, I.N., Shortland, G., 2001. Nonhepatic hyperammonaemia: An important, potentially reversible cause of encephalopathy. *Postgrad. Med. J.* 77, 717-722.
- Kay, J.D., Hilton, Jhones, D., Hyman, N., 1986. Valproate toxicity and ornithine carbamoyltransferase deficiency. *Lancet.* 2, 1283-1284.
- Löscher, W., 1999. Valproate: A reappraisal of its pharmacodynamic properties and mechanisms of action. *Prog. Neurobiol.* 58, 31-59.
- McCall, M., Bourgeois, J.A., 2004. Valproic acid-induced hyperammonemia: A case report. *J. Clin. Psychopharmacol.* 24, 521-526.
- O'Neil, M., Dubrey, R.W., Grocott-Mason, R.M., 2002. Valproate encephalopathy and hyperammonaemia. *Postgrad. Med. J.* 78, 316-317.
- Polat, F., Koskderelioglu, A., Alpaydin, S., Keskingöz, N., Araç, N., Gönül, A.S., Kocaman, A., Şirin, H., 2010. Valproate-induced encephalopathy in three cases. *Turk J. Neurol.* 16, 203-207.
- Segura-Buruna, N., Rodriguez-Campello, A., Puente, V., Roquer, J., 2006. Valproate-induced hyperammonemic encephalopathy. *Acta Neurol. Scandinavica.* 114, 1-7.
- Sobaniec-Lotowska, M., Sobaniec, W., 1996. Morphological features of encephalopathy after chronic treatment of the antiepileptic drug valproate to rats. A transmission electron microscopic study of capilleries in the cerebellar cortex. *Exp. Toxicol. Pathol.* 48, 65-75.
- Ulker, M., Sari, H., Atakli, D., Arpacı, B., 2004. Valproic Acid-Associated Severe Encephalopathy in A Patient with low serum carnitine level and slight encephalopathy. *Epilepsy (Turkish).* 10, 169-172.
- Verotti, A., Trotta, D., Morgese, D., Chiarelli, F., 2002. Valproate-induced hyperammonemic encephalopathy. *Metab. Brain Dis.* 17, 367-373.