



Recovery of chronic central serous chorioretinopathy with a single dose of intravitreal ranibizumab injection: A case report

Emrah Kan^{a*}, Ozlem Eski Yucel^b

^a Department of Ophthalmology, Samsun Training and Research Hospital, Samsun, Turkey

^b Department of Ophthalmology, Faculty of Medicine, Ondokuz Mayıs University, Samsun, Turkey

ARTICLE INFO

ABSTRACT

Article History

Received 10 / 11 / 2014

Accepted 02 / 01 / 2015

* Correspondence to:

Emrah Kan

Department of Ophthalmology,
Samsun Training and Research Hospital,
Samsun, Turkey

e-mail: dremrahkan@yahoo.com

Central serous chorioretinopathy is an idiopathic condition characterized by the development of a serous detachment of the sensory retina especially in healthy men between 25 and 55 years of age. Observation of the patients at least for three months for spontaneous recovery in unilateral central serous chorioretinopathy is recommended. Conventional treatment modalities include laser photocoagulation and photodynamic therapy but these treatments can cause permanent damage to the retinal pigment epithelium or choriocapillary. Recently intravitreal anti-vascular endothelial growth factor agents have been used to ameliorate this condition but their results are controversial. Herein we present a successful treatment of a patient with chronic central serous chorioretinopathy with a single dose of intravitreal ranibizumab injection.

Keywords:

Central serous chorioretinopathy

Choroidal thickness

Photodynamic therapy

Ranibizumab

© 2015 OMU

1. Introduction

Central serous chorioretinopathy (CSCR) is an idiopathic condition characterized by the development of a serous detachment of the sensory retina due to the primary dysfunction at the level of the choroid and one or more focal lesions of retinal pigment epithelium (RPE). CSCR occurs primarily in healthy men between 25 and 55 years of age. Although most patients are asymptomatic, still once the central macula is affected the most common symptom appears as sudden onset of blurred vision. Corticosteroid use, personality types including type A personality, hypochondria, hysteria and conversional neurosis have been associated with CSCR. It can be classified as acute (symptoms and diagnostic

findings <6 months) and chronic (symptoms and diagnostic findings >6 months) (Hussain and Gass, 1998).

2. Case report

A 47 year-old woman admitted to our clinic with a complaint of sudden blurred vision in her left eye which had begun two days ago. Complete ophthalmologic examination including best corrected visual acuity (BCVA), slit lamp and fundus examination, fundus fluorescein angiography (FFA) and optical coherence tomography (OCT) were performed. Her anterior segment examination was normal. Her BCVA were 0.7 in both eyes. Intra ocular pressure (IOP) levels were 18 mmHg in the right eye and 17 mmHg in the left eye. Fundus

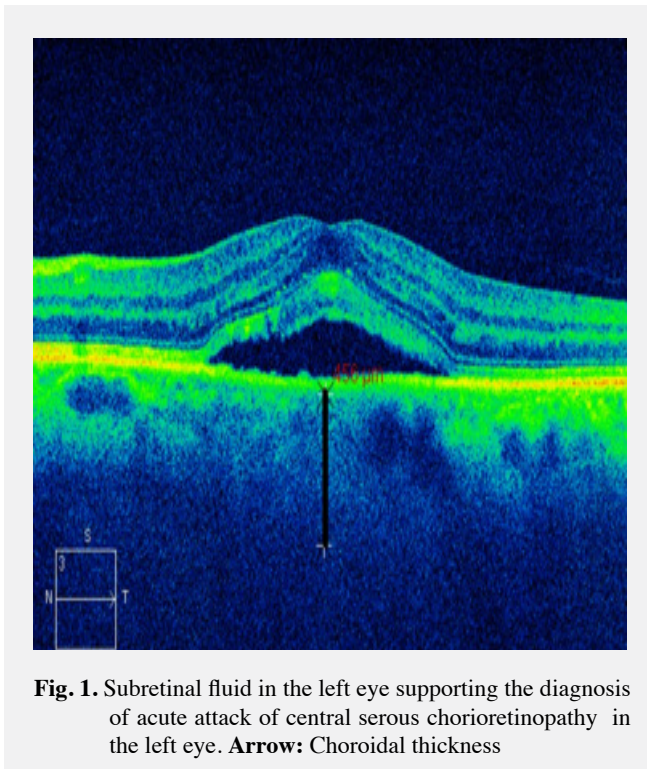


Fig. 1. Subretinal fluid in the left eye supporting the diagnosis of acute attack of central serous chorioretinopathy in the left eye. **Arrow:** Choroidal thickness

evaluation showed serous macular detachment of the left eye and old macular pigmentary changes in the right eye. The FFA examination showed a hyperfluorescence window defect lesion in the right eye and early macular dye leakage that increased in size of intensity as the angiogram progressed in the left eye, indicating acute attack. OCT revealed an irregularity in the right eye indicating a previous attack and a subretinal fluid in the left eye supporting the diagnosis of acute attack of CSCR (Fig. 1). In the enhanced depth imaging (EDI) mode of OCT choroidal thickness was measured 125 μm in the right eye and 456 μm in the left eye. The patient was diagnosed as an acute attack of CSCR in the left and taken to a follow-up. She did not have any systemic illness and had not been using any medications which might lead to CSCR. Three months after, BCVA in the left eye was 0.7. OCT showed sub-retinal fluid accumulation and FFA showed an irregular granular type hyperfluorescence in the left eye indicating the chronic phase of CSCR (Fig. 2). After informed consent was obtained from the patient, a single dose of intravitreal ranibizumab (IVR) injection was applied to the left eye for the diagnosis of chronic CSCR. One month after injection, in OCT, subretinal fluid disappeared and retinal layers flattened. Choroidal thickness measurement showed to a decrease 409 μm in the left eye (Fig. 3). BCVA improved to 1.0 in the left eye. The patient was subsequently re-assessed at 1, 3, 6 and 12 months intervals following injection. During the follow-up periods, neither a subretinal fluid nor a recurrence was observed.

3. Discussion

The mechanism for the development of CSCR remains unclear. According to one of the hypothesized mechanisms, abnormalities in choroidal perfusion can be causative factors in CSCR. Indocyanine green angiography in patients with CSCR has demonstrated evidence of choroidal lobular ischemia, choroidal venous congestion and also multiple areas of choroidal vascular hyperpermeability, suggesting

a more generalized RPE or choroidal vascular disturbance (Prunte and Flammer, 1996; Stanga et al., 2003). Furthermore, enhanced depth imaging, a new development of OCT, has proven that the choroid is thicker in patients suffering from CSCR compared with normal controls, supporting the original idea of a hyperpermeable choroid (Imamura et al., 2009).

Current treatment guidelines recommend that patients may be observed for at least three to four months for spontaneous recovery in unilateral CSCR. Although there is not a gold standard therapy defined yet, different treatment options are recommended. Conventional therapy procedures include laser photocoagulation (Robertson and Ilstrup, 1983) and PDT (Cardillo et al., 2003) but these treatments can cause permanent damage to the RPE or choriocapillary, retinal thermal injury, and subretinal choroidal neovascularization (Colucciello, 2006).

Vascular endothelial growth factor (VEGF) is produced by damaged retinal and choroidal cells and has dramatic effects on vascular permeability. Choroidal ischemia in CSCR may induce an increase in the concentration of VEGF. Lim et al. (2010) demonstrated that aqueous VEGF levels are increased in a portion of patients with chronic CSCR, but not in acute CSCR.

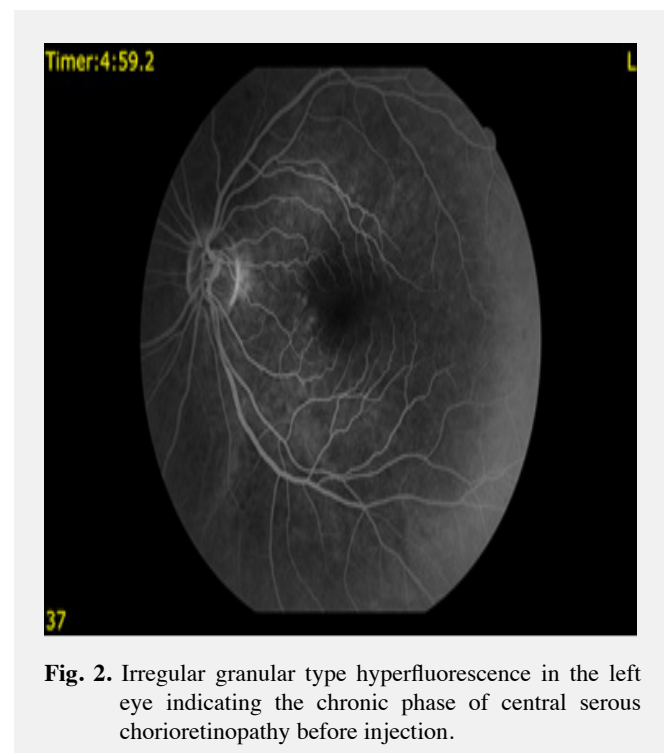


Fig. 2. Irregular granular type hyperfluorescence in the left eye indicating the chronic phase of central serous chorioretinopathy before injection.

Recently, intravitreal injections of anti-VEGF drugs have been presented as a safe and alternative therapy to avoid these side effects caused by conventional approach. The mechanism by which intravitreal anti-VEGF drugs ameliorates RPE leak and resorption of subretinal fluid in CSCR is unknown. Ranibizumab is a humanized anti-VEGF antibody that inhibits all forms of biologically active VEGF. Ranibizumab may be more effective than bevacizumab for treating CSCR because of its smaller molecular weight and possible deeper penetration into choroidal vascular hyperpermeability lesions in patients with CSCR (Lantry, 2007). In a retrospective study IVR injection was applied to CSCR patients who were resistant to intravitreal bevacizumab (IVB) injection.

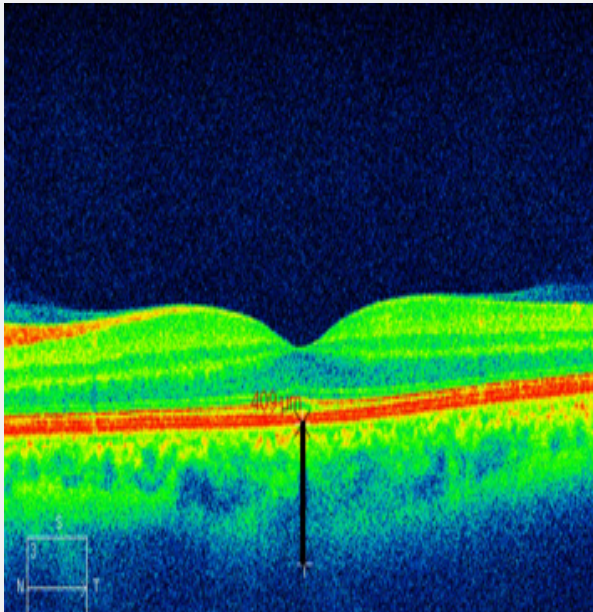


Fig. 3. One month after injection, subretinal fluid disappeared and retinal layers flattened. **Arrow:** Choroidal thickness

Subretinal fluid completely resolved and leakage disappeared in FFA in all cases after IVR injection, thus IVR injection was considered as an effective treatment in patients with CSCR who were resistant to bevacizumab in acute or early chronic stage (Altun et al., 2014). In a study the efficacy of IVB injection in chronic CSCR was evaluated in eight patients. The foveal thicknesses were $351.25 \pm 78.492 \mu\text{m}$ before and $183.50 \pm 22.640 \mu\text{m}$ one month after injection respectively. But in their study, they only evaluated the short term effects of bevacizumab (Gregori-Gisbert et al., 2011). Park et al. (2014) evaluated the efficacy of anti-VEGF drugs and compared the results with the observation group in acute CSCR. Of 36 patients with acute CSCR, 21 patients were treated with a single dose bevacizumab or ranibizumab and 15 patients were

observed (observation group). Resolution of subretinal fluid (SRF) was achieved in 20 of 21 eyes in the anti-VEGF group and in 12 of 15 eyes in the observation group. Mean BCVA and SRF did not differ between groups after 12 months. Foveal inner segments and outer segments (IS/OS) line were found statistically more damaged in the observation group than anti-VEGF group in the final OCT. They concluded that although BCVA and SRF did not show a difference between groups, anti-VEGF group had a favorable effect in terms of healthy IS/OS line (Park et al., 2014). In this study mean time was 1.2 months for the complete resolution of SRF in anti-VEGF group. In our case we observed the complete SRF resolution in the first month of anti-VEGF injection. The superior effects of intravitreal anti-VEGF agents compared to conventional therapies are controversial. In a study the efficacy and safety of low-fluence PDT was compared with IVR injection in chronic CSCR patients. Sixteen eyes with chronic CSRC were randomized to receive either low-fluence PDT or IVR injections. At three months, 75% of eyes in the low-fluence PDT group achieved complete resolution of subretinal fluid and reduction of choroidal hyperpermeability, whereas 25% of eyes in the ranibizumab group achieved this after consecutive ranibizumab injections. Four eyes (50%) in the ranibizumab group underwent additional low-fluence PDT and accomplished complete resolution. As a conclusion IVR injections did not offer promising results compared with that of low-fluence PDT in this study (Bae et al., 2011).

The superior side of our case, compared to previous studies that have been conducted so far, is that we have been successful to ameliorate a chronic CSCR and showed this with EDI-OCT. One enjection had been enough for the complete resolution of SRF caused by CSRS and the patient did not require any other therapy by the end of twelve months. Although controversial studies are present in the literature, we recommend IVR injection for chronic CSCR patients. Longitudinal and comparative studies with larger patients are necessary to emerge the ameliorating effect of IVR.

REFERENCES

- Altun, A., Kurna, S.A., Olcaysu, O.O., Sengor, T., Aki, S.F., Atakan, T.G., 2014. Success of ranibizumab in central serous chorioretinopathy resistant to bevacizumab. *J. Ocul. Pharmacol. Ther.* 30, 842-846. doi: 10.1089/jop.
- Bae, S.H., Heo, J.W., Kim, C., Kim, T.W., Lee, J.Y., Song, S.J., Park, T.K., Moon, S.W., Chung, H., 2011. A randomized pilot study of low fluence photodynamic therapy versus intravitreal ranibizumab for chronic central serous chorioretinopathy. *Am. J. Ophthalmol.* 152, 784-792. doi: 10.1016/j.ajo.2011.04.008
- Cardillo, F., Eandi, C.M., Ventre, L., Grignolo, F.M., 2003. Photodynamic therapy for chronic central serous chorioretinopathy. *Retina.* 23, 752-763.
- Colucciello, M., 2006. Choroidal neovascularization complicating photodynamic therapy for central serous retinopathy. *Retina.* 26, 239-242.
- Gregori-Gisbert, I., Aguirre-Balsalobre, F., García-Sánchez, J., León-Salvatierra, G., Mengual-Verdú, E., Hueso-Abancéns, J.R., 2011. Recurrent and chronic central serous chorioretinopathy. Retinal thickness evaluation one month after intravitreal bevacizumab injection. *Arch. Soc. Esp. Ophthalmol.* 86, 407-412.
- Hussain, D., Gass, J.D., 1998. Idiopathic central serous chorioretinopathy. *Indian J. Ophthalmol.* 46, 131-137.
- Imamura, Y., Fujiwara, T., Margolis, R., Spaide, R.F., 2009. Enhanced depth imaging optical coherence tomography of the choroid in central serous chorioretinopathy. *Retina.* 29, 1469-1473. doi: 10.1097/IAE.0b013e3181be0a83.
- Lantry, L.E., 2007. Ranibizumab, a mAb against VEGF-A for the potential treatment of age-related macular degeneration and other ocular complications. *Curr. Opin. Mol. Ther.* 9, 592-602.
- Lim, J.W., Kim, M.U., Shin, M.C., 2010. Aqueous humor and plasma levels of vascular endothelial growth factor and interleukin-8 in patients with central serous chorioretinopathy. *Retina.* 30, 1465-1471. doi: 10.1097/IAE.0b013e3181d8e7fe.
- Park, S.U., Lee, S.J., Kim, M., 2014. Intravitreal anti-vascular endothelial growth factor versus observation in acute central serous chorioretinopathy: One-year results. *Korean J. Ophthalmol.* 28, 306-313. doi: 10.3341/kjo.2014.28.4.306.
- Prunte, C., Flammer, J., 1996. Choroidal capillary and venous congestion in central serous chorioretinopathy. *Am. J. Ophthalmol.* 121, 26-34.
- Robertson, D.M., Ilstrup, D., 1983. Direct, indirect, and sham laser photocoagulation in the management of central serous chorioretinopathy. *Am. J. Ophthalmol.* 95, 57-66.

Stanga, P.E., Lim, J.I., Hamilton, P., 2003. Indocyanine green angiography in chorioretinal diseases: Indications and interpretation: An evidence-based update. *Ophthalmology*. 110, 15-21.