

Comparison of the use of graft augmented tubularized split (GATS) and tubularized incised plate urethroplasty (TIPU) techniques for hypospadias repair in patients with narrow plate and small glans

Ahsen Karagözü Akgül¹, Sadık Abidoğlu², Gürsu Kıyan³, Embiye Adalı⁴, Halil Tuğtepe⁵

¹ Ministry of Health, Marmara University Pendik Training and Research Hospital, Department of Pediatric Surgery, Division of Pediatric Urology, Istanbul, Turkey

² Marmara University, Faculty of Medicine, Department of Pediatric Surgery, Division of Pediatric Urology, Istanbul, Turkey

³ Marmara University, Faculty of Medicine, Department of Pediatric Surgery, Istanbul, Turkey

⁴ Marmara University, Faculty of Medicine, Department of Pediatric Surgery, and Ministry of Health, Istanbul Dr Lutfi Kırdar City Hospital, Department of Pediatrics, Istanbul, Turkey

⁵ Maltepe University, Department of Pediatric Surgery, Istanbul, Turkey

ORCID ID of the author(s)

AKA: 0000-0003-3250-605X
SA: 0000-0002-8654-8856
GK: 0000-0001-5461-353X
EA: 0000-0001-8206-8057
HT: 0000-0001-7465-2739

Corresponding Author

Ahsen Karagözü Akgül
Ministry of Health, Marmara University Pendik Training and Research Hospital, Department of Pediatric Urology, Fevzi Çakmak, Muhsin Yazıcıoğlu Cd No:10, 34899 Pendik/Istanbul, Turkey
E-mail: ahsenkaragozlu@yahoo.com

Ethics Committee Approval

The study has been approved by Marmara University Faculty of Medicine Clinical Research Ethics Committee on 04.12.2020 with protocol number 09.2020.1333.

Informed consent for both participation and publication was obtained from parents of the patients who included this study.

All procedures in this study involving human participants were performed in accordance with the 1964 Helsinki Declaration and its later amendments.

Conflict of Interest

No conflict of interest was declared by the authors.

Financial Disclosure

The authors declared that this study has received no financial support.

Published

2022 March 25

Copyright © 2022 The Author(s)

Published by JOSAM

This is an open access article distributed under the terms of the Creative Commons Attribution-NonCommercial-NoDerivatives License 4.0 (CC BY-NC-ND 4.0) where it is permissible to download, share, remix, transform, and buildup the work provided it is properly cited. The work cannot be used commercially without permission from the journal.



Abstract

Background/Aim: Hundreds of repair techniques were described for hypospadias repair. It is still a problem to choose the right technique in hypospadias repair for patients with narrow plate and small glans, because the patients with narrow urethral plate and small glans usually suffer from complications. GATS (Glans Augmented Tubularized Split) is an alternative technique with different details from grafted TIPU (Tubularized Incised Plate Urethroplasty). The aim of this study is to compare the outcomes of TIPU and GATS procedures on these difficult cases.

Methods: This retrospective cohort study consists of the analysis of patients who underwent GATS and TIPU procedures in our department between January 2017 and January 2020. Patients with distal and midpenile hypospadias and with shallow groove, glans smaller than 17 mm, and plate narrower than 8mm were included the study. Patient with follow-up shorter than 1 year or incomplete data and secondary cases were excluded. Patients were divided into two groups according to the technique performed, as 25 patients in TIPU group and 20 patients in GATS group.

Results: The mean diameter of glans were 15.3 mm and 14.5 mm, mean width of plate were 5.2 mm and 4.1 mm in TIPU and GATS groups respectively. Complications were observed in 7 (28%) patients of TIPU group and in 2 (10%) patients of GATS group ($P>0.05$). Urethral stenosis in one patient, urethral fistula in two patients, urethral dehiscence in two and urethral stenosis and diverticula in one patient, urethral stenosis and fistula in one patient were detected in TIPU group. Urethral fistula in one patient and urethral dehiscence in one patient were observed in GATS group.

Conclusion: GATS procedure is an alternative method for difficult cases with narrow urethral plate and small glans with less complications than TIPU technique.

Keywords: Hypospadias, Narrow urethral plate, Small glans, Shallow groove, Grafting, Complication

Introduction

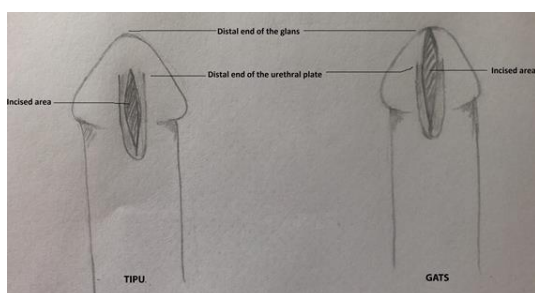
Hypospadias repair is one of the most common surgeries in pediatric urology. In this context, more than one hundred surgical techniques have been described in the literature for hypospadias repair, yet there is still no consensus on the technique that can serve as the gold standard technique.

Tubularized incised plate urethroplasty (TIPU) technique was first described by Snodgrass in 1994 [1] and has become the most commonly used technique for hypospadias repair since then. The rates of complications reported to have been associated with TIPU vary between 0% and 60% [2, 3]. The patients with narrow plate, small glans and shallow groove generally bear higher complication risks, and are thus commonly considered as difficult hypospadias cases [3, 4].

TIPU generally results in narrow neourethra in hypospadias cases with narrow plate, and subsequently in inelastic narrow urethra [5].

Surgeons attempted to solve the mentioned complications observed in hypospadias cases considered as difficult through the augmentation of the plate with graft [6]. Additionally, Snodgraft or inlay tubularized plate urethroplasty techniques were described and performed with less or similar complications [6-9]. In these techniques, plate is incised deeply, graft is applied inside the plate and tubularization is performed on a urethral stent. Grafts should be inlayed to increase the width of the plate, improve re-epithelialization, and prevent scar formation [10, 11]. In both of these techniques, the final meatus position is mostly glanular, yet not at the top of the glans, which is thus not an optimal position. On the other hand, in graft augmented tubularized split (GATS) [12] technique, plate and also glans are incised till the top of the glans deeply, and in this way the meatus is moved to the distal end of the glans (Figure 1). The defect is augmented with graft and the procedure is completed with tubularization of the neourethra. GATS technique provides a wider neourethral plate, a neomeatus that is positioned at the distal end of the glans, which is the optimum position, and also a slit-like meatus. Therefore, use of GATS procedure in hypospadias cases may lead to lower complication rates, although it is considered as a difficult procedure. But the debate in this issue for difficult cases with narrow and shallow plate and small glans still continues, whether TIPU is sufficient or a graft should be placed on the incised area. In our report, we compare the outcomes of the TIPU and GATS techniques in these difficult hypospadias cases with narrow plate, small glans and shallow groove and tried to determine whether the grafting of narrow urethra and deepen the shallow groove decreases the complications after GATS procedure.

Figure 1: Differences between the TIPU (on the left) and the GATS (on the right) techniques in terms of incised area



Materials and methods

The study has been conducted upon the required ethics committee approval has been obtained from the Marmara University Faculty of Medicine Clinical Research Ethics Committee on 04.12.2020 with protocol number 09.2020.1333. The clinical data of the patients with hypospadias, who underwent either TIPU or GATS procedures, between January 2017 and January 2020, in the clinic, where the study was conducted, were reviewed retrospectively. The clinical data of the patients, which were recorded to be analyzed within the scope of this study, included all penile anatomical details, i.e. diameter of the glans, width of the plate and length of penis in both stretched and normal positions, and classification of the groove of the glans as shallow (flat), mild (intermediate) or deep (like a cleft). Patients with distal and mid-penile hypospadias, shallow groove, glans diameter less than 17 mm, and plate width smaller than 8 mm, were included in the study; whereas patients, who were followed up clinically for less than 1 year as well as the patients, who require secondary surgery or were circumcised, were excluded from the study. Consequentially, a total of 45 patients were included in the study. These 45 patients were divided into two groups based on the hypospadias repair technique they underwent, as the TIPU group, which included 25 patients and as the GATS group, which included 20 patients.

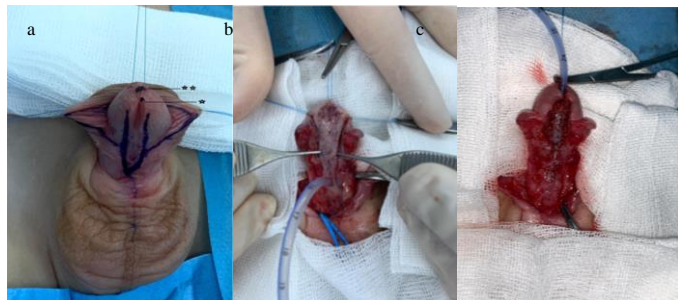
Patients' age at the time they underwent the surgery, diameter of glans, width of plate, the type of hypospadias and the complications they had, and their follow up times were compared.

Surgical procedure

All procedures were performed under general anesthesia and penile block was performed at the beginning of the procedure. Antibiotic prophylaxis was administered one hour prior the surgery. The procedures started with U incision around the hypospadiac meatus ending on both sides of the plate (Figure 2a). Degloving and dissection of the glanular wings were performed in case of both TIPU and GATS techniques. A deep midline incision that is limited to inside the urethral plate was performed in TIPU technique. A deep midline incision was also performed in GATS technique, yet the incision was extended distally to the top of the glans, that is, a few millimeter further to the point the urethral plate ends. In the GATS technique, the graft was harvested from the inner prepuce and placed in the incised plate and also in the incised area on the glans (Figure 2b). 7/0 PDS (polydioxanone suture) was used to fix the graft inner border of the plate. In addition, a few fixation sutures were placed between graft and base, in the midline in particular. Subsequently, the urethral plate was tubularized over 6 or 8 Fr (French) urethral catheter in two layers in both techniques; first layer with continuous subcuticular 7/0 Vicryl sutures and second layer with interrupted subcuticular 7/0 Vicryl sutures (Figure 2c). A pedicle flap from dartos fascia was prepared and placed on the neourethra as a cover. Glanuloplasty was performed with 6/0 PDS sutures. Urethral catheter was left in place for seven days postoperatively. Patients were followed up during the second week, first month and third month after the surgery. Thereafter, the follow up of patients were conducted by means of patient visits made to the outpatient clinic every 3 months until the end of the first year from the surgery, and annually thereafter. During

these follow visits, patients were evaluated for penile cosmetics, meatal and urethral stenosis, urethrocutaneous fistula by means of physical examination, and their neourethras were calibrated by means of 6-8 Fr catheter and video voiding device.

Figure 2: GATS procedure. 2a: U incision around the narrow urethral plate. *Distal end of the urethral plate. **Top of the glans. 2b: Grafting the incised area. 2c: Tubularization of the grafted neo-urethral plate.



Statistical analysis

SPSS 21.0 (IBM Statistical Package for Social Sciences version 21.0) software package was used to conduct the statistical analyses of the research data. Quantitative variables were expressed as numbers, mean or median values. Probability (P) values of <0.05 were deemed to indicate statistical significance. Mann-Whitney U test was used to compare information such as age, diameter of glans, width of plate and follow-up time, whereas Pearson’s Chi-squared test was used to compare the categorical variables between the groups.

Results

There was no statistically significant difference between the groups in terms of age, hypospadias type and glans diameter (P>0.05 for each) (Table 1). Additionally, all patients had shallow groove. The mean width of plate values were 5.2 mm and 4.15 mm in TIPU and GATS groups, respectively (P=0.045). The mean width of the plate in GATS group was narrower than the width in TIPU group. Complications were observed in 7 patients in the TIPU group, and in 2 patients in the GATS group (Table 1). Of the patients, who developed a complication in the TIPU group, two patients had urethral fistula, two patients had urethral dehiscence, one patient had urethral stenosis, one patient had urethral stenosis and diverticula, and one patient had urethral stenosis and fistula. On the other hand, of the patients, who developed a complication in the GATS group, one patient had urethral fistula and another patient had urethral dehiscence. The complication rates and severity of the cases were higher in TIPU group (28%) than in the GATS group (10%), albeit not statistically significantly (P=0.134). None of the patients had hormonal therapy or underwent plication for chordee. The median follow up times were 19 and 28.5 months in TIPU and GATS groups, respectively.

Table 1: Demographic and clinical characteristics of the patients included in the study

	TIPU Group	GATS Group	Total	P-value
Mean age (months) mean (SD) (min-max)	33.6 (20.2) (10-84)	34.35 (22.2) (6-81)	(6-84)	0.917*
Hypospadias type				0.651**
Distal	6	6	12	
Midpenile	19	14	33	
Mean width of the plate (mm) (min-max)	5.2 (3-8)	4.15 (2-8)		0.045***
Diameter of the glans (mm) (min-max)	15.32 (12-17)	14.55 (10-17)		0.141***
Number of patients with a complication	7 (28%)	2 (10%)	9 (20%)	0.134**
Median follow-up time (months)	19 (13-26)	28.5 (12-55)	19 (12-55)	0.108***

SD: Standard deviation, * t-test, **Pearson’s Chi-Squared test, *** Mann-Whitney U Test

Discussion

More than one hundred surgical techniques have been described in the literature for hypospadias repair in order to have better cosmetic and functional outcomes. Most common complications are urethrocutaneous fistula, meatal stenosis and the stricture of neourethra, dehiscence and diverticulum. These complications are seen more frequently in patients with narrow plate, shallow groove and small glans [4, 13]. Narrow urethral plate of less than 8 mm wide is associated with higher complication rates in the postoperative period. 40% of patients with shallow groove, 15% of patients with moderate groove, yet none with deep groove, develop narrow neourethra following the surgery [4]. It was reported in a prospective randomized study conducted by Sarhan et al. that urethral plate width affects the outcome of the surgery and that the plate width should be 8 mm or more for tubularization [14]. Accordingly, the major challenge is to repair the hypospadias in cases with narrow plate and shallow groove. In this context, only the patients with urethral plate width less than 8 mm, glans smaller than 17 mm, and shallow groove, were included in this study.

Tubularized incised plate urethroplasty (TIPU) technique is the most commonly used hypospadias repair technique both in the world and in the clinic, where this study was conducted. Braga et al. reported that the complication rates associated with TIPU ranged between 0% and 50%, with a median value of 7.3% [2]. This huge variation in the complication rates associated with TIPU can be attributed to the anatomy of the hypospadias and level of experience of the surgeon. Accordingly, only the patients, who were operated by the same experienced pediatric urologists, were included in this study. The main anatomic features of the hypospadiac penis that affect the surgical outcome are the location of the meatus, chordee, width of the plate, diameter of the glans, and depth of the groove. Tugtepe et al. [13] presented a scoring system to predict the complications that may arise following the hypospadias surgery. They demonstrated in the study they conducted with 394 patients who underwent TIPU that the complications were higher in those with narrow plate, shallow groove, chordee, and small glans [13, 15]. On the other hand, Bush and Snodgrass reported short term outcomes of TIPU in 224 cases, 80% of whom had narrow urethral plate (< 8 mm), and concluded that width of the urethral plate does not affect the outcome of TIPU [16]. Some authors suggest that the incision of the plate may provide enough width for tubularization of the urethra, and some surgeons suggest that the area without epithelle tissue may heal with scar tissue later and the caliber of the neourethra may reduce in long term. Leslie et al. performed an experimental animal study to assess the status of the urethra at 4 to 8 weeks-time following urethroplasty without incision, TIPU, or grafted TIPU [17]. The tubularized incised plate defect was bridged by urothelium, while the preputial graft in the incised plate kept its original histological characteristics. However, simple tubularization of the narrow urethra led to significant decrease in flow. TIPU and grafted TIPU resulted in similar urethral flow dynamics [17]. In another study conducted in 2000, Holland and Smith reported that the incision of the plate is similar to urethrotomy and that it heals with scar tissue instead of epithelization. They concluded that the depth of the urethral

groove and width of the plate affect the caliber of the neourethra, and that shallow groove and narrow plate were associated with narrow neourethra and urethrocutaneous fistula following TIPU [4].

TIPU vs grafted TIPU

In another study conducted in 2000, Kolon and Gonzales [7] described a new technique involving inner preputial free graft to augment urethral plate in TIPU. They reported to have performed the incision on the plate as described in the Snodgrass technique without extension from the end of the plate to the top of the glans and grafting the plate before tubularization. Consequentially, they reported a complication rate of 6% in 32 patients, also taking complications such as glans dehiscence and ventral skin breakdown into consideration, but they did not have any patient that had meatal stenosis, neourethral stricture, urethrocutaneous fistula or diverticulum, during the 21-month follow up period. Gundetti et al. [8] reported that they did not observe any meatal stenosis but only one recessed meatus associated with the use of grafted TIPU technique. In their prospective study, Silay et al. [9] reported to have performed the grafted TIPU procedure with a 9.8% urethrocutaneous fistula rate. Shuzhu [6], Eldeeb [10] and Helmy [11] et al. compared the outcomes of TIPU and grafted TIPU procedures, and did not find any significant difference between the two procedures. The authors of the aforementioned studies indicated that the graft was placed on the incised area, limited with the plate and not extended to the tip of the glans. To the contrary of the findings reported in those studies, Mouravas et al. [18] reported complication rates of 30.4% and 8.3% associated with the use of TIPU and grafted TIPU, respectively.

TIPU vs GATS

The meatal position of the neourethra following TIPU or grafted TIPU procedure is generally not located at the top of the glans. Instead, the end of the neourethra lies in glanular position in most cases due to the distal end of the urethral plate. GATS is a procedure performed with a very deep incision on the urethral plate that extends to the top of the glans and which provides a good deep groove and a wide plate. The graft is used to augment the neo-plate or neo-groove and neo-slit in the glans tip. In comparison, Ahmed and Alsaïd reported as a result of the study they conducted using a similar technique, that is, preputial inlay graft with TIPU procedure without a control group, that they have achieved excellent (96.09%) cosmetic and functional results regardless of the width and depth of plate or size of the glans, and that urethrocutaneous fistula was developed in only 3.91% of the patients [19]. Similarly, Asanuma reported a urethrocutaneous fistula rate of 3.6% in the study conducted in 2007 with 28 patients, who underwent dorsal inlay graft urethroplasty [20], whereas Nerli et al. [21] reported a urethrocutaneous fistula rate of 0% in the study they conducted with 12 patients with proximal hypospadias, who underwent dorsal inlay graft urethroplasty. Urethroplasty was performed using a technique similar to GATS in all these studies, in which no meatal or neo-urethral stenosis was observed and wide slit-like meatus was achieved at optimum position. However, the width of the urethral plate was not indicated in these studies, which constitutes a limitation of these studies, since no solution was suggested as to the choice of the most appropriate technique

for hypospadias repair in patients with narrow plate, shallow groove and small glans.

Making a direct comparison of the success and complication rates of the techniques used for hypospadias repair using the research data available in the literature is difficult, due to reasons such as varying patient selection criteria or patient selection bias and varying types of hypospadias in these researches. Despite the fact that the features of urethral plate are deemed to be an important risk factor affecting the outcomes of hypospadias repair techniques, the results of the studies conducted to assess the urethral plate are highly subjective [22]. In comparison, only patients with shallow groove, urethral plates less than 8 mm wide and glans diameter smaller than 17 mm, were included in this study. Consequentially, the complication rates were determined as 28% and 13% in the TIPU and GATS groups, respectively. Urethrocutaneous fistula was observed in 3 patients in the TIPU group and only in 1 patient in the GATS group. There was no case of meatal or urethral stenosis in the GATS group. Nevertheless, the difference between the groups in terms of complications was not found to be statistically significant. The complication rates found in this study may appear to be higher than those reported in the literature. However, this should not come as a surprise, since all the cases included in this study were cases that are considered as difficult hypospadias cases, contrary to the cases reported in the studies available in the literature, most of which neither mentioned width of the plate nor diameter of the glans.

We usually select the GATS technique for difficult cases with narrow plate, shallow groove and small glans. We did not compare all patients who underwent GATS with patients who underwent TIPU. To eliminate selection bias we compare the patients with similar difficulty by excluding patients with glans bigger than 17 mm, and plate wider than 8 mm and patients without shallow groove.

The mean follow up time reported in the literature for hypospadias cases is longer than 12 months in most studies [6, 7, 10, 19-21]. Even though a decrease is observed in the rate of complications by the 6th month after the surgery, there remains a risk up until the 12th month from the time of the surgery. Therefore, the patients with follow-up times longer than 12 months were included in this study. The median follow-up time of the patients included in this study was 20 months (min.12 and max. 55) months.

Limitation

There were some limitations of this study. First, it was carried out as a retrospective cohort study. Secondly, the study group consisted of relatively a small number of patients. Lastly, the quality of spongiosum was not recorded in patients' data. Therefore, prospective, randomized, double-blind studies with larger populations are needed to corroborate the findings of this study.

Conclusion

The findings of this study suggest that grafting the deeply incised plate and split glans may reduce the fistula rate and prevent meatal or neo-urethral stenosis. Additionally, even though the difference was not statistically significant, lower complication rates achieved with GATS technique as compared to the TIPU technique. In conclusion, GATS technique stands

out as a good alternative to TIPU technique, particularly for use in difficult hypospadias cases with narrow plate and small glans.

References

1. Snodgrass W. Tubularized, incised plate urethroplasty for distal hypospadias. *J Urol.* 1994;151(2):464-5. doi: 10.1016/S0022-5347(17)34991-1.
2. Braga LHP, Lorenzo AJ, Salle JLP. Tubularized incised plate urethroplasty for distal hypospadias: A literature review. *Indian J Urol.* 2008;24(2):219-25. doi: 10.4103/0970-1591.40619.
3. Braga LHP, Pippi Salle JL, Lorenzo AJ, et al. Comparative Analysis of Tubularized Incised Plate Versus Onlay Island Flap Urethroplasty for Penoscrotal Hypospadias. *J Urol.* 2007;178(4):1451-1457. doi: 10.1016/j.juro.2007.05.170.
4. Holland AJA, Smith GHH. Effect of the depth and width of the urethral plate on tubularized incised plate urethroplasty. *J Urol.* 2000;164(2):489-91. doi: 10.1016/S0022-5347(05)67408-3
5. Perera M, Jones B, O'Brien M, Hutson JM. Long-term urethral function measured by uroflowmetry after hypospadias surgery: Comparison with an age matched control. *J Urol.* 2012;188(4 SUPPL.):1457-62. doi: 10.1016/j.juro.2012.04.105.
6. Shuzhu C, Min W, Yidong L, Weijing Y. Selecting the right method for hypospadias repair to achieve optimal results for the primary situation. *Springer plus.* 2016;5:1624. doi: 10.1186/s40064-016-3314-y.
7. Kolon TF, Gonzales ET. The dorsal inlay graft for hypospadias repair. *J Urol.* 2000;163(6):1941-3. doi: 10.1016/S0022-5347(05)67603-3.
8. Gundeti M, Queteishat A, Desai D, Cuckow P. Use of an inner preputial free graft to extend the indications of Snodgrass hypospadias repair (Snodgraft). *J Pediatr Urol.* 2005;1(6):395-6. doi: 10.1016/j.jpuro.2005.03.010.
9. Silay MS, Sirin H, Tepeler A, et al. "Snodgraft" technique for the treatment of primary distal hypospadias: Pushing the envelope. *J Urol.* 2012;188(3):938-42. doi: 10.1016/j.juro.2012.04.126
10. Eldeeb M, Nagla S, Abou-Farha M, Hassan A. Snodgrass vs Snodgraft operation to repair the distal hypospadias in the narrow urethral plate. *J Pediatr Urol.* 2020;16(2):165.e1-165.e8. doi: 10.1016/j.jpuro.2020.01.006.
11. Helmy TE, Ghanem W, Orban H, et al. Does grafted tubularized incised plate improve the outcome after repair of primary distal hypospadias: A prospective randomized study? *J Pediatr Surg.* 2018;53(8):1461-3. doi: 10.1016/j.jpedsurg.2018.03.019.
12. Cherian A, Smeulders N. Graft Augmented Tubularised Split (GATS). In: 27th Congress of European Society of Paediatric Urology, Harrogate, UK. 2016.
13. Tugtepe H, Thomas DT, Calikli Z, et al. A new objective scoring system for the prediction of complications after hypospadias surgery. In: 29th Congress of ESPU, 2018, Abstract Book. 96. doi: 10.29052/2413-4252.v4.i1.2018.23-55.
14. Sarhan O, Saad M, Helmy T, Hafez A. Effect of Suturing Technique and Urethral Plate Characteristics on Complication Rate Following Hypospadias Repair: A Prospective Randomized Study. *J Urol.* 2009;182(2):682-6. doi: 10.1016/j.juro.2009.04.034
15. Thomas, David Terence Calikli Z, Canmemis A, Ergun R, Valiyev N, et al. Prediction of TIPU complications using an objective scoring system. In: 29th Congress of the ESPU. Vol Abstract b. ; 2018:97.
16. Bush NC, Snodgrass W. Pre-incision urethral plate width does not impact short-term Tubularized Incised Plate urethroplasty outcomes. *J Pediatr Urol.* 2017;13(6):625.e1-625.e6. doi: 10.1016/j.jpuro.2017.05.020.
17. Leslie B, Jesus LE, El-Hout Y, et al. Comparative histological and functional controlled analysis of tubularized incised plate urethroplasty with and without dorsal inlay graft: A preliminary experimental study in rabbits. *J Urol.* 2011;186(4 SUPPL.):1631-7. doi: 10.1016/j.juro.2011.04.008.
18. Mouravas V, Filippopoulos A, Sfoungaris D. Urethral plate grafting improves the results of tubularized incised plate urethroplasty in primary hypospadias. *J Pediatr Urol.* 2014;10(3):463-468. doi: 10.1016/j.jpuro.2013.11.012
19. Ahmed M, Alsaïd A. Is combined inner preputial inlay graft with tubularized incised plate in hypospadias repair worth doing? *J Pediatr Urol.* 2015;11(4):229.e1-229.e4. doi: 10.1016/j.jpuro.2015.05.015
20. Asanuma H, Satoh H, Shishido S. Dorsal inlay graft urethroplasty for primary hypospadiac repair. *Int J Urol.* 2007;14(1):43-7. doi: 10.1111/j.1442-2042.2006.01662.x
21. Nerli RB, Guntaka AK, Patil RA, Patne PB. Dorsal inlay inner preputial graft for primary hypospadias repair. *African J Paediatr Surg.* 2014;11(2):105-8. doi: 10.4103/0189-6725.132789
22. Abbas TO, Braga LH, Spinoit AF, Salle JLP. Urethral plate quality assessment and its impact on hypospadias repair outcomes: A systematic review and quality assessment. *J Pediatr Urol.* 2021 Jun;17(3):316-25. doi: 10.1016/j.jpuro.2021.02.017.

The National Library of Medicine (NLM) citation style guide has been used in this paper.