



Acute fulminant liver failure, COVID -19 and 2-day intensive care unit follow-up period: A Case Report

Duygu DEMİZİZ GÜLMEZ^{1,*}, Hilal AKÇA², Raziye TURAN³

¹Department of Anesthesiology and Reanimation, Faculty of Medicine, Giresun University, Giresun, Turkey

²Department of Anesthesiology and Reanimation, Ministry of Health Sebinkarahisar State Hospital, Giresun, Turkey

³Department of Anesthesiology and Reanimation, University of Giresun, Prof. Dr. A. İlhan Özdemir Training and Research Hospital Training and Research Hospital, Giresun, Turkey

Received: 15.08.2021

Accepted/Published Online: 15.11.2021

Final Version: 18.03.2022

Abstract

We aimed to share our case who developed liver failure due to covid-19, which is more severe than we have ever encountered. A 67-year-old male patient was brought to our hospital by ambulance with complaints of weakness and eating and drinking disorder. In the first examination, the patient was conscious, oriented and cooperative. The liver and kidney function tests and whole blood parameters of the patient at the first admission were within normal limits. The patient was admitted to the intensive care unit because of comorbidities and oxygen support may be required. It was found that the patient's liver function tests were found to be elevated in the examinations on the first intensive care unit day. Transplantation and Plasmapheresis could not be performed due to the patient's general condition. In the follow-up, orotracheal intubation was performed for the patient whose general condition deteriorated, blood pressure decreasing and positive inotropic therapy was initiated on the second ICU day. The patient whose general condition deteriorated could not be saved despite all interventions. Although our knowledge about SARS-CoV-2 is not sufficient yet, we think that it should be kept in mind that it may also cause fulminant liver failure.

Keywords: SARS-CoV-2, fulminant liver failure, covid-19, intensive care unit

1. Introduction

A previously unidentified viral pneumonia was detected in Wuhan, China, from December 31, 2019, to January 7, 2020. After these dates, the virus spread all over the world and caused a pandemic. The first case of the pandemic was seen on March 11, 2020, in Turkey. COVID-19 ranging in severity from mild asymptomatic disease to severe acute respiratory distress syndrome and has become a central health problem worldwide. We aimed to share our case who developed liver failure due to covid-19, which is more severe than we have ever encountered. The SARS-CoV-2 virus typically presents with fever and upper respiratory tract symptoms. Non respiratory symptoms of SARS-CoV-2 infection include gastrointestinal symptoms such as diarrhea, vomiting and abdominal pain occurring in 17.6% of patients (1). It is observed in 18.2% of patients with non-severe disease and 39.4% of patients with severe disease (2). While research on the pathogenesis of the disease and its effects in different populations was ongoing, we aimed to report our health care worker who presented with SARS-CoV-2 infection and non-icteric hepatitis with fulminant course.

2. Case Report

A 67-year-old male patient was brought to our hospital by ambulance with complaints of weakness and eating and

drinking disorder. It was learned from the patient that he had been hospitalized for 5 days due to COVID-19 and left the hospital, refusing the treatment of his own will. In the first examination, the patient was conscious, oriented and cooperative. He had no spontaneous breathing effort, no dyspnea, mild tachypnea (respiratory rate was 25/min), his oxygen saturation (SPO₂) was 98% with receiving 8 L/min oxygen support from reservoir mask. His heart rate was 74/min and his blood pressure was 100/70 mmHg. The patient with known congestive heart failure, pacemaker, ischemic heart disease, hypertension, diabetes mellitus, chronic renal failure without need of dialysis was hospitalized in the intensive care unit (ICU). When the drugs he used we questioned, it was learned that he had been using metoprolol, carvedilol, clopidogrel and furosemide. Also, he was using favipiravir for 5 days for the treatment of COVID-19. The liver and kidney function tests and whole blood parameters of the patient at the first admission were within normal limits (Table 1). The patient was admitted to the intensive care unit because of comorbidities and oxygen support may be required. On the first day of the patient's stay in the intensive care unit, symptomatic treatment was arranged after consultations with gastroenterology, infectious diseases, cardiology and internal medicine departments. It

*Correspondence: duygudemiriz@hotmail.com

was found that the patient's liver function tests were found to be elevated in the examinations on the first intensive care unit day at 12.00 a.m. (Table 1).

Table 1. Laboratory parameters of the patient on ward, on ICU first day and on ICU second day

	WARD	ICU 1.day	ICU 2.day
WBC (10 ⁹ /l)	10.40	18.04	17.06
Hb/Htc(g/dL/%)	11.8/37	13.3/41.8	13.1/40.3
Lymphocyte (10 ⁹ /L)	0.45	0.73	0.65
Platelet (10 ⁹ /L)	257	182	167
ALT (U/L)	25	1127	1712
AST (U/L)	41	1046	1647
Urea (mg/dL)	281.0	273.0	322.0
Creatinine (mg/dL)	3.33	2.93	3.36
D dimer (ng FEU/ml)		6412	6325
INR	1.38	6.02	
CRP (mg/L)	25	25	30
Procalcitonin (ng/ml)		0.55	
Albumin (g/L)		35.2	
Total Bilirubin/Direct Bilirubin (mg/dL)	0.61-0.39	1.87/0.82	2.23/1.31
pH		7.354	7.228
pO ₂ (mmHg)		361.9	153.5
pCO ₂ (mmHg)		26.9	20.1
Lactate (mmol/L)		5.09	10.81
HCO ₃ std (mmol/L)		17.2	11.7
K (mmol/L)		5.12	5.81
O ₂ % (est)		98.7	99.8

It was thought that there was moderate to severe lung involvement in the chest X-ray (Fig.1) There was no evidence of hypoxia, ischemia or hypotension that would cause liver failure. The viral hepatitis markers (anti-HAV IgM, HBsAg, anti-HBs, anti-HBc IgM and IgG, anti-HCV), autoimmune markers (ANA, ASMA, AMA, anti-LKM), ceruloplasmin, Fe, TIBC, % Fe saturation, ferritin investigated were negative. All causes of fulminant non-icteric hepatitis (medicines, infections) and acute liver failure were excluded. Transplantation was arranged after consultations with gastroenterology, infectious diseases, cardiology and internal medicine departments. Upon this, the situation was discussed with the transplantation center, but it was stated that transplantation could not be performed due to the current condition of the patient, his additional diseases and contagious disease. With the diagnosis of acute renal failure, hemodiafiltration was initiated in the patient who developed anuria during follow-up and whose renal function tests deteriorated on the first ICU day at 21.00 p.m. Plasmapheresis could not be performed due to the patient's general condition. In the follow-up, orotracheal intubation was performed for the patient whose general condition deteriorated, blood pressure decreasing and positive inotropic therapy was initiated on the second ICU day 08.00 a.m. The patient whose general condition deteriorated further on the second day of his intensive care hospitalization at 13.00 a.m. could not be saved despite all interventions. Written informed consent was obtained from the patient's family for this study.

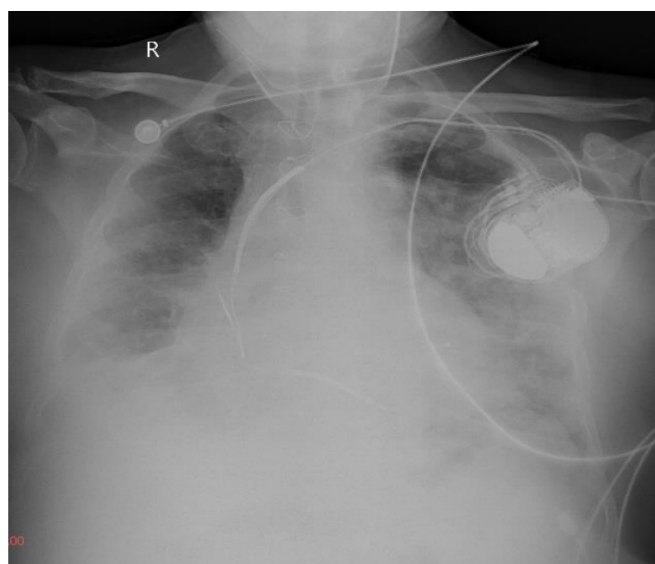


Fig. 1. Chest x-ray of the patient at ICU

3. Discussion

In our case report, we tried to explain the rapidly progressive liver failure, which we thought was caused by covid-19. Liver injury is more common among patients admitted to the intensive care unit, reaching up to 62% compared to 25% of patients who do not require intensive care. In most patients, liver damage is temporary and no intervention is required. The mechanism of liver damage in patients with COVID-19 may be due to the fact that SARS-CoV-2 directly infects liver cells (2). Similar to the respiratory viruses, SARS-CoV-2 can induce hepatic damage through an altered immune response involving cytotoxic T cells and Kupffer cells (3). Although other reasons other than COVID-19, especially liver failure secondary to multiple organ dysfunction syndrome, could not be completely excluded in our patient, hypotension was avoided in our patient whose EF was 20%, and in the follow-up, the patient did not develop hypotension, and because of the absence of hypoxia, the diagnosis of ischemic hepatitis was excluded. Viral markers and autoimmune markers were negative and there was no history of chronic liver disease. While high levels of liver aminotransferase have been observed in SARS-CoV-2 infection, severe liver failure has not been defined yet in similar situations (4). Favipiravir, which was also used in the treatment of our patient, was an RNA polymerase inhibitory antiviral agent (5). During Favipiravir treatment; diarrhea, increased transaminase levels, hyperuricemia and neutropenia may develop. The reported elevation in transaminase level secondary to the Favipiravir use was never as high as we encountered in our patient. Since it is not metabolized by the CYP450 system, it does not interact with drugs metabolized by this pathway. Wander et al. presented a case of acute hepatitis after covid-19 in a 59-year-old female patient with immunosuppression.

This patient presented with gastrointestinal symptoms such as vomiting and abdominal pain. Unlike our patient, hydroxychloroquine was used in the treatment of covid-19 in

the patient whose hepatitis markers were negative, as in our patient. The patient recovered completely with supportive treatment and the drugs she used herself (6).

In the case report of Melquist et al., a 36-year-old female patient who presented with gastrointestinal symptoms developed a sudden onset of clouding of consciousness on the 3rd day of follow-up. The patient, who was intubated on the fourth day and the diagnosis of liver failure was supported by transjugular biopsy, was successfully extubated 1 week after admission. Liver transplantation was also discussed in this patient, but it was observed that the patient recovered completely with supportive treatment (7).

Our patient had eating and drinking disorders and loss of appetite. Unlike the patients in the literature, our patient used favipiravir instead of hydroxychloroquine. Since we are in the discussing of the treatment (transplantation) of our patient and rapidly progress we could not have a radiological examination. The rapid progression and the need for dialysis after the sudden increase in liver enzymes have taken us away from liver disease due to drug interaction.

Although our knowledge about SARS-CoV-2 is not sufficient yet, we think that it should be kept in mind that it may also cause fulminant liver failure.

Conflict of interest

None.

Acknowledgments

None.

References

1. Cheung KS, Hung IFN, Chan PPY et al (2020) Gastrointestinal manifestations of SARS-CoV2 infection and virus load in fecal samples from a Hong Kong cohort: Systematic review and meta-analysis. *Gastroenterology* 159(1): 81–95.
2. Zhang C, Shi L, Wang FS (2020) : Liver injury in COVID-19: Management and challenges. *Lancet Gastroenterol Hepatol* 5(5): 428–30
3. Lee YH, Bae SC, Song GG(2013) Hepatitis B virus reactivation in HBsAg-positive patients with rheumatic diseases undergoing anti-tumor necrosis factor therapy or DMARDs. *Int J Rheum Dis* 16(5): 527–31
4. Ong J, Young BE, Ong S (2020) COVID-19 in gastroenterology: a clinical perspective. *Gut* 69:1144–5.
5. Shiraki K, Daikoku T (2020) Favipiravir, an anti-influenza drug against life-threatening RNA virus infections. *Pharmacology & Therapeutics* 10751.
6. Wander P, Epstein M, Bernstein D (2020) COVID-19 presenting as acute hepatitis. *Am J Gastroenterol* 115(6): 941–42.
7. Melquist, S., Estep, K., Aleksandrovich, Y., Lee, A., Beiseker, A., Hamedani, F. S., Bassett, J (2020) COVID-19 presenting as fulminant hepatic failure: A case report. *Medicine* 99(43).