

The effects of technical factors on the fractal dimension in different dental radiographic images

Purpose

The aim of this study was to assess the impact of exposure parameters and image formats on fractal dimension (FD) values in periapical, panoramic, and CBCT images.

Materials and Methods

Seven dry male mandibles were selected, and a Gutta-Percha was used to identify identical regions of interest. A periapical radiograph was taken with 60 kVp/7 mA and exported in DICOM, JPEG, TIFF, and PNG formats. Nine periapical radiographs (60, 65, 70 kVp; 4, 5, 6 mA) were taken from seven dry human mandibles. Additionally, 12 panoramic radiographs (60, 70, 81, 90 kVp; 5, 8, 13 mA) and 10 CBCT images (with different scanning options and FOVs) were taken from each mandible. FDs were measured from a standard area.

Results

The intra-class correlation coefficient demonstrated a high degree of agreement between observers. No significant difference was found between TIFF and PNG formats ($p > 0.05$). The highest FD mean was found in TIFF format, while the lowest FD mean was found in JPEG format ($p < 0.001$). There was no significant difference between kVp and mA settings in periapical images. In panoramic images, a significant difference was found at 90 kVp ($p = 0.001$) and 13 mA ($p < 0.001$), with lower FD values observed at these settings. There was no significant difference between FOV and resolution in CBCT images ($p > 0.05$).

Conclusion





The format of the image can influence FD. For periapical and panoramic radiographs, kVp and mA settings do not have a significant impact on FD. However, fractal analysis may not be an ideal method for evaluating three-dimensional images, such as those obtained with CBCT.

Keywords: Fractal analysis, Exposure parameters, Image format, Dental radiography, CBCT

Introduction

Fractal analysis (FA) is a mathematical technique utilized to evaluate complex structures and quantify their degree of irregularity through a numerical value known as the fractal dimension (FD). This method has been employed by radiologists as a tool to assess bone tissue quality and bone mineral density (1, 2), and it has been used for various purposes in dentistry (3). Previous research on FA has utilized a range of dental radiographic images, including panoramic, periapical, bitewing, cephalometric, and cone-beam computed tomography (CBCT), which are commonly employed in dentistry (1, 4).

FA can only be performed on digital radiographic images, but these images must be processed in advance. To this end, White and Rudolph developed a method using ImageJ software (<https://imagej.nih.gov/ij/>) with

Mehmet Amuk¹ ,
Gamze Şirin Sarıbal¹ ,
Nihal Ersu¹ ,
Serkan Yılmaz¹ 

ORCID IDs of the authors: M. A. 0000-0001-6390-7169;
G. S. S. 0000-0002-5191-377X; N. E. 0000-0002-1356-9971;
S. Y. 0000-0001-7149-0324

¹Department of Oral and Maxillofacial Radiology, Faculty of Dentistry, Erciyes University, Kayseri, Türkiye

Corresponding Author: Gamze Şirin Sarıbal

E-mail: g.sirin20@gmail.com

Received: 18 August 2021

Revised: 31 May 2022

Accepted: 24 June 2022

DOI: 10.26650/eor.2023984422

the aim of making inferences about bone microarchitecture using radiographic images and FA (5). The resolution of the images is a crucial factor in ensuring accurate and realistic evaluations. However, image resolution is directly affected by scanning and exposure parameters such as peak tube voltage (kVp), tube current (mA), exposure time, scan time, the field of view (FOV), and voxel-pixel size (6). The selection of FOV has a significant impact on the quality of CBCT images and the visualization of anatomical structures (7). Moreover, several factors can influence FD, including the compression and recording format of the radiographic image, as well as the size and location of the regions of interest (ROI) within the bone being analyzed. The effect of these factors on FD has been a subject of debate in the literature, with some studies reporting minimal differences in FD associated with exposure parameters (8-13).

Digital Imaging and Communications in Medicine (DICOM) is a widely accepted image format designed for medical radiographic imaging, despite having some disadvantages. Other commonly used formats include Joint Photographic Experts Group (JPEG), Tagged Image File Format (TIFF), Portable Network Graphics (PNG), Bitmap (BMP), and Graphics Interchange Format (GIF) (14, 15). JPEG is a popular image format on all platforms, known for its compression capability. On the other hand, TIFF is an adaptable image format that uses lossless compression (LC) (14, 16). PNG was developed to replace the GIF format and is useful in medical imaging due to its LC, which results in the created image being the same as the original after decompression (16). The effects of compression on image quality or qualitative and quantitative measurements in digital radiography are important issues that need to be investigated. Although the analysis part of the FA method has some standardized steps through a computer program, there are non-standardized steps such as the methods of obtaining the radiographs, the selection of areas to be measured, and the recording formats of the images (5). The purpose of this study is to evaluate the effects of exposure parameters and image formats on FD values using periapical, panoramic, and CBCT images.

Materials and Methods

Ethical approval and study design

This study is a retrospective in-vitro study conducted in the Department of Oral and Maxillofacial Radiology at Erciyes University Faculty of Dentistry. It does not include a control group. The study was approved by the Erciyes University Clinical Research Ethics Committee. The study started with the following hypotheses: Different image formats can affect FD, exposure parameters can affect FD in periapical radiograph, exposure parameters can affect FD in panoramic radiographs and FOV and different scanning resolutions can affect FD in CBCT images.

Specimens

The present study included the use of edentulous dry mandibles from seven male cadavers that did not have any pathologies or diseases affecting bone metabolism and were aged between 50-70 years. To ensure consistency,

each mandible was marked with a Gutta-Percha to identify a specific ROI. The marked area was a 6×6 mm square region located distal to the mental foramen in the periapical bone area, without any overlap with the tooth roots or periodontal space.

Radiographic imaging

The mandibles were positioned on a hard and fixed surface to ensure consistent projection geometry throughout the imaging procedures. Periapical radiographs were captured using the Kodak 2100 Intraoral X-Ray System (Kodak, New York, USA) and size 2 photostimulable phosphor plates (PSP). The dental X-ray unit was set to operate at 1.5 mm Al equivalent filtration, 0.2 s exposure time, and a focus-receptor distance of 25 cm. The parallel technique was employed to obtain all periapical images (Figure 1A-1B). Firstly, periapical radiographs were captured using 60 kVp/7 mA values, which were accepted by the device as the standard for periapical radiography in adults.

The images were exported in uncompressed DICOM, JPEG, TIFF, and PNG formats. Following that, nine periapical radiographs were taken from each mandible using 60, 65, and 70 kVp and 4, 5, and 6 mA values, respectively, resulting in 70 periapical images. The photostimulable phosphor plate (PSP) was scanned immediately after exposure using the Express Digital Imaging Plate Scanner (Instrumentarium Dental, Tuusula, Finland) in standard resolution.

Panoramic radiographs were acquired using the Instrumentarium Dental Orthopantomograph OP200 D (Instrumentarium Dental, Tuusula, Finland). The device is equipped with radial reference lines that assist in patient positioning and ensure alignment of the midsagittal plane and Frankfort plane. The position of each mandible was fixed during image acquisition with the aid of these lines (Figure 2). Initially, panoramic radiography was performed using 66 kVp/8 mA values, which were considered as the standard for panoramic radiography in adults. Subsequently, 12 panoramic radiographs were taken from each mandible, with varying exposure parameters of 60, 70, 81, and 90 kVp and 5, 8, and 13 mA values, respectively, resulting in a total of 91 panoramic images.

CBCT images were acquired using the Newtom CBCT device (Newtom5G, QR, Verona, Italy). Radial reference lines were used as a guide, similar to the panoramic radiography device. Five different scan FOVs were employed, namely 8×8, 12×8, 15×12, and 18×16, with varying scanning options. These options included standard resolution standard dose (STD), standard resolution high dose (BOOSTED), and high resolution (HIRES). However, for the HIRES resolution of the device, only 8×8 and 12×8 FOV values were available, and images were captured accordingly. A total of 70 CBCT images were produced. The exposure parameters in all radiography techniques were modified within the permissible limits of the respective devices. The images obtained through periapical, panoramic, and CBCT techniques were saved in uncompressed TIFF format.

Fractal analysis

The images were analyzed by three oral and maxillofacial radiologists using NNT software (Version 9.1), which is the

original software of the CBCT machine (Newtom5G, QR, Verona, Italy) for CBCT images, on a Dell Precision T5400 workstation with a 19-inch 1920x1080 resolution monitor (Dell E1905, China). The radiologists had three years of clinical experience and were blinded to the parameters from which the images were taken. All regions of interest (ROIs) were within the marked area borders, and the measured locations were the same regardless of technical parameter changes or imaging methods.

Firstly, FDs were calculated to assess the effects of image formats. ROIs were placed at specific X and Y coordinates using features provided by the software to ensure they were all at the same point. This ensured that ROIs in all formats (DICOM, JPEG, PNG, TIFF) were of the same size and position (see Figure 3). To evaluate the effects of exposure parameters, FD was calculated on radiographic images taken with different parameters. The size of ROIs was determined to be the maximum size allowed by the marked area in the images. The size of ROI on periapical radiographs was 70x70 pixels (see Figure 4A), on panoramic radiographs, it was 50x50 pixels (see Figure 4B), and on CBCT images, it was 40x40 pixels (see Figure 4C). FA was carried out on ImageJ version 1.53 software using the box-counting method defined by White and Rudolph (5) (see Figure 5).

Statistical analysis

The statistical analysis was performed using SPSS v26 (IBM, Armonk, New York, USA). To determine the level of agreement between observers, the intra-class correlation coefficient (ICC) with a 95% confidence interval (CI) was calculated. Statistical differences were assessed using one-way repeated measures ANOVA followed by Bonferroni's post hoc test. A p-value less than 0.05 was considered statistically significant.

Results

ICC showed a high degree of agreement between observers in all image format and imaging methods measurements (Table 1).

Image format

Based on the analysis of variance using mean FD values, it was determined that there was no significant difference

between the FD values of TIFF and PNG formats ($p > 0.05$) as they already had the same FD value. However, a statistically significant difference was observed between the FD values of TIFF (and PNG), DICOM, and JPEG formats ($p < 0.001$). Among these formats, TIFF (and PNG) had the highest mean FD value, whereas JPEG had the lowest mean FD value, as shown in Table 2.

Exposure parameters

In the analysis of variance performed on FD measurement values obtained with the periapical radiography technique, it was found that there was no significant difference between the values of kVp and mA exposure parameters ($p > 0.05$) (Table 3). For the panoramic radiography technique, a significant difference was found in the FD values of 90

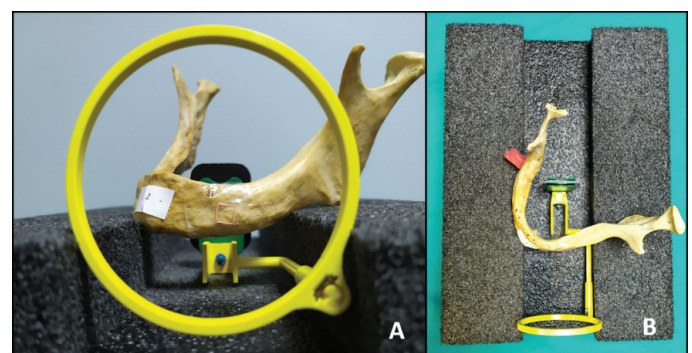


Figure 1. A, Positioning of the mandible and apparatus for taking periapical radiographs with the parallel technique. B, mandible was placed on a hard and constant floor for stabilization.

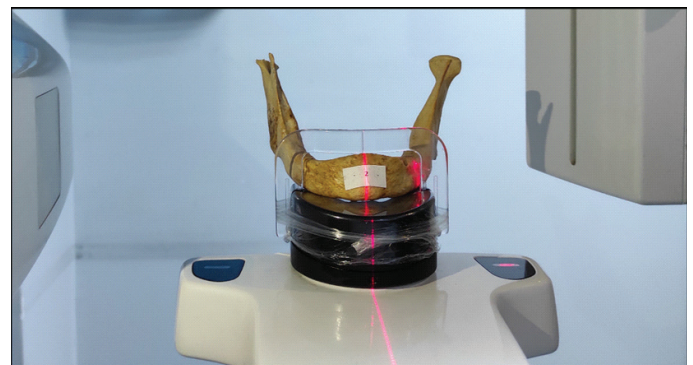


Figure 2. Positioning of dry human mandible for panoramic radiograph.

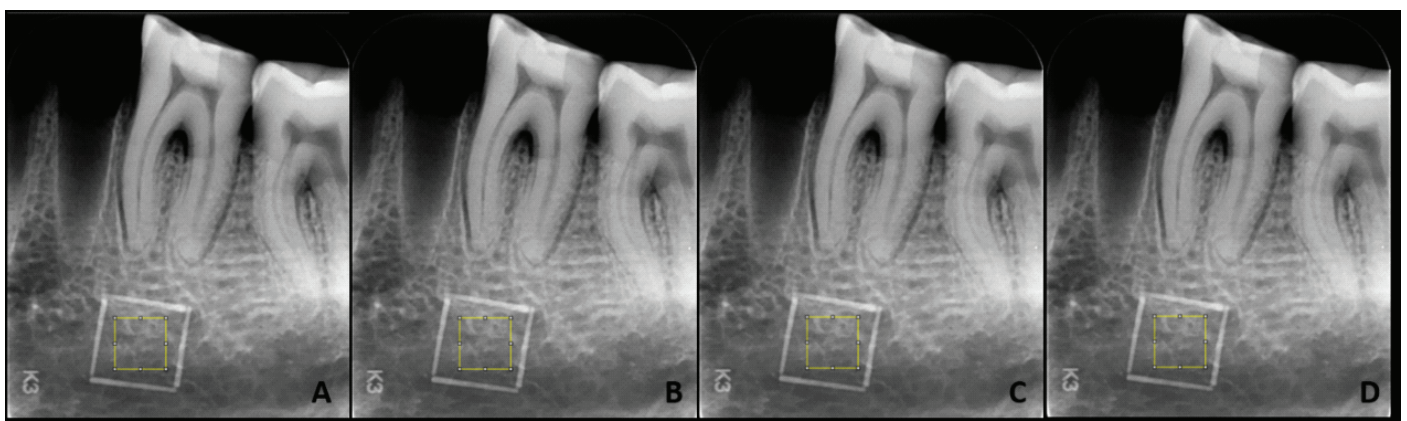


Figure 3. Periapical radiographs with different image formats placed on the marked area. A; DICOM, B; JPEG, C; PNG, D; TIFF.

kVp/13 mA ($p < 0.05$). The FD was found to be lower in the 90 kVp/13 mA exposure parameters (Table 4). In the analysis of variance using FD measurement values in the images obtained with the CBCT technique, no significant difference was found between all groups, including FOV and resolution ($p > 0.05$) (Table 5).

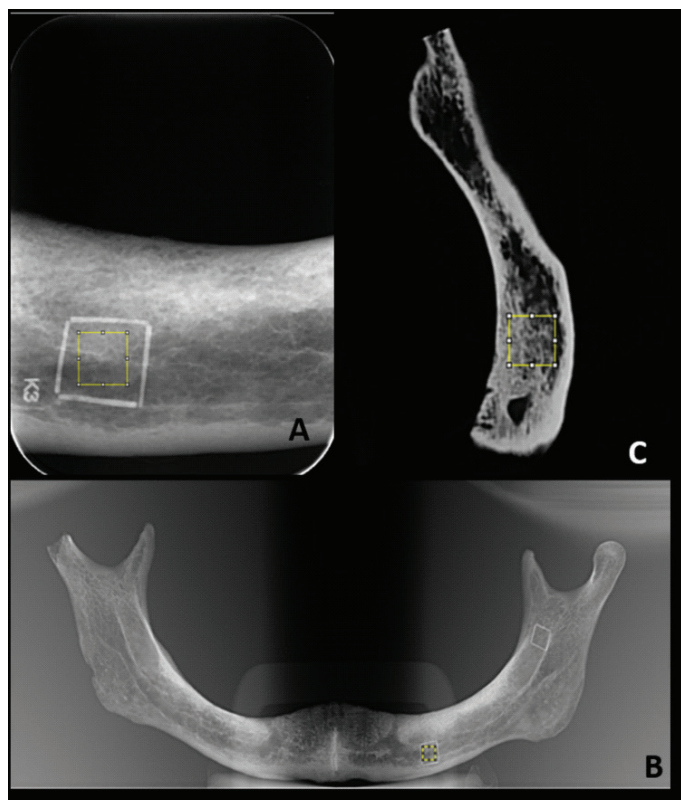


Figure 4. A; periapical radiograph with a 70x70 ROI inserted within the marked area borders, B; panoramic radiograph with a 50x50 ROI inserted within the marked area borders, C; CBCT images with 40x40 ROI inserted within the marked area borders.




Figure 5. Steps of fractal analysis.

Discussion

To ensure clinical reliability and value of a bone analysis method, it should be able to operate independently of technical parameters and demonstrate stability against varying parameters, as the obtained results should remain consistent (13).

DICOM is a widely accepted image format designed for medical radiographic imaging. However, DICOM has some disadvantages. It cannot be viewed without a special viewer (such as ImageJ or DICOM Works), and it has a larger file size

Table 1. The Intra-Class Correlation (ICC) coefficient between the raters in imaging methods

	ICC (95%CI)	P
Image Formats Measurements	0.947(0.893-0.991)	0.001*
Periapical Radiography Measurements	0.932(0.807-0.988)	0.002*
Panoramic Radiography Measurements	0.947(0.893-0.991)	0.001*
CBCT Measurements	0.953(0.829-0.992)	0.001*

ICC (%95 CI): Intra-Class Correlation with 95% confidence interval. *Significant at $p \leq 0.05$

Table 2. Comparison of fractal dimension results for different image format measurements on periapical radiography.

Image Format	n	mean	SD	p	F
DICOM	7	1.254 ^b	0.057	0.000*	F=32.70
JPEG	7	1.252 ^c	0.055		
TIFF	7	1.264 ^a	0.057		
PNG	7	1.264 ^a	0.057		

n: number of dry mandible, SD; standard deviation F: One-way repeated measures ANOVA, *Significant at $p \leq 0.05$, a, b, c: the difference between the averages without the common letter is significant

because DICOM is a data set that includes different types of data, such as demographic information of the individual, imaging parameters of the device, and matrix size of the image (14, 15). JPEG is a widely used and compression-capable format. Thanks to this compression feature, JPEG offers an easy and high level of portability. However, the images produced have poorer quality than TIFF or DICOM. TIFF uses LC, making it the best choice for a master copy (14, 16). PNG is also very useful in medical imaging due to its LC. The image created after decompression is the same as the original (16).

In our study, it was found that PNG and TIFF had significantly higher FD, which was an expected result, as these formats use the LC technique. In contrast, JPEG had the lowest FD significantly, which was also an expected result because JPEG causes LC in the image.

Toghyani *et al.* (17) conducted a study comparing FD values across different image formats, resolutions, and compression levels (CL) on periapical radiographs. They found that FD increased with increasing resolution and that the most consistent and reliable FD value was obtained at high resolution. Baksi *et al.* (18) compared the effects of different compression levels on periapical radiographs using JPEG and JPEG2000 formats. They found that FA was insensitive to CL and confirmed the validity of FA, which was consistent with previous studies that reported insensitivity to changes in exposure parameters and projection geometry (8, 19). In a similar vein, Yaşar *et al.* (20) also found that the FD value was higher in the TIFF format than in the JPEG format, which is consistent with our study findings.

Fractal images exhibit a high degree of similarity between the points of the image, making them particularly susceptible to the negative effects of noise. Increased noise levels can impede correct diagnosis and early treatment, particu-

Table 3. Comparison of fractal dimension results for periapical radiography measurements

kVp/mA	4		5		6		7		F	p
	Mean	SD	Mean	SD	Mean	SD	Mean	SD		
60	1.201	0.049	1.198	0.058	1.206	0.059	1.204	0.069	0.161	0.921
65	1.187	0.034	1.217	0.039	1.189	0.070			1.548	0.260
70	1.189	0.033	1.197	0.044	1.197	0.044			0.283	0.758
F	0.489		0.788		1.001					
P	0.625		0.421		0.396					

SD; standard deviation, F: One-way repeated measures ANOVA, Significant at $p \leq 0.05$.

Table 4. Comparison of fractal dimension results for panoramic radiography measurements

kVp/mA	5		8		13		F	p
	Mean	SD	Mean	SD	Mean	SD		
60	1.331	0.056	1.355	0.036	1,345 ^A	0.048	0,994	0,399
66			1.352	0.044				
70	1.343	0.035	1.327	0.037	1,341 ^{AB}	0.045	3,043	0,085
81	1.348	0.029	1.339	0.029	1,331 ^{AB}	0.047	1,206	0,333
90	1.345 ^a	0.027	1.347 ^a	0.032	1,280 ^{Bb}	0.041	13,583	0,001*
F	0.421		2.240		13.334			
P	0.578		0.095		0.000*			

SD; standard deviation, F: One-way repeated measures ANOVA, *Significant at $p \leq 0.05$ A, B: In the same column, the difference between the mean kVp without common capital letters is significant. a,b: In the same row, the difference between the mA averages without the common lowercase letter is significant

Table 5. Comparison of fractal dimension results for CBCT measurements.

FOV/Resolution	Standard		Boosted		HiRES		F or t	p
	Mean	SD	Mean	SD	Mean	SD		
8x8	1.304	0.089	1.334	0.090	1.329	0.081	1.338	0.299
12x8	1.313	0.077	1.337	0.085	1.324	0.067	0.997	0.358
15x12	1.330	0.082	1.328	0.087			0.180	0.863
18x16	1.313	0.083	1.335	0.070			-1.639	0.152
F or t	1.326		0.160		0.746			
P	0.297		0.922		0.484			

Standard: standard dose standart resolution scannig, Boosted: standart dose high resolution scanning, HiRES: high dose high resolution scanning, SD; standard deviation. t:Paired t-test, F: One-way repeated measures ANOVA, Significant at $p \leq 0.05$

larly in the early stages of lesions (21). Previous studies have demonstrated that exposure parameters can influence the amount of noise present in images (22, 23).

In our study, there was no statistically significant difference found in the FD of periapical radiographs. This is consistent with the findings of a previous study that evaluated exposure parameters on periapical radiographs and found no significant difference in FDs (8). Given the high level of detail and clarity provided by periapical images, it is believed that FD is not affected by changes in exposure parameters. In panoramic radiographs, FD was not significantly affected up to 90 kVp and 13 mA, but there was a statistically significant difference in images taken with 90 kVp and/or 13 mA. FD changed in images taken with less than 13 mA and 90 kVp or with less than 90 kVp and 13 mA. To the best

of our knowledge, there are no studies on the effects of exposure parameters on FA in panoramic images in the literature. Therefore, previous studies that have investigated the effects of exposure parameters on image quality have been reviewed in this study.

In a previous study, panoramic images that provide less detail were found to have lower FD values than periapical images that offer higher detail (24). Similarly, PSP scanned at higher resolutions were found to have higher FD values (12, 17). Although previous studies did not directly investigate the effects of different kVp-mA settings on FD in panoramic radiographs, we believe that our results are related to the varying spatial resolution, based on the information provided by these studies. However, further research is necessary to fully explore this topic.

In our study, we found no statistically significant differences in FD values between CBCT images taken with different FOV sizes. This finding is consistent with a study by Tsai *et al.* (25), which evaluated the effects of scanning protocols on bone microarchitecture in CBCT images using the ImageJ program and found that resolution mode did not affect the trabecular parameters. However, it should be noted that there are studies in the literature indicating that changes in CBCT scanning parameters can alter image quality (27-30). Furthermore, in a study by Corpas *et al.* (26) that evaluated bone density with CBCT images and histological bone sections in animal experiments, the authors found that FD values of two-dimensional CBCT image sections and histological sections were not compatible. This suggests that analyzing two-dimensional sections obtained from CBCT images using the ImageJ program may not provide accurate results. To address this issue, current publications recommend using the BoneJ extension of the ImageJ program for three-dimensional images, and using three-dimensional FD analysis (31, 32). This approach can provide more accurate and reliable results for FD analysis of CBCT images.

The goal of the researchers was to make the evaluation of bone microarchitecture with FA applicable to clinical practice. They achieved this by evaluating clinical conditions like orthognathic surgery healing and implant osseointegration using FA (33, 34). It is believed that FA can be useful in assessing bone quality before and after surgical procedures. We anticipate that this application will become more prevalent in the future. Consequently, we believe that it is necessary to standardize the use of FA in these assessments.

To improve the accuracy and reliability of the results, future studies should have larger sample sizes to assess the effects of technical parameters and the FA method on various imaging modalities. Another limitation of this study was the lack of consideration for soft tissue compensation, which may affect the results. Since our study evaluated the effects of technical features, soft tissue compensation was not taken into account. Moreover, it should be noted that each image format has its own advantages and disadvantages that should be taken into account by the radiologist according to the intended use.

Conclusion

FA is a bone analysis technique that is intended for clinical use but its standardization has yet to be clarified. The format of images used for FA can affect the FD. The study findings suggest that using higher resolution TIFF images that are suitable for black and white images can result in more accurate measurements. The parameters, such as kVp and mA, used for periapical and panoramic radiographs do not significantly affect the FD. However, for panoramic images, it is important to avoid using images that were taken with high doses, such as 90 kVp and 13 mA. It is worth noting that FA may not be appropriate for evaluating two-dimensional cross-sectional images of CBCT, and three-dimensional FA methods may be necessary.

Türkçe özet: Farklı Dental Radyografik Görüntülerde Teknik Faktörlerin Fraktal Boyuta Etkisi. Amaç: Işınlama parametreleri ve görüntü formatının fraktal boyuta (FB) etkisini periapikal, panoramik ve KIBT görüntüleri kullanılarak değerlendirmek amaçlanmıştır. Gereç ve Yöntem: Erkek ka-

davralara ait, 7 adet tam dişsiz kuru mandibula seçildi ve belirlenen ilgili alanlar Gutha-Perka kullanılarak işaretlendi. 60 kVp/7mA değerlerinde bir periapikal radyografi alındı ve DICOM, JPEG, TIFF, PNG formatlarında kaydedildi. Sonrasında her mandibuladan sırasıyla 60,65,70kVp/ 4,5,6mA değerlerinde 9 periapikal radyografi; sırasıyla 60,70,81,90kVp/ 5,8,13 mA değerlerinde 12 panoramik radyografi; farklı çözünürlük ve FOV boyutlarında 10 KIBT görüntüsü alındı. Seçilen standart bölgelerden FB ölçüldü. Bulgular: Sınıf içi korelasyon değeri gözlemler arasında yüksek derecede uyum gösterdi. TIFF ve PNG formatları arasında istatistiksel olarak anlamlı bir fark yoktu. ($p>0.05$) FB değeri en yüksek TIFF formatında, en düşük JPEG formatında ölçüldü. ($p<0.001$) Periapikal görüntülerde farklı kVp ve mA parametreleri arasında anlamlı bir fark yoktu. ($p>0.05$) Panoramik görüntülerde 90 kVp/13 mA parametrelerinde daha düşük FB ölçüldü. ($p<0.001$) KIBT görüntülerinde farklı çözünürlük ve FOV boyutlarında anlamlı bir fark yoktu. ($p>0.05$). Sonuç: Görüntü formatı FB'yi değiştirebilir. Periapikal ve panoramik radyografilerde kVp ve mA değişimleri FB'yi büyük ölçüde etkilememektedir. Fraktal analiz, KIBT gibi üç boyutlu görüntülerde değerlendirme yapmak için uygun bir yöntem olmayabilir. Anahtar kelimeler: Fraktal analiz, ışınlama parametreleri, görüntü formatı, dental radyografi, KIBT.

Ethics Committee Approval: The research protocol was approved by the Erciyes University Clinical Research Ethics Committee.

Informed Consent: Not required.

Peer-review: Externally peer-reviewed.

Author contributions: MA, GSS, NE, SY participated in designing the study. MA, GSS, NE, SY participated in generating the data for the study. GSS, SY participated in gathering the data for the study. GSS, NE, SY participated in the analysis of the data. GSS, NE wrote the majority of the original draft of the paper. MA, GSS, NE, SY participated in writing the paper. MA, GSS, NE, SY have had access to all of the raw data of the study. MA, GSS have reviewed the pertinent raw data on which the results and conclusions of this study are based. MA, GSS, NE, SY have approved the final version of this paper. GSS, NE guarantee that all individuals who meet the Journal's authorship criteria are included as authors of this paper.

Conflict of Interest: The authors had no conflict of interest to declare.

Financial Disclosure: The author declared that this study has received no financial support.

Acknowledgments: Authors would like to thank Yeliz KAŞKO ARICI for her contribution.

REFERENCES

- Güngör E, Yildirim D, Çevik R. Evaluation of osteoporosis in jaw bones using cone beam CT and dual-energy X-ray absorptiometry. *Journal of oral science* 2016;58:185-94. [CrossRef]
- Tolga Suer B, Yaman Z, Buyuksarac B. Correlation of Fractal Dimension Values with Implant Insertion Torque and Resonance Frequency Values at Implant Recipient Sites. *International Journal of Oral & Maxillofacial Implants* 2016;31. [CrossRef]
- Geraets W, Van Der Stelt P. Fractal properties of bone. *Dentomaxillofacial Radiology* 2000;29:144-53. [CrossRef]
- Kato CN, Barra SG, Tavares NP, Amaral TM, Brasileiro CB, Mesquita RA, et al. Use of fractal analysis in dental images: a systematic review. *Dentomaxillofacial Radiology* 2020;49:20180457. [CrossRef]
- White SC, Rudolph DJ. Alterations of the trabecular pattern of the jaws in patients with osteoporosis. *Oral Surgery, Oral Medicine, Oral Pathology, Oral Radiology, and Endodontology* 1999;88:628-35. [CrossRef]

6. Bechara B, McMahan CA, Moore WS, Noujeim M, Geha H, Teixeira FB. Contrast-to-noise ratio difference in small field of view cone beam computed tomography machines. *Journal of oral science* 2012;54:227-32. [\[CrossRef\]](#)
7. Ibrahim N, Parsa A, Hassan B, van der Stelt P, Aartman IH, Wismeijer D. The effect of scan parameters on cone beam CT trabecular bone microstructural measurements of the human mandible. *Dentomaxillofacial Radiology* 2013;42:20130206. [\[CrossRef\]](#)
8. Jolley L, Majumdar S, Kapila S. Technical factors in fractal analysis of periapical radiographs. *Dentomaxillofacial Radiology* 2006;35:393-7. [\[CrossRef\]](#)
9. Wilding R, Slabbert J, Kathree H, Owen C, Crombie K, Delpont P. The use of fractal analysis to reveal remodelling in human alveolar bone following the placement of dental implants. *Archives of Oral Biology* 1995;40:61-72. [\[CrossRef\]](#)
10. Shrout MK, Roberson B, Potter BJ, Mailhot JM, Hildebolt CF. A comparison of 2 patient populations using fractal analysis. *Journal of periodontology* 1998;69:9-13. [\[CrossRef\]](#)
11. Shrout M, Hildebolt C, Potter B. The effect of varying the region of interest on calculations of fractal index. *Dentomaxillofacial Radiology* 1997;26:295-8. [\[CrossRef\]](#)
12. Baksi BG, Fidler A. Image resolution and exposure time of digital radiographs affects fractal dimension of periapical bone. *Clinical oral investigations* 2012;16:1507-10. [\[CrossRef\]](#)
13. Pauwels R, Faruangaeng T, Charoenkarn T, Ngonphloy N, Panmekiate S. Effect of exposure parameters and voxel size on bone structure analysis in CBCT. *Dentomaxillofacial Radiology* 2015;44:20150078. [\[CrossRef\]](#)
14. Varma DR. Managing DICOM images: Tips and tricks for the radiologist. *The Indian journal of radiology & imaging* 2012;22:4. [\[CrossRef\]](#)
15. Tan LK. Image file formats. *Biomed Imaging Interv J* 2006;2:e6. [\[CrossRef\]](#)
16. Viswanathan GK, Lotus R. Comparison and analysis of Image File Formats.
17. Toghyani S, Nasseh I, Aoun G, Noujeim M. Effect of image resolution and compression on fractal analysis of the periapical bone. *Acta Informatica Medica* 2019;27:167. [\[CrossRef\]](#)
18. Baksi BG, Fidler A. Fractal analysis of periapical bone from lossy compressed radiographs: a comparison of two lossy compression methods. *Journal of digital imaging* 2011;24:993-8. [\[CrossRef\]](#)
19. Shrout MK, Potter BJ, Hildebolt CF. The effect of image variations on fractal dimension calculations. *Oral Surgery, Oral Medicine, Oral Pathology, Oral Radiology, and Endodontology* 1997;84:96-100. [\[CrossRef\]](#)
20. Yasar F, Apaydin B, Yilmaz H-H. The effects of image compression on quantitative measurements of digital panoramic radiographs. *Medicina oral, patologia oral y cirugia bucal* 2012;17:e1074. [\[CrossRef\]](#)
21. Veenland J, Grashuis J, Gelsema E. Texture analysis in radiographs: the influence of modulation transfer function and noise on the discriminative ability of texture features. *Medical Physics* 1998;25:922-36. [\[CrossRef\]](#)
22. Attaelmanan AG, Borg E, Gröndahl H-G. Signal-to-noise ratios of 6 intraoral digital sensors. *Oral Surgery, Oral Medicine, Oral Pathology, Oral Radiology, and Endodontology* 2001;91:611-5. [\[CrossRef\]](#)
23. Kocasarac HD, Kursun-Cakmak ES, Ustaoglu G, Bayrak S, Orhan K, Noujeim M. Assessment of signal-to-noise ratio and contrast-to-noise ratio in 3 T magnetic resonance imaging in the presence of zirconium, titanium, and titanium-zirconium alloy implants. *Oral surgery, oral medicine, oral pathology and oral radiology* 2020;129:80-6. [\[CrossRef\]](#)
24. Bollen A, Taguchi A, Hujoel P, Hollender L. Fractal dimension on dental radiographs. *Dentomaxillofacial Radiology* 2001;30:270-5. [\[CrossRef\]](#)
25. Tsai M-T, He R-T, Huang H-L, Tu M-G, Hsu J-T. Effect of Scanning Resolution on the Prediction of Trabecular Bone Microarchitectures Using Dental Cone Beam Computed Tomography. *Diagnostics* 2020;10:368. [\[CrossRef\]](#)
26. dos Santos Corpus L, Jacobs R, Quirynen M, Huang Y, Naert I, Duyck J. Peri-implant bone tissue assessment by comparing the outcome of intra-oral radiograph and cone beam computed tomography analyses to the histological standard. *Clinical oral implants research* 2011;22:492-9. [\[CrossRef\]](#)
27. Parsa A, Ibrahim N, Hassan B, Motroni A, Van der Stelt P, Wismeijer D. Influence of cone beam CT scanning parameters on grey value measurements at an implant site. *Dentomaxillofacial Radiology* 2013;42:79884780. [\[CrossRef\]](#)
28. Neves FS, Freitas DQ, Campos PSF, Ekestubbe A, Lofthag-Hansen S. Evaluation of cone-beam computed tomography in the diagnosis of vertical root fractures: the influence of imaging modes and root canal materials. *Journal of endodontics* 2014;40:1530-6. [\[CrossRef\]](#)
29. Schulze R, Heil U, Groß D, Bruellmann D, Dranischnikow E, Schwanecke U, et al. Artefacts in CBCT: a review. *Dentomaxillofacial Radiology* 2011;40:265-73. [\[CrossRef\]](#)
30. Schulze R. Spatial resolution in CBCT machines for dental/maxillofacial applications—what do we know today? 2015.
31. Flaherty T, Tamaddon M, Liu C. Micro-Computed Tomography Analysis of Subchondral Bone Regeneration Using Osteochondral Scaffolds in an Ovine Condyle Model. *Applied Sciences* 2021;11:891. [\[CrossRef\]](#)
32. Min C-K, Kim K-A. Quantitative analysis of metal artefacts of dental implant in CBCT image by correlation analysis to micro-CT: A microstructural study. *Dentomaxillofacial Radiology* 2021;50:20200365. [\[CrossRef\]](#)
33. Kang H-J, Jeong S-W, Jo B-H, Kim Y-D, Kim SS. Observation of trabecular changes of the mandible after orthognathic surgery using fractal analysis. *Journal of the Korean Association of Oral and Maxillofacial Surgeons* 2012;38:96-100. [\[CrossRef\]](#)
34. Bezerra dos Santos LC, Tavares Carvalho AdA, Carneiro Leão J, Duarte Neto PJ, Stosic T, Stosic B. Fractal Measure and Microscopic Modeling of Osseointegration. *International Journal of Periodontics & Restorative Dentistry* 2015;35. [\[CrossRef\]](#)