

## RESEARCH

# Prevalence and Characteristics of Supernumerary Premolars in a Group of Non-Syndromic Turkish Children Between 6-18 Years of Age: A Retrospective CBCT Study

Elif Ballıkaya(0000-0002-1743-1881)<sup>α</sup>, Nagihan Koç(0000-0002-3339-7783)<sup>β</sup>, Merve Kaşıkçı(0000-0003-3211-2093)<sup>γ</sup>

Selcuk Dent J, 2022; 9: 471-478 (Doi: 10.15311/selcukdentj.991041)

Başvuru Tarihi: 04 Eylül 2021  
Yayına Kabul Tarihi: 27 Aralık 2021

### ABSTRACT

#### Prevalence and Characteristics of Supernumerary Premolars in a Group of Non-Syndromic Turkish Children Between 6-18 Years of Age: A Retrospective CBCT Study

**Background:** The prevalence and characteristics of supernumerary premolars in non-syndromic Turkish children between 6-18 years of age was investigated in this retrospective study through CBCT (cone beam computed tomography) analysis.

**Methods:** CBCT images of 48 patients with at least one supernumerary premolar were evaluated in 1012 images of patients referred between 2015 and 2020. The localization, number, eruption state, shape, the position of supernumerary premolar, concomitant other dental anomalies, associated complications, and the presence of resorption on the nearest adjacent teeth were recorded. The statistical analysis of possible associated factors with resorption was performed by the Chi-square test and Logistic regression.

**Results:** The prevalence of supernumerary premolars was 4.7%. A total of 107 supernumerary premolars in 48 patients with mean age of  $15.02 \pm 2.24$  were analyzed. Compared to single supernumerary premolar, multiple supernumerary premolars were more prevalent (62.5%). The concomitant dental anomalies such as pulp stones, mesiodens were observed in fifteen patients (31.2%). Most of the supernumerary premolars were impacted, supplemental shaped and vertical position. The most common complication associated with supernumerary premolars was root resorption (56.4%) of neighborhood teeth. Supernumerary premolars with immature roots induced significantly higher resorption percentages than only crown ones ( $P = 0.002$ ). Also, the root resorption of adjacent teeth due to supernumerary premolars was significantly higher in children over 13 years of age ( $P < 0.001$ ).

**Conclusion:** The prevalence and three-dimensional radiographic characteristics of supernumerary premolars in non-syndromic Turkish children offer valuable information to the literature and highlight the possible complications.

### KEYWORDS

Cone Beam Computed Tomography; Supernumerary Premolars; Complications, Root Resorption; Children

### ÖZ

#### 6-18 Yaş Arası Sendromik Olmayan Bir Grup Türk Çocuklarında Süpernumere Premolarların Prevalansı ve Özellikleri: Retrospektif Bir KIBT Çalışması

**Amaç:** Bu retrospektif çalışmada 6-18 yaş arası sendromik olmayan Türk çocuklarında süpernumere premolarların prevalansı ve özellikleri KIBT (konik ışınli bilgisayarlı tomografi) analizi ile araştırılmıştır.

**Gereç ve Yöntemler:** 2015 ve 2020 yılları arasında sevk edilen 1012 hasta görüntülerinden en az bir süpernumere premoları olan 48 hastanın KIBT görüntüleri değerlendirilmiştir. Süpernumere premoların bölgesi, sayısı, sürme durumu, şekli, konumu, eşlik eden diğer dental anomaliler, ilişkili komplikasyonlar ve en yakın komşu dişlerde rezorbsiyon varlığı kaydedilmiştir. Rezorbsiyonla ilişkili olası faktörlerin istatistiksel analizi, Ki-kare testi ve Lojistik regresyon ile yapılmıştır.

**Bulgular:** Süpernumere premolarların prevalansı %4,7'dir. Ortalama yaşı  $15.02 \pm 2.24$  olan 48 hastada toplam 107 süpernumere premolar diş analiz edilmiştir. Tek sayıda süpernumere premolar ile karşılaştırıldığında, çoklu süpernumere premolarlar daha yaygındır (%62,5). Süpernumere premoları olan on beş hastada (%31,2), eşlik eden pulpa taşı, mesiodens gibi dental anomaliler görülmüştür. Süpernumere premolarların çoğu gömülü, suplemental şekilli ve dikey konumdadır. Süpernumere premolarlarla ilişkili en yaygın komplikasyonlar kök rezorbsiyonudur (%56,4). Olgunlaşmamış köklere sahip süpernumere küçük azılar, yalnızca kron kısmı olanlara göre önemli ölçüde daha fazla rezorbsiyon yüzdelere neden olmuştur ( $P = 0,002$ ). Ayrıca, süpernumere küçük azı dişleri nedeniyle gelişen komşu dişlerde kök rezorbsiyonu 13 yaşın üzerindeki çocuklarda önemli ölçüde daha yüksektir ( $P < 0,001$ ).

**Sonuç:** Sendromik olmayan Türk çocuklarında süpernumere premolarların prevalansı ve üç boyutlu radyografik özellikleri literatüre değerli bilgiler sağlamak ve olası komplikasyonları vurgulamaktadır.

### ANAHTAR KELİMELE

Konik Işınli Bilgisayarlı Tomografi, Süpernumere Küçük Azı Dişleri, Komplikasyonlar, Kök Rezorbsiyonu, Çocuklar.

## INTRODUCTION

The term of supernumerary describes the teeth consisting in addition to normal dentition.<sup>1</sup> Supernumerary teeth (ST) are frequently discerned

when a failure was observed in tooth eruption. The exact etiology of the supernumerary teeth was not clarified entirely. This developmental anomaly may appear in children with syndromes such as Cleidocranial dysplasia, Gardner's syndrome, cleft of the lip and palate, and also

<sup>α</sup> Hacettepe University Faculty of Dentistry, Department of Pediatric Dentistry, Ankara, Turkey

<sup>β</sup> Hacettepe University, Faculty of Dentistry, Department of Dentomaxillofacial Radiology, Ankara, Turkey

<sup>γ</sup> Hacettepe University, Department of Biostatistics, Ankara, Turkey

in cases regardless of the systemic disorders.<sup>2</sup>

This anomaly may occur in both primary and permanent dentition but more frequently in permanent dentition and also in males compared to females. The classification of supernumeraries according to the location includes mesiodens, parapremolars, paramolars, and distomolars. While mesiodens teeth were asserted most frequently in the literature,<sup>3,4</sup> the parapremolar teeth was reported by Öztaş et al.<sup>5</sup> as the most common supernumerary with a prevalence of 1.6%, in a Turkish population.<sup>5</sup> A supernumerary tooth located in premolar region is defined as parapremolar. Parapremolars were observed more commonly in the mandible, and three times more frequently in males compared to females, which indicates sex-linked inheritance.<sup>2</sup> Distribution can be single or multiple, unilaterally or bilaterally<sup>6</sup> and the development of supernumerary premolar (SP) may be observed around 12-13 years of age.<sup>7</sup>

Although supernumerary teeth are usually noticed incidentally during the radiographic examination, they may result in some complications such as failure of eruption, rotation, displacement, crowding, diastema and cyst formation.<sup>3,6</sup> Removal or follow-up of a supernumerary tooth should be considered depending on the risk of complication to the adjacent structures.<sup>8,9</sup> The treatment planning and ideal timing for surgery are also based on the location within the dental arch, and eruption status of supernumerary teeth.<sup>10</sup>

Proper clinical and radiographic evaluation is essential to decide the best management approach. Cone-beam computed tomography (CBCT) imaging provides proper diagnostic accuracy and spatial relationships with adjacent teeth due to three-dimensional view compared to conventional panoramic images.<sup>6,11</sup> It offers suitable information for treatment planning and surgical operation. The limited numbers of CBCT studies on SPs are present in the literature.<sup>3,6</sup>

The present study aims to consider the characteristics of SPs in Turkish children and teens and, the possible complications induced by SPs, utilizing CBCT imaging.

## MATERIALS AND METHODS

### Sample Selection

The retrospective study was performed following the approval by Research Ethics Board of Hacettepe University (GO20/1179). A sample of 1698 CBCT images of the patients aged 6 to 18 years referred between January 2015 and June 2020 were initially selected from the database of the Department of Dentomaxillofacial Radiology. The presence of one or more SP teeth was the sole inclusion criterion. Patients with maxillofacial anomalies, previously diagnosed syndromes, and with a history of prior extraction of supernumerary teeth were not included. CBCT images with poor image quality were also excluded. The final sample consisted of 1012 scans.

### CBCT Protocol and Image Evaluation

CBCT scans were obtained by using an i-Cat Next Generation device (Imaging Sciences International, Hatfield, PA, USA) with the following protocol: 120 kVp, 3–8 mA, 0.20-mm voxel, and 26-s scan time. The CBCT scans were evaluated simultaneously by two examiners (E.B. and N.K.) using i-CAT Vision software (Imaging Sciences, Hatfield, PA, USA) with a 24-inch LCD monitor (1920 × 1080 resolution, Dell, Round Rock, USA) under optimal conditions. The presence of supernumerary teeth was evaluated on axial, coronal, and sagittal multiplanar reconstruction planes (MPR).

### Parameters

Demographic variables were recorded for each patient with SP. Number, jaw localization (maxilla, mandible, both), type of occurrence (unilateral, bilateral, ipsilateral, contralateral), shape (supplemental, conical, atypical, tuberculate), position (vertical, inclined, transvers, horizontal), location (bucco-oral, vertical), development stage (crown formation, immature root formation, mature root formation), eruption status (impacted, partially erupted, erupted), concomitant dental anomalies (supernumerary teeth, pulp stone, supernumerary teeth&pulp stones, dens invaginatus), and associated pathologies or complications (delayed eruption of adjacent teeth, impacted permanent teeth, malocclusion, crowding, diastema, displacement, rotation, dilacerations, follicular enlargement (>3 mm), root resorption (RR) of adjacent tooth were evaluated. Location (cervical, middle, or apical third of the root) and degree of RR (slight, moderate, severe) and the closest distance (mm) between the SP and the nearest adjacent tooth were also assessed.

### Statistical Analysis

Statistical analyses were performed by using SPSS software version 22.0 (SPSS, Inc., Chicago, IL, USA). Data were expressed by frequencies and percentages. Chi-square test was performed to assess the significance of the differences between categorical variables. The level of significance was set at  $P < 0.05$ . Multiple logistic regression analysis was used to determine whether an independent variable remained statistically significant after controlling for other confounding variables. Based on the results of the univariate analyses, independent variables with  $p$ -value  $< 0.1$  included in the regression model. Risk estimates were presented as odds ratios (ORs) with 95% confidence intervals (CIs).

## RESULTS

Among the 1012 CBCT scans, 107 SPs were found in 48 patients (4.7%). The patients were comprised of 27 males and 21 females, which gives a ratio of 1.28:1.

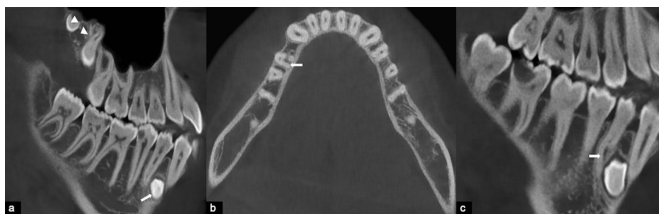The average number of supernumerary premolars per person was 2.2. The mean age of the sample was  $15.02 \pm 2.24$  years (age range, 6-18 years). Table 1 shows the characteristics of SPs. Single SP was found in 18 patients (37.5%) whereas 30 patients (63.5%) had two or more SPs. The majority of SPs were bilateral (26, 54.2%). The mandible was the most common location ( $n=33$ ). The most frequently observed morphological type of SP was supplemental (100, 93.5%), followed by conical (4, 3.7%) and atypical (3, 2.8%). Tuberculate SP was not detected. The majority of SPs were impacted ( $n=101$ ). Of the total SPs, most ( $n=63$ ) had an immature or partial root stage, while 42 had only crown formation. Only two SPs were considered as fully developed. In 68.8% ( $n=33$ ) of the SPs, no concomitant dental anomalies were detected. Among the 15 dental anomalies, the presence of concomitant ST ( $n=6$ ) was the most common finding (Fig. 1a). The majority of SPs ( $n=88$ ) were in the vertical position.

When the clinical complications associated with SPs were assessed (Figs. 1-4), RR of adjacent permanent tooth was the predominant finding with an occurrence in 57 out of 107 cases (Table 2). The most common location for RR was middle third of the root ( $n= 33$ ), while the degree of resorption was mostly slight ( $n= 40$ ). A significant number of SPs ( $n= 75$ ) were in close contact to the nearest adjacent permanent tooth.

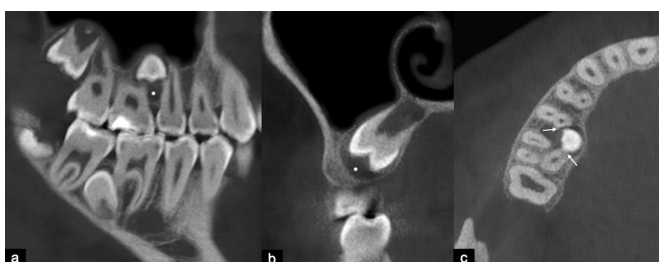
**Table 1. The Characteristics of Supernumerary Premolars**

Characteristics	n	%
<b>Sex</b>		
Male	27	56.3
Female	21	43.8
<b>Number (n=48)</b>		
Single	18	37.5
Two	16	33.3
Three	4	8.3
Four	6	12.5
Five	4	8.3
<b>Type of occurrence (n=48)</b>		
Unilateral	19	39.6
Bilateral	26	54.2
Ipsilateral	1	2.1
Contralateral	2	4.2
<b>Localization (n=48)</b>		
Maxillary	4	8.3
Mandibular	33	68.8
Both	11	22.9
<b>Concomitant dental anomaly (n=48)</b>		
Absent	33	68.8
Present	15	31.2
Supernumerary	6	12.5
Pulp stone	4	8.3
Supernumerary & pulp stones	4	8.3
Dens invaginatus	1	2
<b>Eruption status (n=107)</b>		
Impacted	101	94.4
Partially erupted	3	6.3
Erupted	3	6.3
<b>Shape (n=107)</b>		
Supplemental	100	93.5
Conical	4	3.7
Atypical	3	2.8
Tuberculate	-	-
<b>Position (n=107)</b>		
Vertical	88	82.2
Inclined	15	14.0
Transverse	3	2.8
Horizontal	1	0.9
<b>Location (vertical) (n=107)</b>		
Apical to the root tip	3	2.8
Apical third of the root	19	17.8
Middle third of the root	55	51.4
Cervical third of the root	14	13.1
Coronal	16	15.0
<b>Location (bucco-oral) (n=107)</b>		
Buccal	-	-
Median/within arch	43	40.2
Palatal/lingual	64	59.8
<b>Development stage (n=107)</b>		
Only crown	42	39.3
Immature root	63	58.9
Mature root	2	1.9

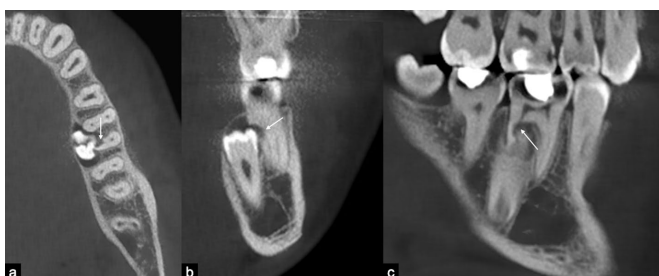Characteristics	n	%
<b>Sex</b>		
Male	27	56.3
Female	21	43.8
<b>Number (n=48)</b>		
Single	18	37.5
Two	16	33.3

**Figure 1**

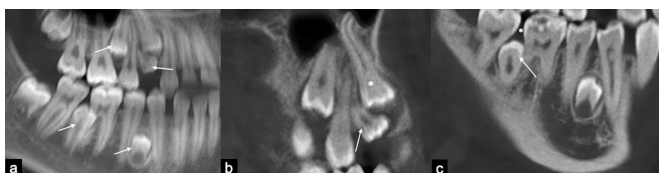
Cone-beam computed tomography images of a patient with multiple supernumerary teeth. Corrected sagittal (a) section showing mandibular supernumerary premolar (arrow), maxillary distomolars (arrowheads), and pulp stones involving several permanent teeth. Axial (b) and corrected sagittal (c) sections showing mandibular first premolar with atypical root formation (arrow) associated with impacted supernumerary premolar.

**Figure 2**

Cone-beam computed tomography images of a patient with multiple supernumerary premolars. Corrected sagittal (a) and coronal (b) sections showing maxillary supernumerary premolar with follicular enlargement (asterisk). Axial (c) section showing root resorption (arrows) in adjacent maxillary premolar and molar teeth associated with impacted supernumerary premolar.

**Figure 3**

Axial (a), coronal (b), and sagittal (c) cone-beam computed tomography sections showing root resorption (arrow) in mandibular first molar associated with impacted supernumerary premolar.

**Figure 4**

Panoramic (a) cone-beam computed tomography image of a patient with multiple supernumerary premolars (arrows). Sagittal (b) section showing maxillary supernumerary premolar (arrow) associated with the impaction of maxillary first premolar (asterisk). Corrected sagittal (c) section showing a diastema between mandibular molars (asterisk) associated with the impacted supernumerary premolar (arrow).

**Table 2.**

### The Characteristics of Clinical Complications Associated With Supernumerary Premolars

Complications (n=107)	n	%
Root resorption of adjacent tooth	57	53.3
Rotation	28	26.1
Malocclusion	23	21.5
Diastema	17	15.9
Displacement	14	13.1
Delayed eruption of adjacent teeth	14	13.1
Impacted permanent teeth	9	8.4
Dilaceration	8	7.5
Follicular enlargement (> 3 mm)	6	5.6
Crowding	4	3.7
<b>Location of resorption (n=57)</b>		
Apical third of the root	19	33.3
Middle third of the root	33	57.9
Cervical third of the root	5	8.8
<b>Severity of resorption (n=57)</b>		
Slight (up to half of the dentine thickness to the pulp)	40	70.2
Moderate (resorption midway to the pulp or more, the pulp lining being unbroken)	10	17.5
Severity (the pulp is exposed by the resorption)	7	12.3
<b>Proximity to the nearest adjacent tooth (n=107)</b>		
0 mm	75	70.0
< 0.5 mm	30	28.1
> 0.5 mm	2	1.9

Table 3 shows the association between RR of adjacent permanent teeth and other parameters. The prevalence of RR was higher in cases of SPs with partial or complete root formation than in those with only crown formation ( $P = 0.002$ ). Considering the vertical location of SPs, a higher prevalence of RR was observed in cases of SPs located in the middle third of the root of the adjacent tooth compared to cases of SPs located in the coronal region of the adjacent tooth ( $P = 0.048$ ). RR was also associated with the bucco-oral position of the SPs: a higher prevalence of RR was detected in cases of SPs within arch or with a median location than in those with palatal/lingual location ( $P = 0.005$ ). RR was more common in patients aged over 12 years than in patients aged between 9-12 years ( $P < 0.001$ ). Jaw localization, shape, or position/inclination of SPs was not significantly associated with the prevalence of RR ( $P = 0.546$ ,  $P = 0.281$ , and  $P = 0.337$ , respectively). Logistic regression analysis showed that patients aged over 12 years (OR: 8.05) and SPs with bucco-oral position (OR: 3.68) had increased risk for the presence of RR in adjacent teeth (Table 4;  $P = 0.016$  and  $P = 0.006$ , respectively). SPs with partial or complete root formation also showed an increased risk for RR but not within the significance level ( $P = 0.067$ ).

**Table 3.****The Association Between Root Resorption of Adjacent Permanent Teeth and Other Parameters**

		Root resorption			P value
		Absent n (%)	Present n (%)	Total	
Development stage	Only crown	28 (66.7)	14 (33.3)	42	0.002
	Immature root	21 (33.3)	42 (66.7)	63	
	Mature root	1 (50.0)	1 (50.0)	2	
Shape	Supplemental	45 (45.0)	55 (55.0)	100	0.281
	Conical	2 (50.0)	2 (50.0)	4	
	Atypical	3 (100.0)	0 (0.0)	3	
Localization	Maxilla	13 (52.0)	12 (48.0)	25	0.546
	Mandible	37 (45.1)	45 (54.9)	82	
Position	Vertical	42 (47.7)	46 (52.3)	88	0.337
	Inclined	8 (53.3)	7 (46.7)	15	
	Transverse	0 (19.2)	3 (80.8)	3	
	Horizontal	0 (34.4)	1 (65.6)	1	
Location (vertical)	Apical to the root tip	1 (33.3)	2 (66.7)	3	0.048
	Apical third of the root	9 (47.4)	10 (52.6)	19	
	Middle third of the root	21 (38.2)	34 (61.8)	55	
	Cervical third of the root	6 (42.9)	8 (57.1)	14	
	Coronal	13 (81.3)	3 (18.8)	16	
Location (bucco-oral)	Median/within arch	13 (30.2)	30 (69.8)	43	0.005
	Palatal/lingual	37 (57.8)	27 (42.2)	64	
Age	9-12 years	15 (88.2)	2 (11.8)	17	< 0.001
	> 12 years	35 (38.9)	55 (61.1)	90	

**Table 4.****Logistic Regression Analysis of Variables Associated With Root Resorption of Adjacent Permanent Teeth**

		Odds ratio	95% (CI)	P value
Age	> 12 years	8.05	1.48–43.72	0.016
	9-12 years	.	.	.
Location (bucco-oral)	Median/within arch	3.68	1.46–9.29	0.006
	Palatal/lingual	.	.	.
Development stage	Immature root	2.45	0.94–6.41	0.067
	Only crown	.	.	.

**DISCUSSION**

One hundred and seven non-syndromic supernumerary premolars of 48 patients among the CBCT images of 1012 Turkish patients aged between 6-18 years were examined in the present study.

Bereket et.al.<sup>12</sup> observed 222 supernumerary premolars in 146 patients (1.3%) out of 111.293 patients in a retrospective study which they conducted on panoramic images of the Turkish population with a mean age of 22.71. Similarly, Celikoglu et al.<sup>4</sup> reported the prevalence of all supernumerary teeth as 1.2% in 3491 Turkish patients aged from 12 to 25. Esenlik et al.<sup>13</sup> reported the frequency of supernumerary teeth as 2.7% among 2599 panoramic images of Turkish patients with a mean age of 8.6. Among all ST, supernumerary premolars were only present in 17 patients (0.06%) and were more prevailed in the mandible. Compared to these studies, the prevalence of non-syndromic supernumerary premolars (4.7%) in the present study was more frequent. The presence of supernumerary premolars could be the indication for the CBCT imaging in the present study, which may probably lead to a relatively higher prevalence.

Almost two-thirds of patients had multiple supernumerary premolars (62.5%) in the present study. The average number of supernumerary premolars per person was 2.2, which was higher than the previous studies.<sup>3,6</sup> In the present study, the most common jaw for supernumerary premolars was mandible (68.8% only in mandible, 8.3% only in maxilla) which was also corroborated with previous studies.<sup>14,15</sup> Supernumerary premolars appear more frequently in the mandible contrary to other supernumerary teeth and those are the most common supernumerary teeth in the mandible.<sup>2,3,14</sup>

In line with the findings of previous studies conducted on all supernumerary teeth,<sup>3,6,13</sup> the supernumerary premolars were also more common in males than females with a ratio of 1.28:1 in the present study.

In 100 supernumerary premolars (93.5%), the supplemental shape was apparent. Similarly, González et al.<sup>14</sup> reported that 90.4% of the 73 supernumerary premolars had supplemental morphology. Mossaz et al.<sup>3</sup> and Jiang et al.<sup>6</sup> used CBCT imaging for evaluating the supernumerary teeth and they reported that 70.8% and 70.43% of the premolars showed supplemental morphology, respectively. This discrepancy may result from the differences in the sample size, and the classification of morphology. Unlike the atypical morphology, the classification of developing tooth buds was present in their study. Although the developing tooth buds were not encountered in the present study, premolars with only entire crown development were recorded within the development stage parameters.

Supernumerary teeth may either lead to some complications in the adjacent teeth like delayed eruption, displacement, root resorption, rotation, cyst formation or can remain asymptomatic.<sup>14</sup> These adverse effects of supernumerary teeth and the root development of the adjacent teeth were considered in the literature to determine the necessity, and the ideal time point of surgical removal.

According to Garvey et al.,<sup>1</sup> if an associated complication, eruption of supernumerary teeth, or constituting an interference for orthodontic treatment has happened, surgical removal of the supernumerary is required. Here, more than half of the supernumerary premolars (53.2%) were associated with root resorption of adjacent teeth. Although many of the resorptions were observed at a slight level, seven of them exposed the dental pulp. Similarly, 15 of 24 supernumerary premolars (62.5%) caused root resorption of adjacent teeth in the study of Mossaz et al.<sup>3</sup> Among all supernumerary teeth, Jiang et al.<sup>6</sup> detected root resorption of adjacent teeth most frequently related to supernumerary premolars. When possible associated factors of resorption were evaluated with logistic regression analysis in the present study, supernumerary premolars of patients over 12 years of age had an 8.047-fold higher risk for root resorption than patients with 9-12 years of age.

Additionally, the development stage of supernumerary premolar showed that the immature root stage had 2.451 times higher risk for root resorption than the only crown stage. Similarly, Park et al.<sup>9</sup> evaluated the complications associated with specific characteristics of supernumerary teeth and they concluded that an increased patient age or the direction of the eruption of supernumerary teeth were associated with complications. The direction of supernumerary premolars was not analyzed in the present study since most of the supernumerary premolars were in the vertical direction but the bucco-oral position of supernumerary premolars was evaluated in the present study as in the study of Jiang et al.<sup>6</sup> They observed that many of the supernumerary premolars (167, 87.4%) were significantly located palatally/lingually but they did not report the association of location by resorption resulting from supernumerary premolars. Furthermore, they found no association between the bucco-oral position and resorption due to supernumerary teeth. The prevalence of resorption of adjacent teeth originated from all supernumerary teeth was also lower (n=43, 3.7%) in their study. However, supernumerary premolars located within the alveolar arch caused a 3.680-fold higher risk of root resorption of adjacent teeth than palatally/lingually located supernumeraries in the present study. These complications and bucco-oral position are critical for deciding a surgical removal of supernumerary premolars. CBCT imaging ensures a 3D view and a better diagnostic accuracy for assessing all these critical factors.

In previous studies, an enlarged dental follicle along with the pressure of the erupting supernumerary teeth described as being the possible reason for root resorption of adjacent teeth.<sup>16</sup> However, Ericson et al.<sup>17</sup> explained the etiology of root resorption due to an ectopic eruption as only the direct physical contact of the ectopic and the impacted canine tooth with the neighborhood permanent teeth, and consequently consisting pressure. Mossaz et al.<sup>3</sup> reported that follicle enlargement, the proximity of supernumerary to adjacent teeth were associated with the presence of root resorption. They recommended that the results of their study should be handled considering the low sample size. Herein, only two supernumerary premolars were more than 0.5 mm in distance to the nearest adjacent teeth and only 6 supernumeraries had enlarged dental follicles. Therefore, these variables were not analyzed in the present study.

Aside from complications, concomitant dental anomalies such as supernumeraries in other parts of the jaws, pulp stones, dens invaginatus were detected in 15 patients (31.2%) herein. In the literature, supernumerary teeth and pulp stones were reported in the clinical intraoral manifestations of

Ehler Danlos Syndrome.<sup>18</sup> In the present study, pulp stone which is also one of the dental hard tissue anomalies, were accompanied in 8 healthy patients with supernumerary premolars. Genetic aspects of multiple dental hard tissue anomalies should be evaluated in future studies.

The prevalence of supernumerary premolars should be evaluated within the limitations of this study. Here, the presence of the supernumeraries is also one of the indications for CBCT imaging and this may lead to a relatively higher prevalence compared to the previous studies on panoramic images. However, the large sample size of the supernumerary premolars may contribute to the literature in terms of their characteristics, and associated complications. CBCT imaging of supernumerary premolars ensured multifaceted assessments such as the measuring of the proximity to adjacent teeth, the level of resorption, and bucco-oral position. With logistic regression analysis, some factors associated with resorption were able to be established. The obtained results point to the significance of early diagnosis and timely intervention of supernumerary premolars.

### **CONCLUSIONS**

- Non-syndromic supernumerary premolars were not uncommon in a group of the young Turkish population.
- Multiple supernumerary premolars and a high prevalence of root resorption of adjacent teeth were observed.
- The patient age, development stage, and median position of supernumerary premolar were associated with root resorption. Other supernumerary teeth like mesiodens, and pulp stones were also detected in some patients with supernumerary premolars.

## REFERENCES

1. Garvey MT, Barry HJ, Blake M. Supernumerary teeth-an overview of classification, diagnosis and management. *J Can Dent Assoc* 1999; 65: 612-616.
2. Solares R, Romero MI. Supernumerary premolars: a literature review. *Pediatr Dent* 2004; 26: 450-458.
3. Mossaz J, Kloukos D, Pandis N, Suter VG, Katsaros C, Bornstein MM. Morphologic characteristics, location, and associated complications of maxillary and mandibular supernumerary teeth as evaluated using cone beam computed tomography. *Eur J Orthod* 2014; 36: 708-718.
4. Celikoglu M, Kamak H, Oktay H. Prevalence and characteristics of supernumerary teeth in a non-syndromic Turkish population: associated pathologies and proposed treatment. *Med Oral Patol Oral Cir Bucal* 2010; 15: 575-8.
5. Öztaş B, Bardak Ç, Kurşun EŞ, Akbulut N. Clinical characteristics of non-syndromic supernumerary teeth in a cohort of Turkish patients. *Oral Radiol* 2011; 27: 108-113.
6. Jiang Y, Ma X, Wu Y, et al. Epidemiological, clinical, and 3-dimensional CBCT radiographic characterizations of supernumerary teeth in a non-syndromic adult population: a single-institutional study from 60,104 Chinese subjects. *Clin Oral Investig* 2020; 24: 4271-4281.
7. Paduano S, Rongo R, Lucchese A, Aiello D, Michelotti A, Grippaudo C. Late-developing supernumerary premolars: analysis of different therapeutic approaches. *Case Rep Dent* 2016; 2016: 1-8.
8. Gupta S, Goswami M. Asymptomatic nonsyndromic multiple supernumerary premolars. *Int J Clin Pediatr Dent* 2012; 5: 84-6.
9. Park S-Y, Jang H-J, Hwang D-S, et al. Complications associated with specific characteristics of supernumerary teeth. *Oral Surg Oral Med Oral Pathol Oral Radiol* 2020; 130: 150-155.
10. Amaral D, Muthu M. Supernumerary teeth: Review of literature and decision support system. *Indian J Dent Res* 2013; 24: 117-122.
11. Kapila S, Conley R, Harrell Jr W. The current status of cone beam computed tomography imaging in orthodontics. *Dentomaxillofac Radiol* 2011; 40: 24-34.
12. Bereket C, Çakır-Özkan N, Şener İ, Bulut E, Baştan A. Analyses of 1100 supernumerary teeth in a nonsyndromic Turkish population: A retrospective multicenter study. *Niger J Clin Pract* 2015; 18: 731-738.
13. Esenlik E, Sayın MÖ, Atilla AO, Özen T, Altun C, Başak F. Supernumerary teeth in a Turkish population. *Am J Orthod Dentofacial Orthop* 2009; 136: 848-852.
14. Martiánez-González JM, Brinkmann JC-B, Calvo-Guirado JL, Arias-Irímia O, Barona-Dorado C. A clinical epidemiologic analysis of a sample of 73 supernumerary premolars. *J Am Dent Assoc* 2010; 141: 1435-1441.
15. De Oliveira Gomes C, Drummond SN, Jham BC, Abdo EN, Mesquita RA. A survey of 460 supernumerary teeth in Brazilian children and adolescents. *Int J Clin Pediatr Dent* 2008; 18: 98-106.
16. Bidwell JP, Fey EG, Marks Jr SC. Nuclear matrix-intermediate filament proteins of the dental follicle/enamel epithelium and their changes during tooth eruption in dogs. *Arch Oral Biol* 1995; 40: 1047-1051.
17. Ericson S, Bjerklín K, Falahat B. Does the canine dental follicle cause resorption of permanent incisor roots? A computed tomographic study of erupting maxillary canines. *Angle Orthod* 2002; 72: 95-104.
18. Létourneau Y, Pérusse R, Buithieu H. Oral manifestations of Ehlers-Danlos syndrome. *J Can Dent Assoc* 2001; 67: 330-334.

## Corresponding Author:

Elif Ballıkaya, DDS  
 Department of Pediatric Dentistry, Faculty of Dentistry,  
 Hacettepe University Sıhhiye, 06100  
 Ankara, Turkey  
 E-mail : eyildirim@hacettepe.edu.tr