

Unusual origin of three headed biceps brachii muscle

Danielle Reilly, Srinath Kamineni

Department of Orthopaedic Surgery, University of Kentucky, Lexington, KY, USA

Abstract

The biceps brachii is one of the most variable muscles in the human body in terms of the number of heads contributing to the muscle. The most common origin of these supernumerary heads is along the humeral shaft. We document a previously unreported point of origin for a supernumerary head. Routine dissection of a 10% formalin fixed upper extremity of a 72 year old Caucasian male, revealed a tripital biceps brachii muscle. The third head took its origin from the deep investing fascia of the brachialis muscle and inserted onto the tendon of the short head of the biceps brachii. We believe this to be a previously unreported point of origin for a supernumerary head of the biceps brachii muscle. Supernumerary heads become clinically important as they can be a source of confusion for surgeons operating in this region and may be mistaken for soft tissue tumors when they are unilateral. An understanding of such variations is important.

Keywords: biceps third head; elbow; shoulder; supernumerary biceps brachii

Anatomy 2015;9(2):94–99 ©2015 Turkish Society of Anatomy and Clinical Anatomy (TSACA)

Introduction

The biceps brachii is located in the flexor compartment of the arm and is classically described as a large, fusiform muscle with two heads.^[1] The short head takes its origin from the lateral coracoid apex along with the coracobrachialis.^[1–3] The long head is a long thin tendon which originates from the supraglenoid tubercle within the shoulder capsule, and is an intra-articular structure.^[1] This tendon is surrounded by a double tubular sheath which is an extension of the shoulder capsule, and distally courses over the humeral head, exiting the joint deep to the transverse humeral ligament.^[1,4] These two heads form elongated muscle bellies that are adherent to each other, but can be easily separated from one another until about 7 cm proximal to the elbow joint, where they amalgamate into a common tendon.^[1] This common tendon twists about its long axis before it inserts onto the bicipital tuberosity of the proximal radius.^[1] If the fibers of the tendon are dissected out at its insertion, it becomes apparent that the anterior fibers are from the short head and the posterior ones are from the long head.^[1] A bursa separates the tendon from the anterior

radial tuberosity which allows the tendon to glide smoothly over it during forearm pronation and supination.^[1,5] The distal tendon also has a medial expansion that forms the bicipital aponeurosis or lacertus fibrosus which extends medially covering the brachial artery and joins the deep fascia of the forearm flexors.^[1,3,4]

Variations in the morphology and number of biceps brachii are well reported and have been recognized since the 19th century, making it one of the most variable muscles in the body in this respect.^[6–8] A tripital muscle is the most frequently reported variation, however, up to six heads have been reported.^[3,6,8–11] There is a wide variety of points of origin for these accessory heads as well. The most commonly reported third head originates from the humerus between the insertion of the coracobrachialis muscle and the origin of the brachialis muscle.^[2,3,6,7,9,10,12–20] Other origins can include the tendons or fascia of the neighboring muscles (deltoid, pectoralis major, pronator teres, brachioradialis and medial triceps), the intermuscular septum, the shoulder capsule itself, the neck, lesser tuberosity or the anteromedial surface of the humerus.^[4,6,8–10,14,16–18,20–29] The insertion of these

accessory heads can be just as variable as their origins. The current literature reports them inserting into the individual muscle bellies of the normal long and short heads, into a common muscle belly, the common tendon or onto the bicipital aponeurosis.^[2,3,6-10,12,14-16,18-20,22,23,26,28,30,31]

There have been multiple population based studies which attempt to determine the prevalence of supernumerary heads. The overall prevalence has traditionally been reported as 10% in white Europeans, 12% in black Africans, 8% in Chinese and 18% in Japanese populations.^[1,3,6] Significant differences between populations have been identified, but the data can vary widely between studies of the same population and trends based on race are difficult to identify (**Table 1**). For example, one study found that a third head of the biceps was more frequent in South African blacks than whites, but was absent in those of Zulu ancestry.^[32] Supernumerary heads appear to be distributed evenly between right and left limbs and a higher incidence in males has been reported in some studies.^[6,32,33] The incidence of bilaterally symmetric supernumerary heads is also variable between studies and has been reported to be between 3.3% and 29.3%.^[9,17,19,22,32,34,35]

All reported supernumerary heads of the biceps brachii are innervated by the musculocutaneous nerve,^[10,12,13,16,22,23,28,30,33-35] with the rare exceptions where accessory heads are innervated by the median nerve.^[24,36]

However, the presence of supernumerary head of the biceps are also frequently associated with musculocutaneous nerve variations which include anything from the absence of the nerve, to unique branching patterns, to duplication.^[8,12,13,22,24,34,35] Le Double hypothesized in 1897 that the altered muscle anatomy was responsible for the anomalous route of the nerve, however, Lee reports statistical analysis that the two variations develop independently.^[8,37]

Case Report

During routine dissection of a 72 year old male cadaver in our lab, a tricipital biceps brachii was noted. A well-developed muscular slip was observed to originate from the anterior deep investing fascia of the brachialis muscle (**Figures 1 and 2**). This muscle belly continued distally as an individual tendon and this tendon joined with the short head of the biceps brachii, before inserting onto the radial tuberosity. The musculocutaneous nerve was deep to this third head of the biceps and gave off small branches to this accessory muscle.

To our knowledge, this is the first report of a third head of the biceps solely originating from the fascia of the brachialis muscle. Poudel et al.^[18] mention that supernumerary heads may arise from the brachialis muscle, however, this origin was not noted in Poudel’s study of the Nepalese population. Two authors report cases of an accessory head primarily originating from the anterome-

Table 1
Summary of population prevalence studies of supernumerary heads of the biceps brachii muscle.

First Author (Year)	Population	No. Arms examined	No. arms with supernumerary heads (%)	No Cadavers Dissected	No. cadavers with supernumerary heads (%)
Santo Neto (1998)	Brazilian white	100	20 (20%)	-	-
	Brazilian black	100	9 (9%)	-	-
Kosugi (1992)	Japanese	546	75 (13.7%)	273	58 (21.2%)
Nakatani (1998)	Japanese	50	6 (12%)	25	4 (16%)
Asvat (1993)	South African white	24	1 (4.2%)	12	1 (8.3%)
	South African black	146	24 (16.4%)	73	15 (20.5%)
Nayak (2005)	Indian	96	2 (2.1%)	48	1 (2.1%)
Rai (2007)	Indian	84	3 (3.6%)	42	3 (7.1%)
Khaledpour (1985)	European	152	1 (0.7%)	76	1 (1.3%)
	Iranian	400	1 (0.3%)	200	1 (0.5%)
Poudel (2009)	Nepalese	32	4 (12.5%)	16	2 (12.5%)
Paraskevas (2008)	Greek	112	2 (1.8%)	56	2 (3.6%)
Kervancioglu (2011)	Turkish fetuses	24	2 (8.3%)	12	2 (16.7%)
Kopuz (1999)	Turkish neonates	120	20 (16.7%)	60	11 (15%)
	Turkish adults	40	4 (10%)	20	2 (10%)
Rodriguez-Niedenfuhr (2003)	-	350	32 (9.1%)	175	27 (15.4%)

dial humerus just lateral to the brachialis and that this head had some fibers originating from the fascia surrounding the brachialis muscle.^[16,25] Extensive literature search did not find any case reports of a third head only arising from the brachialis fascia as seen in our specimen.

Discussion

Supernumerary heads of the biceps brachii are a well-documented anatomic variation. Studies of comparative anatomy, especially of the gibbon and orangutan, have lead anatomists to hypothesize that the variation results from a remnant of an additional head of the coracobrachialis muscle which is seen in these animals, and that it regressed as humans transitioned to upright walking, relying less on the upper extremities for weight bearing.^[8,38,39]

Two relatively large studies have categorized the origins and insertions of supernumerary heads in an attempt to identify the most frequent variations. Rodriquez-Niedenfuhr et al.^[11] identified three different points of origin: superior, infero-lateral, and infero-medial. Their data is summarized in **Table 2**. These authors propose that case reports of up to seven biceps brachii heads are combinations of the superior, infero-lateral and infero-medial origins with duplication of the long or short heads.^[11] Our specimen does not fit into this classification system. The other classification system, summarized in **Table 3**, was proposed by Kosugi et al.^[34] They grouped supernumerary

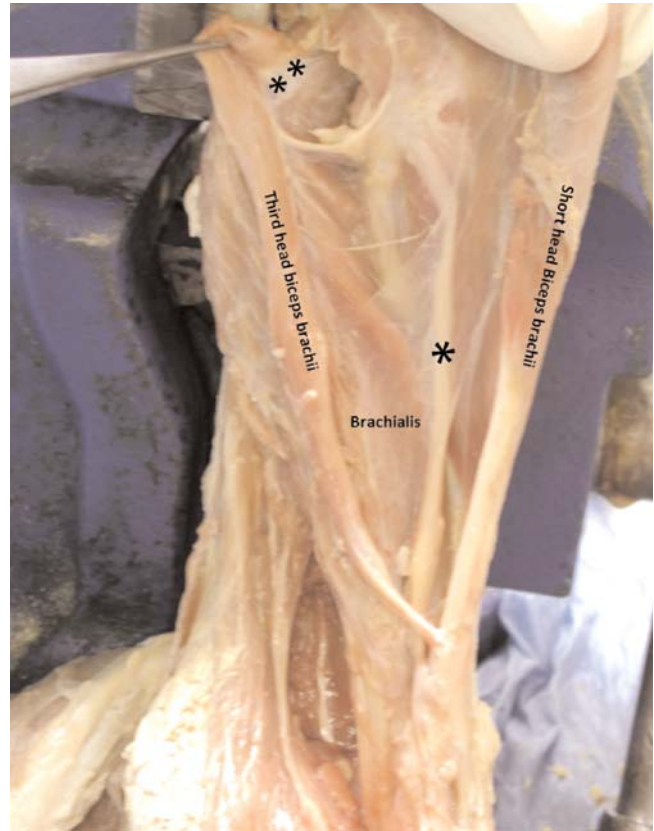

Figure 1. Photograph of cadaver specimen with three heads of the biceps brachii muscle. *Indicates the musculocutaneous nerve, **indicates the origin of the well-developed third head from the deep investing fascia of the brachialis muscle.

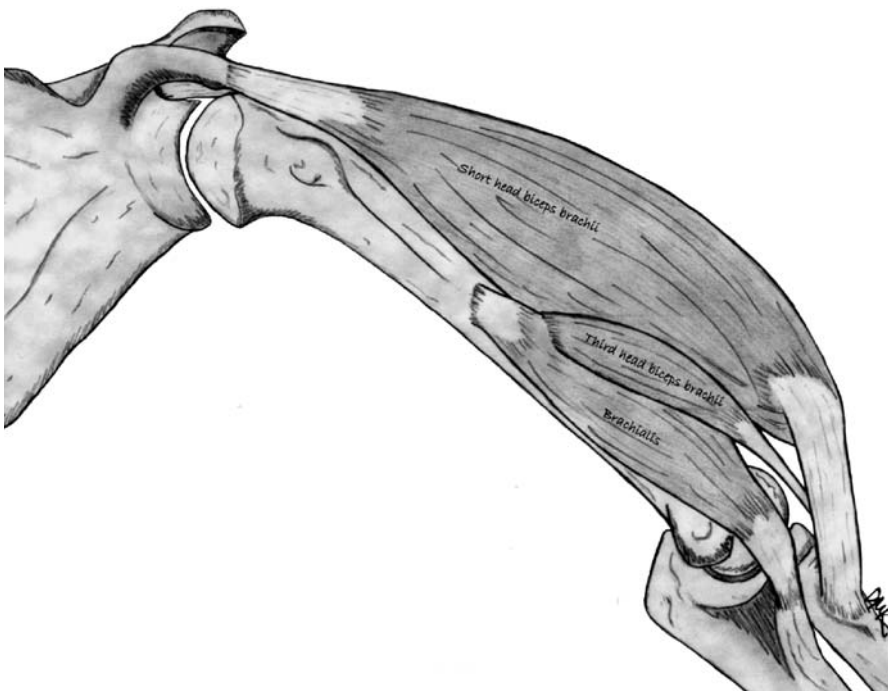


Figure 2. Illustration showing the short head of the biceps brachii muscle retracted to reveal the third head originating from the deep fascia of the brachialis muscle.

Table 2

Rodriguez-Nidenfuhr^[11] classification of supernumerary humeral heads of biceps brachii muscle.

Rodriguez-Nidenfuhr classification of supernumerary humeral heads of biceps brachii		
Classification	Origin	Prevalence
Superior	Humerus between the lesser tubercle and the insertion of the coracobrachialis muscle and origin of the brachialis muscle	5/350 (1.5%)
Infero-medial	Anteromedial humerus, continuous with insertion of the coracobrachialis muscle	31/350 (9%)
Infero-lateral	Lateral intermuscular septum between the insertion of the deltoid muscle and the origin of the brachioradialis muscle	1/350 (0.3%)

head origin into three regions: the shaft of the humerus between coracobrachialis and the brachialis, the intermuscular septum, or from any other region like the shoulder joint capsule or pectoralis major tendon.^[34] Our specimen fits into this system because of their use of the third “catch all” category. They also classified specimens with four or more heads as combinations of their three categories.^[34] Despite its novel origin, the variation seen in our specimen inserted onto the tendon of the short head, which is the second most common insertion according to Kosugi et al.^[34]

Clinical implications

Of course, the kinetic effects of supernumerary heads are somewhat dependent on their point of origin and their size. There are rare reports of accessory heads originating from the scapula,^[33] but in general, they only cross the elbow joint and this may allow for flexion at the elbow regardless of shoulder position as well as contribute to increased forearm supination.^[15,19,28,30,32]

There are also several important clinical implications to bear in mind. These accessory muscle bundles have been reported to cause neurovascular compression or entrapment. This can result in high median nerve entrapment symptoms, thrombosis from brachial artery compression and edema from brachial vein compression.

^[2,15,22,24,30,40] As mentioned above, the musculocutaneous nerve very often has an anomalous course associated with the presence of supernumerary heads of the biceps brachii and this can contribute to nerve entrapment, but is also important for surgeons operating in this region.^[15,27,34] The deltopectoral interval is a common route of entry into the arm and supernumerary heads can cause confusion leading to development of incorrect intervals during this approach, especially when they originate from the pectoralis major.^[4] Additionally, this is usually a unilateral variation which can lead to concern for soft tissue tumors.^[4,24,33] Accessory muscle heads should be able to be differentiated from soft tissue tumors with routine MR imaging.^[26,38] Finally, supernumerary heads can cause unusual displacement of humeral fragments after fracture.^[19]

Conclusion

The variations of the biceps brachii are well documented. However, to our knowledge, an accessory head originating from the investing fascia of the brachialis muscle, like we observed in our specimen, has not been reported. Understanding the varying origins of this muscle is essential for surgeons operating in this region as supernumerary heads can cause confusion intraoperative-

Table 3

Kosugi et al.^[34] classification of supernumerary humeral heads of biceps brachii muscle origin and insertion.

Kosugi et al. classification of supernumerary humeral heads of biceps brachii origin and insertion			
Origin	Prevalence	Insertion	Prevalence
Shaft of humerus between coracobrachialis and brachialis muscles	54.7%	Common belly	74.7%
Intermuscular septum	2.7%	Common tendon	14.7%
Other regions (ie. Tendon of pectoralis major, deltoid, shoulder capsule)	12%	Short head of biceps brachii	16%
Shaft of humerus and intermuscular septum	36%	Long head of biceps brachii	4%
Shaft of humerus and other regions	4%		

ly.^[4,15,22] It is also important for clinicians to be aware of this relatively frequent variation, and that it can be a cause of unusual displacement of humeral bone fragments with fractures, nerve entrapment or can be mistaken for soft tissue tumors.^[2,4,15,19,22,24,27,30,33,40]

Acknowledgements

The authors would like to thank the cadaver donor who made this publication possible.

References

- Bannister L, Dyson M, Warwick R, Williams P. Gray's anatomy. 37th ed. Edinburgh: Churchill Livingstone; 1989.
- Tallapaneni S, Vemavarapu M, Ismail M, Mohammed M, Uddin A, Mariya ST. Inframedial humeral head (Caput Accessorium) of biceps brachii. *History* 2014;7:68–73.
- Tountas CP, Bergman R. Anatomic variations of the upper extremity. New York: Churchill Livingstone; 1993. p. 286.
- Sargon MF, Tuncali D, Celik HH. An unusual origin for the accessory head of biceps brachii muscle. *Clin Anat* 1996;9:160–2.
- Brasseur JL. The biceps tendons: from the top and from the bottom. *J Ultrasound* 2012;15:29–38.
- Bergman R, Thompson S, Afifi A. Catalogue of human variations. Munich: Urban and Schwarzenberg; 1984.
- Kervancioglu P, Orhan M. An anatomical study on the three-headed biceps brachii in human fetuses, and clinical relevance. *Folia Morphol (Warsz)* 2011;70:116–20.
- Le Double A. Traite des variations due systeme musculaire de homme et de leur signification au point de vue de anthropologie zoologique. Paris: Schichicher Freres; 1897.
- Greig H, Anson B, Budinger J. Variations in the form and attachments of the biceps brachii muscle. *Quarterly Bulletin Northwestern University (Evanston, Ill) Medical School* 1951;26:241–4.
- Higashi N, Sone C. A case of brachial biceps with bilaterally abnormal bundles of origin and insertion. *Okaj Folia Anat Jpn* 1987;64:147–55.
- Rodriguez-Niedenfuhr M, Vazquez T, Choi D, Parkin I, Sanudo JR. Supernumerary humeral heads of the biceps brachii muscle revisited. *Clin Anat* 2003;16:197–203.
- Abu-Hijleh MF. Three-headed biceps brachii muscle associated with duplicated musculocutaneous nerve. *Clin Anat* 2005;18:376–9.
- Cerda A. Third head of biceps brachii muscle, associated with musculocutaneous and median nerve bilateral communication and with a communicating branch between median nerve roots. *Int J Morphol* 2014;32:510–4.
- Cucca YY, McLay SV, Okamoto T, Ecker J, McMenamin PG. The biceps brachii muscle and its distal insertion: observations of surgical and evolutionary relevance. *Surg Radiol Anat* 2010;32: 371–5.
- Lee SE, Jung C, Ahn KY, Nam KI. Bilateral asymmetric supernumerary heads of biceps brachii. *Anat Cell Biol* 2011;44:238–40.
- Mas N, Pelin C, Zagyapan R, Bahar H. Una rara relación del nervio mediano con la cabeza accesoria del músculo bíceps braquial: Reporte de caso. *Int J Morphol* 2006;24:561–4.
- Nakatani T, Tanaka S, Mizukami S. Bilateral four-headed biceps brachii muscles: the median nerve and brachial artery passing through a tunnel formed by a muscle slip from the accessory head. *Clin Anat* 1998;11:209–12.
- Poudel PP, Bhattarai C. Study on the supernumerary heads of biceps brachii muscle in Nepalese. *Nepal Med Coll J* 2009;11: 96–8.
- Swieter MG, Carmichael SW. Bilateral three-headed biceps brachii muscles. *Anat Anz* 1980;148:346–9.
- Vazquez T, Rodriguez-Niedenfuhr M, Parkin I, Sanudo JR. A rare case of a four-headed biceps brachii muscle with a double piercing by the musculocutaneous nerve. *Surg Radiol Anat* 2003;25:462–4.
- Abuel-Makarem SM, Ibrahim AF, Darwish HH. Absence of musculocutaneous nerve associated with a third head of biceps brachii muscle and entrapment of ulnar nerve. *Neurosciences (Riyadh)* 2007;12:340–2.
- Kumar H, Das S, Rath G. An anatomical insight into the third head of biceps brachii muscle. *Bratisl Lek Listy* 2008;109:76–8.
- Nayak SR, Krishnamurthy A. An unusual supernumerary head of biceps brachii muscle. *Clin Anat* 2008;21:788–9.
- Nayak SR, Krishnamurthy A, Prabhu LV, Jiji PJ, Ramanathan L, Kumar S. Multiple supernumerary muscles of the arm and its clinical significance. *Bratisl Lek Listy* 2008;109:74–5.
- Nayak SR, Prabhu LV, Sivanandan R. Third head of biceps brachii: a rare occurrence in the Indian population. *Ann Anat* 2006;188:159–61.
- Ozan H, Atasever A, Sinav A, Simsek C, Basar R. An unusual insertion of accessory biceps brachii muscle. *Kaibogaku Zasshi* 1997;72:515–9.
- Rai R, Ranade AV, Prabhu LV, Pai MM, Prakash. Third head of biceps brachii in an Indian population. *Singapore Med J* 2007;48: 929–31.
- Singla RK, Gupta R, Sachdeva K. Multiple musculovascular anomalies in the superior extremities of a cadaver: a case report. *J Clin Diagn Res* 2013;7:342–6.
- Warner JJ, Paletta GA, Warren RF. Accessory head of the biceps brachii. Case report demonstrating clinical relevance. *Clin Orthop Relat Res* 1992:179–81.
- Kopuz C, Sancak B, Ozbenli S. On the incidence of third head of biceps brachii in Turkish neonates and adults. *Kaibogaku Zasshi* 1999;74:301–5.
- Rodriguez-Vazquez JF, Merida-Velasco JR, Jimenez-Collado J. Unusual variation of a third head of the biceps brachii muscle. *Ann Anat* 1999;181:573–5.
- Asvat R, Candler P, Sarmiento E. High incidence of the third head of biceps brachii in South African populations. *J Anat* 1993;182: 101.
- Nasr AY, Hussein AM. Morphology and clinical implication of the extra-head of biceps brachii muscle. *Folia Morphol (Warsz)* 2013;72:349–56.
- Kosugi K, Shibata S, Yamashita H. Supernumerary head of biceps brachii and branching pattern of the musculocutaneous nerve in Japanese. *Surg Radiol Anat* 1992;14:175–85.
- Ozturk NC, Uzmansel D, Ozturk H. An unreported pattern of musculocutaneous and median nerve communication with multiple variations of biceps brachii: a case report. *Surg Radiol Anat* 2010;32:887–90.

36. Ongeti K, Pulei A, Ogeng'o J, Saidi H. Unusual formation of the median nerve associated with the third head of biceps brachii. *Clin Anat* 2012;25:961–2.
37. Lee JH. Reply: unusual formation of the median nerve associated with the third head of biceps brachii. *Clin Anat* 2013;26:920.
38. Ekstrom JE, Shuman WP, Mack LA. MR imaging of accessory soleus muscle. *J Comput Assist Tomogr* 1990;14:239–42.
39. Sonntag CF, editor. *On the anatomy, physiology, and pathology of the orang^outan*. Proceedings of the Zoological Society of London; 1924.
40. Paraskevas G, Natsis K, Ioannidis O, Papaziogas B, Kitsoulis P, Spanidou S. Accessory muscles in the lower part of the anterior compartment of the arm that may entrap neurovascular elements. *Clin Anat* 2008;21:246–51.

Online available at:
www.anatomy.org.tr
doi:10.2399/ana.15.008
QR code:



deomed®

Correspondence to: Srinath Kamineni, MD
University of Kentucky, 740 South Limestone Street,
Kentucky Clinic, K412, Lexington KY, 40536, USA
Phone: +1 859 218 3057
e-mail: srinathkamineni@gmail.com

Conflict of interest statement: No conflicts declared.

This is an open access article distributed under the terms of the Creative Commons Attribution-NonCommercial-NoDerivs 3.0 Unported (CC BY-NC-ND3.0) Licence (<http://creativecommons.org/licenses/by-nc-nd/3.0/>) which permits unrestricted noncommercial use, distribution, and reproduction in any medium, provided the original work is properly cited. *Please cite this article as:* Reilly D, Kamineni S. Unusual origin of three headed biceps brachii muscle. *Anatomy* 2015;9(2):94–99.