

ORIGINAL ARTICLE

Evaluation of Visual Evoked Potentials in Children with Neurofibromatosis Type 1 and Comparison With Radiological Findings

Nörofibromatozis Tip 1 Tanılı Çocuklarda Desen Görsel Uyarılmış Potansiyellerin Değerlendirilmesi ve Radyolojik Bulgularla Karşılaştırılması

¹Ülkühan Öztoprak , ¹Erhan Aksoy , ²Nesrin Ceylan , ²Ayşe Seçil Ekşioğlu , ¹Deniz Yüksel 

¹Sağlık Bilimleri Üniversitesi, Ankara Dr.Sami Ulus Kadın Doğum Çocuk Sağlığı ve Hastalıkları Eğitim ve Araştırma Hastanesi, Çocuk Nöroloji Bölümü

²Ankara Şehir Hastanesi, Radyoloji Bölümü

Correspondence

Ülkühan Öztoprak, Sağlık Bilimleri Üniversitesi, Ankara Dr.Sami Ulus Kadın Doğum Çocuk Sağlığı ve Hastalıkları Eğitim ve Araştırma Hastanesi, Çocuk Nöroloji Bölümü, 06022, Ankara/ Türkiye.

E-Mail: ulkuhantoprak@yahoo.com

How to cite ?

Öztoprak Ü, Aksoy E, Ceylan N, Ekşioğlu AS, Yüksel D. Evaluation of Visual Evoked Potentials in Children with Neurofibromatosis Type 1 and Comparison With Radiological Findings. Genel TIP Derg. 2022; 32(2): 144-149

ABSTRACT

Purpose: It was aimed to examine the pattern visual evoked potentials (P-VEP) of children with neurofibromatosis type 1 (NF type 1) and to evaluate the correlation of P-VEP results with optical gliomas and unidentified bright objects (UBO) associated with NF Type 1.

Materials and Methods: P-VEP and P100 latencies of 28 children including 16 (%57) boys, who were followed up with the diagnosis of NF Type 1 in the Pediatric Neurology Outpatient Clinic of xxxxxxxxxxxx between 2017 and 2020, with a mean age of 9.61 ± 3.7 years of age were compared with the P100 latencies of a control group consisting of 28 healthy children of similar age and gender.

Results: Unidentified bright objects were found in the brain of 82% of the patients by using magnetic resonance imaging, and optic glioma was found in 21% of the patients. P100 latencies were significantly longer in the patient group than in the control group ($p = 0.013$, $p = 0.043$). Patients with optic glioma were found to have significantly longer P100 latencies than patients without optic glioma, consistent with the anatomical location of the optic glioma ($p = 0.042$, $p = 0.025$).

Conclusion: With this study, it has been shown that the P-VEP test is an objective electrophysiological test that can be used in the functional assessment of visual pathways in children with NF Type 1. We think that the use of the P-VEP test in the clinical follow-up of children with NF Type 1 may be particularly useful in the early detection of optic gliomas.

Keywords: Child, Pattern visual evoked potentials, Neurofibromatosis type 1

ÖZ

Amaç: Nörofibromatozis Tip 1 (NF tip 1)'li çocukların desen görsel uyarılmış (pattern visual evoked potentials; P-VEP) potansiyellerini değerlendirmek ve P-VEP sonuçlarının, optik gliom ve NF Tip 1 ilişkili bilinmeyen parlak objeler (unidentified bright objects; UBO) ile korelasyonunu irdelemek amaçlanmıştır.

Gereç ve Yöntem: 2017-2020 yılları arasında XXXXXXXXXXXXX Çocuk Nöroloji Polikliniği'nde NF Tip 1 tanısı ile takip edilen, yaş ortalaması 9.61 ± 3.7 yaş olan, 16 (%57)'si erkek, 28 çocuk hastanın P-VEP P 100 latans değerleri, yaş ve cinsiyeti benzer 28 sağlıklı çocuktan oluşan kontrol grubunun P100 latansları ile karşılaştırıldı.

Sonuç: Hastaların %82'sinde beyin magnetik rezonans görüntülemeye UBO, %21'inde optik gliom saptandı. Hasta grubunda P100 latansları kontrol grubuna göre anlamlı olarak daha uzun idi ($p=0.013$, $p=0.043$). Optik gliomu olan hastaların P100 latanslarının, optik gliomun anatomik lokalizasyonu ile uyumlu şekilde, optik gliomu olmayan hastalara göre anlamlı olarak daha uzun olduğu görüldü ($p=0.042$, $p=0.025$).

Sonuç: Bu çalışma ile P-VEP testinin NF Tip 1'li çocuklarda görme yollarının fonksiyonel değerlendirilmesinde kullanılabilecek objektif bir elektrofizyolojik test olduğu gösterilmiştir. NF Tip 1'li çocukların klinik takibinde P-VEP testinin kullanılmasının özellikle optik gliomların erken dönem tespitinde yararlı olabileceğini düşünmekteyiz.

Anahtar Kelimeler: Çocuk, Desen görsel uyarılmış potansiyeller, Nörofibromatoz tip 1

Introduction

Neurofibromatosis type 1 (NF-1) is the most common autosomal dominant neurocutaneous disease, the clinical findings of which begin to appear in childhood, involving various systems including the skin, skeletal and nervous system, and affects cell growth, especially in neural tissues (1, 2).

The NF-1 gene is a large gene cloned in the 11p12 region of chromosome 17. This gene encodes a protein called neurofibromin, which functions as a tumor suppressor, and consequently, mutations that occur can cause the development of various

tumoral formations that are more common in neuronal tissues (3). Optic nerve glioma is the most common intracranial tumor in NF-1 patients. These tumors, which are considered to be low-grade astrocytomas, are usually benign and most of them are asymptomatic until advanced age. However, although it is rare, it may grow rapidly and cause progressive vision loss (4, 5).

Magnetic resonance imaging (MRI) in NF-type 1 patient findings increase focal signal intensities that are located in different localizations, most commonly in the basal ganglia and brain stem from early ages

and disappear toward the adolescence period (6). To avoid pathological justification, these hyperintense lesions with clear borders are named as 'NF-1 bright objects (NBO)', 'unidentified bright objects (UBO)'. These lesions are thought to be benign hamartomas or areas of defective myelination that disappear with aging (7,8).

Pattern visual evoked potential test (Pattern VEP) is a sedation-free, non-invasive, objective electrophysiological test obtained by recording the electrical responses developing in photoreceptors from the occipital region as a result of a visual stimulus. It provides a functional evaluation of the visual pathways as a whole, starting from the retinal ganglion cells to the occipital cortex (9). It is used to support the clinical diagnosis of demyelinating white matter diseases, inflammatory or infiltrative diseases of the optic nerve, in conditions such as delays in response or prolongation of latency obtained with the pattern VEP test (10, 11).

Magnetic resonance imaging (MRI) is mostly preferred in the detection and follow-up of hamartomatous lesions and optic gliomas in the brain in neurofibromatosis patients. However, sedation or anesthesia is often required during the MRI procedure for pediatric patients (12). Studies in adults have shown that the P-VEP test can be as sensitive as orbital and brain MRI in detecting anatomical and functional pathology in the visual pathways (10, 13, 14). However, despite being an objective electrophysiological diagnostic tool that is non-invasive and does not require sedation, visual evoked potentials are not widely used in the clinical follow-up of pediatric patients with NF type 1. Therefore, it was aimed to evaluate the P-VEP potentials in children with NF type 1 and to examine whether P-VEP results were correlated with radiologically detected optic glioma and UBOS.

Materials and Methods

The patients who were examined in the XXXXXXXXXX Training and Research Hospital Pediatric Neurology Outpatient Clinic between December 2017 and January 2020, patient files were selected by scanning the codes 'Q85.0 Neurofibromatosis (non-malignant)' and 'L 81.3 Coffee with milk' codes in the electronic database and were reviewed (15). At the time of VEP, patients who were aged between 5 to 18 years and had at least one P-VEP test, had at least one brain and/or orbital MRI, and had a maximum of 6 months between VEP test and brain and/or orbital MRI were included in the study. The ages of the patients included in the study at the time of the VEP test, examination findings meeting the NF-diagnostic criteria, accompanying clinical findings, neurological examination results, brain and/or orbital MRI results were recorded.

Other than NF-1 related symptoms, such as periventricular leukomalacia, stroke, cystic encephalomalacia, hypoxia sequel lesion findings,

who do not meet the diagnostic criteria for NF, have cognitive retardation at a level that prevents cooperation in VEP test, the patients whom the time between brain MRI/orbital MRI and VEP test were longer than 6 months, and patients who were younger than 5 years of age were not included in the study because cooperation was required for the P-VEP test. In order to avoid temporal variation of NF-1-related hyperintense lesions, the time between the VEP test and radiological examination was determined to be a maximum of 6 months. The P100 latencies of the patients obtained from the P-VEP test were compared with the control group. Control group was selected among the children admitted to the pediatric neurology outpatient clinic with complaints of blurred vision, macropsia/micropsia, and double vision, whose neurological and ophthalmology examinations were normal and no pathological findings were detected in brain MRI, P-VEP test, and the results were evaluated as normal according to the reference values of our laboratory. Our laboratory's P-VEP test reference P100 latency values were 110 ± 5 ms (11.4-118.8 ms).

P-VEP latencies were recorded with Nihon Kohden® (D-61191 Rosbach, Germany) device. Since the patient had to cooperate with the test during the shooting, no sedative drug was used. For P-VEP recording, the active electrode was attached 2 cm above the protuberantia occipitalis externa in the occipital bone, the reference electrode was attached to the vertex and the ground electrode was attached to the scalp border on the forehead using a paste. In the dim room light, while the patient looks at the fixation point in the middle of the chessboard-shaped patterns on the screen 1 m in front of him with equal numbers of black and white stones, where black squares turn white and whites turn black 1-2 times per second, electrical visual potentials emerging in the occipital cortex were observed. It was recorded by means of electrodes placed in the region. The patient was followed closely by an experienced electrophysiology technician, who looked at the fixation point. After removing artifacts in each measurement, a P-VEP pattern was created by averaging about 200 stimuli (Figure 1). Functional evaluation of the visual pathways was performed by calculating the latency value of the P100 wave, which is the first large positive wave in the P-VEP pattern. The latency of the P100 wave was measured separately from both eyes of the patient and control groups.

MRI of patients was obtained by using Magnetom Essenza 1.5 Tesla with Siemens AG, Germany® device and the standard protocol was applied; T1-weighted spin-echo axial images, turbo-spin-echo T2-weighted axial and coronal images, and fast fluid-attenuated inversion recovery (FLAIR)-weighted images were taken. In addition, SWI and DWI sequences were added to these sequences. Gadolinium-based contrast agent was given at a dose of 0.2 ml/kg. MR images recorded in the PACS system were re-evaluated by a pediatric radiologist experienced in pediatric neuroradiology. The research was approved by the University of Health

Sciences, xxxxxxxxxxxx Clinical Research Ethics Committee (Approval no: E-21/10-217).

The data of the study were evaluated using the Statistical Package for Social Sciences (SPSS, Inc., Chicago, IL, v21) program. The distribution of quantitative variables was performed using the Kolmogorov-Smirnov test. The groups were compared with the independent samples t-test for quantitative variables with normal distribution. Descriptive statistics were given as mean \pm standard deviation. Groups were compared for non-normally distributed variables using Kruskal-Wallis and descriptive statistics were given as median and range of distribution. Categorical data were analyzed using the 'chi-square' or 'Pearson chi-square' test. $P < 0.05$ was considered statistically significant.

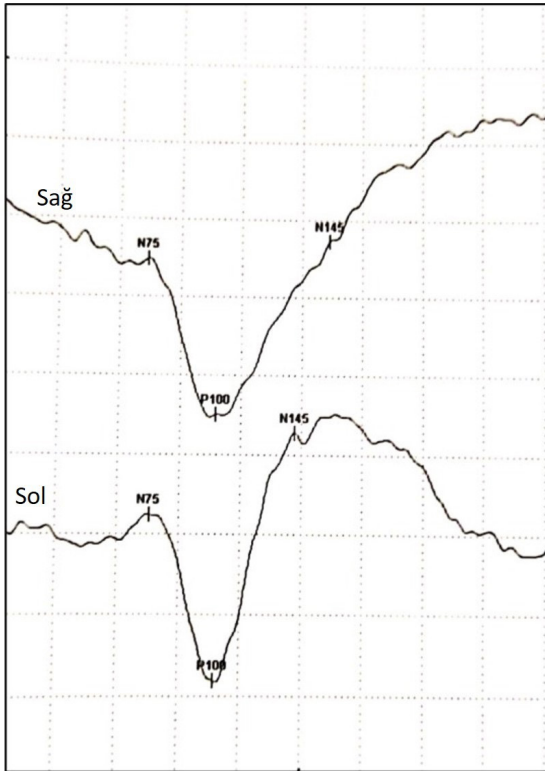


Figure 1

Results

A total of 28 pediatric patients, 16 (57%) of whom were male, and had a mean age of 9.61 ± 3.7 years, followed up in our center with a diagnosis of NF1 and meeting the inclusion criteria were included in the study. The mean age of the control group was 10.57 ± 2.34 years and 12 (43%) of them were male. There was no difference between the patient and control groups in terms of mean age distribution and gender. The gender and mean age distribution of the patient and control groups as well as the clinical characteristics of patients with NF type 1 are given in Table 1. Macrocephaly in 8 patients (28.6%), short stature in 3 patients (10.7%),

epilepsy in 3 patients (10.7%), headache in 5 patients (17.9%), mild cognitive retardation in 8 patients (28.5%) and specific learning disability in 1 patient (3.6%) were recorded. Cranial magnetic resonance imaging (MRI) was performed in all patients, and orbital MRI with contrast fat suppression in the coronal and transverse plane was performed in 19 patients (67.8%). Cranial MRI examination was normal in 5 (18%) patients, while UBO was present in 23 (82%) patients. UBOs were most commonly located in the unilateral and/or bilateral thalamus, globus pallidus, and brainstem (Figure 2). Optic nerve glioma was detected in 21% (n=6) of the patients; in 3 of them, glioma was located on the right, in 2 it was located on the left, and 1 bilateral optic nerve localization was observed (Figure 1). The median age at diagnosis of patients with optic glioma was 5.5 years (5-13 years). In the ophthalmological examination, the evaluation of 4 patients was normal, while bilateral visual acuity was decreased in 2 patients. The neuroradiological findings of the patients and the distribution of UBOs are given in Table 2.

Tablo 1. Hasta ve kontrol grubunun cinsiyet ve yaş ortalaması dağılımı ve hastaların klinik özellikleri

| | Hasta Grubu n (%) | Kontrol Grubu n (%) | p |
|---|----------------------|------------------------|-------|
| Cinsiyet | | | |
| Erkek | 16 (57) | 12 (43) | 0,285 |
| Kız | 12 (43) | 16 (57) | |
| Yaş(ortalama\pmSD) | 9,61 \pm 3,7 | 10,57 \pm 2,34 | 0,256 |
| Pozitif Tanı Kriterleri | | | |
| Sütlü kahve lekeleri | 28 (100) | | |
| Aksiller ve/veya inguinal çillenme | 23 (82) | | |
| İki nörofibrom veya bir pleksiform nörofibrom | 7 (25) | | |
| Lisch nodülü | 23 (82) | | |
| Optik gliom | 6 (21,4) | | |
| NF-1 tanılı 1.derece akraba | 12 (42,9) | | |
| Pozitif tanı kriteri sayısı | | | |
| 2 | 6 (21,4) | | |
| 3 | 12 (42,9) | | |
| ≥ 4 | 10 (35,7) | | |
| SD;standart deviasyon | | | |

Tablo 2. Hastaların nöroradyolojik bulguları ve UBO'ların yerleşim dağılımları

| UBO'ların Yerleşimi | n (%) |
|---------------------|-----------|
| Globus Pallidus | 15 (53,5) |
| Talamus | 12 (42,8) |
| Korpus Kallozum | 1 (3,5) |
| Hipokampus | 1 (3,5) |

| | |
|---|-----------|
| İnternal kapsül | 6 (21,4) |
| Serebral beyaz cevher | 1 (3,5) |
| Beyin sapı (pons, mezensefalon, bulbus) | 14 (50) |
| Dentat Nükleus | 10 (35,7) |
| Serebellar beyaz cevher | 12 (42,8) |
| Optik Gliom | 6 (21,4) |
| Sağ optik sinir | 3 |
| Sol optik sinir | 2 |
| Bilateral tutulum | 1 |
| Beyin MRG normal | 5 (17,9) |
| UBO: unidentified bright objects | |

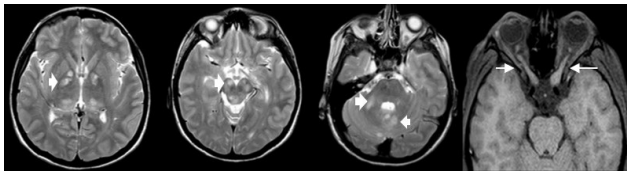
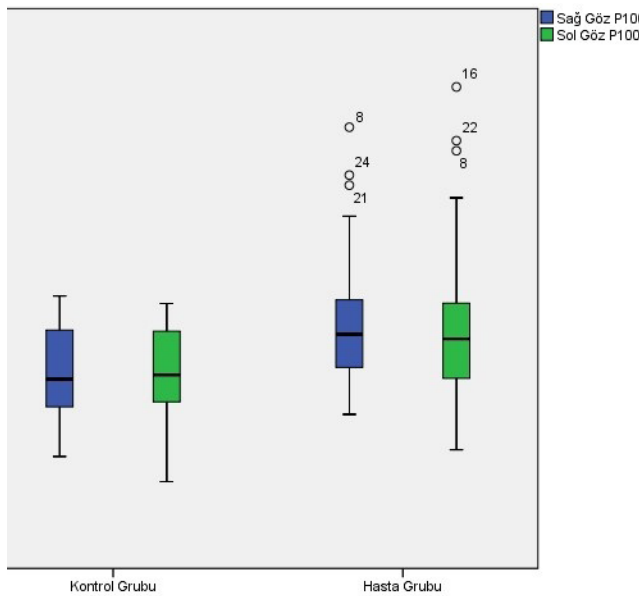
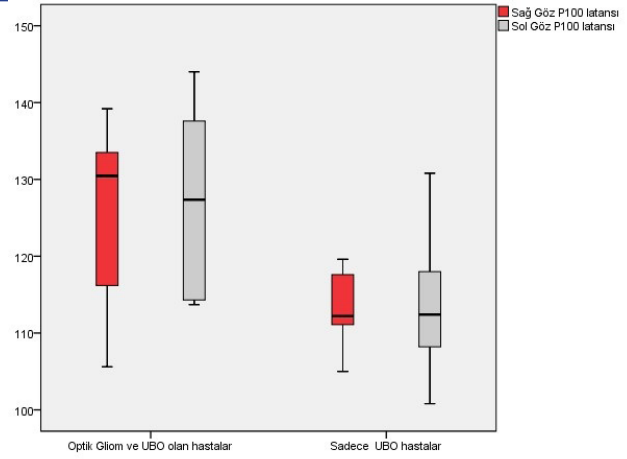


Figure 2:

In the patient group, the mean P100 latency value obtained from the right eye was 115.9 ± 8.5 msec, and the mean P100 latency value obtained from the left eye was 115.8 ± 10.7 msec. The mean P100 latency from the right eye was 110.3 ± 5.4 msec, and the mean P100 latency from the left eye was 110 ± 5.5 msec. The P100 latencies obtained from the right and left eyes in the patient group were significantly longer than in the control group ($p=0.013$, $p=0.043$, Graph 1).



Graph 1



Grafik 2. NF tip1 hasta grubunda P100 latanslarının nöroradyolojik bulgulara göre karşılaştırılması
UBO:unidentified bright objects

Graph 2

It was evaluated whether visual evoked potentials differed according to neuroradiological findings in the patient group with NF Type 1. The mean P100 latency value obtained from the right eye of the patients with optic glioma in orbital MRI was 125.9 ± 12.5 msec, and the mean P100 latency value obtained from the left eye was 127.3 ± 13.4 msec. The mean P100 latency obtained from the right eye was 113.6 ± 4.5 ms, and the mean P100 latency obtained from the left eye was 113.7 ± 7.9 msec in patients that radiologically showed only UBO with no optic glioma. It was observed that the P100 latencies obtained from the right and left eyes of the patients with optic glioma were significantly longer than the patients without optic glioma ($p=0.042$, $p=0.025$, Figure 3).

Discussion

In this study conducted with 28 pediatric patients with NF Type 1, it was found that the P100 latencies of patients with UBO and optic glioma detected in brain MRI were significantly prolonged in the P-VEP test compared to healthy controls. Yerdelen et al. (16) showed that visual evoked potentials were abnormal in 51.3% of the patients in their study group consisting of 13 adolescent and adult patients with NF Type 1 Iannaccone et al. (17) evaluated 16 pediatric patients with NF Type 1 who did not have optic glioma and had only UBO on brain MRI, and found that 18.8% of the patients had abnormal P-VEP results and VEP latencies were more elongated in children with NF Type 1 than healthy children.

In 43% to 93% of pediatric NF type 1 patients, UBO is detected in brain MRI, and these were mostly located in the basal ganglia, mostly in the thalamus, cerebellum, brain stem, and subcortical white matter (18-21). In 82% of our patients, UBOs with locations and frequencies to those previously described were detected. Similar these hyperintense lesions, the pathophysiology of which is not clearly elucidated, are thought to reflect increased fluid in the myelin that is associated with defective myelination areas, hamortomas or dysplastic glial proliferation (6, 22). In addition, it has been shown that the Ras pathway in

Schwann cells is also affected in NF type 1 and that the decrease in neurofibromin activity slows down the myelination process secondarily (23). Therefore, the prolonged visual evoked potentials that we detected in children with NF type 1 in our study may be the electrophysiological reflection of a partial myelination defect that may exist at the microscopic level in the visual pathways.

Optic glioma develops in 5-25% of patients with NF Type 1, and it is more common, especially in young children (24). Optic gliomas may arise in the intraorbital portion of the optic nerves, chiasm, and/or intracerebral visual pathways. Common symptoms of optic gliomas include decreased visual acuity, visual impairment, visual field defects, proptosis, and strabismus. Since the presence of optic glioma may be unrelated to the presence or absence of other clinical manifestations of NF1, clinical suspicion should arise from tumor-related symptoms (25). There are different opinions on what should be the most effective examination method for the screening and detection of optic gliomas, especially in young children with NF type 1. Although the annual ophthalmologic examination is recommended as one of the most effective methods for screening optic gliomas, visual acuity and visual field examination in young children is often difficult and may not provide objective information. In addition, the majority of optic gliomas are usually asymptomatic before the age of 10, and therefore, young children at risk may not be recognized in the early period by only ophthalmologic examination (26).

Magnetic resonances are still the most sensitive test for the detection of optic gliomas. However, because of the cost and the need for sedation or general anesthesia, it is not recommended to use in asymptomatic children (27). In addition, the radiological appearance of the tumor may not fully reflect its biological activity (28). For this reason, studies have been conducted on the usability of non-invasive, sedation-free P-VEP testing that can predict the presence or monitor the progression of optic gliomas in children with NF type 1. In studies, the sensitivity of visual evoked potentials to detect optic gliomas varies between 86-100%, and the specificity ranges between 55-75% (12, 25, 29-31). Wolsey et al. (12) obtained abnormal P-VEP results in 85.7% of 30 patients with NF type 1, 14 of whom had optic glioma. Ammendola et al. (32) conducted a study on the use of multimodal evoked potentials, including the P-VEP test, in NF type 1 patients and found prolonged P100 latency in 10 of 21 children. Similarly, in a recent study, P-VEP P100 latency was found to be significantly longer in children with NF Type 1 with optic glioma compared to those without optic glioma (33). However, there are a small number of studies that do not support these views. In a study by Rossi et al. (30), no correlation was found between optic glioma and P-VEP results. In their study, in which they evaluated 25 asymptomatic patients, they found no abnormality in P-VEP results in any of the 6 patients with optic glioma. Similarly, Listerick et

al. (34) stated that the VEP test is not an appropriate screening tool for the detection of optic glioma in children with NF type 1. In our study, optic glioma was detected in 21% of the patients. While only 2 patients with optic glioma had decreased visual acuity on ophthalmologic examination, and all of these patients had a significantly prolonged visual evoked potential latency when compared with both patients with only UBO on MRI and healthy children, coinciding with the anatomical localization of optic glioma detected.

Limitations of this study are its retrospective design and small sample size.

Conclusion

This study showed that the P-VEP test is an objective electrophysiological test that can be used in the functional evaluation of visual pathways in children with NF type 1 with optic glioma. Therefore, we think that the use of the P-VEP test in the clinical follow-up of children with NF type 1 may be useful in the early detection of optic gliomas, which are not yet evident on the anatomical background and therefore cannot be detected on magnetic resonance imaging.

References

1. Dunning-Davies BM, Parker AP. Annual review of children with neurofibromatosis type 1. *Arch Dis Child Educ Pract Ed* 2016 ;101:102-11.
2. Ferner RE, Huson SM, Thomas N, et al. Guidelines for the diagnosis and management of individuals with neurofibromatosis 1. *J Med Genet* 2007;44:81-8.
3. Abramowicz A, Gos M. Neurofibromin in neurofibromatosis type 1-mutations in NF1 gene as a cause of disease. *Dev Period Med* 2014;18:297-306.
4. Lewis RA, Gerson LP, Axelson KA, et al. Von Recklinghausen neurofibromatosis: II. Incidence of optic gliomata. *Ophthalmology* 1984;91:929-35.
5. Rasool N, Odel JG, Kazim M. Optic pathway glioma of childhood. *Curr Opin Ophthalmol* 2017;28:289-95.
6. DiPaolo DP, Zimmerman RA, Rorke LB, et al. Neurofibromatosis type 1: pathologic substrate of high-signal-intensity foci in the brain. *Radiology* 1995;195:721-4.
7. Szudek J, Friedman J. Unidentified bright objects associated with features of neurofibromatosis 1. *Pediatr Neurol* 2002;27:123-7.
8. Jacques C, Dietemann J. Imagerie de la neurofibromatose de type 1. *J Neuroradiol* 2005;32:180-97.
9. Sherman J. Visual evoked potential (VEP): Basic concepts and clinical applications. *J Am Optom Assoc* 1979;50:19-30
10. Jeon J, Oh S, Kyung S. Assessment of visual disability using visual evoked potentials. *BMC Ophthalmol* 2012;12:36.
11. Stark D. Clinical uses of the visually evoked potential. *Aust J Ophthalmol* 1980;8:211.
12. Wolsey DH, Larson SA, Creel D, et al. Can screening for optic nerve gliomas in patients with neurofibromatosis type I be performed with visual-evoked potential testing? *J AAPOS* 2006;10:307-11.
13. Davies M, Williams R, Haq N, et al. MRI of optic nerve and postchiasmal visual pathways and visual evoked potentials in secondary progressive multiple sclerosis. *Neuroradiology* 1998;40:765-70.

14. Al-Ejailat SM, Senior MVA-M. The role of Magnetic Resonance Imaging and Visual Evoked Potential in management of optic neuritis. *Pan Afr Med J* 2014;17:54.
15. Neurofibromatosis N. Conference statement. National Institutes of Health consensus development conference. *Arch Neurol* 1988; 45:575-8.
16. Yerdelen D, Koc F, Durdu M, et al. Electrophysiological findings in neurofibromatosis type 1. *J Neurol Sci* 2011;306:42-8.
17. Iannaccone A, McCluney RA, Brewer VR, et al. Visual evoked potentials in children with neurofibromatosis type 1. *Doc Ophthalmol* 2002;105:63-81.
18. Aoki S, Barkovich A, Nishimura K, et al. Neurofibromatosis types 1 and 2: cranial MR findings. *Radiology* 1989;172:527-34.
19. DeBella K, Poskitt K, Szudek J, et al. Use of "unidentified bright objects" on MRI for diagnosis of neurofibromatosis 1 in children. *Neurology* 2000;54:1646-51.
20. Duffner PK, Cohen ME, Seidel FG, et al. The significance of MRI abnormalities in children with neurofibromatosis. *Neurology*. 1989;39:373-8.
21. Ferraz Filho JRL, Munis MP, Souza AS, et al. Unidentified bright objects on brain MRI in children as a diagnostic criterion for neurofibromatosis type 1. *Pediatr Radiol* 2008;38:305-10.
22. Menor F, Marti-Bonmati L, Arana E, et al. Neurofibromatosis type 1 in children: MR imaging and follow-up studies of central nervous system findings. *Eur J Radiol* 1998;26:121-31.
23. Rosenbaum T, Kim HA, Boissy YL, et al. Neurofibromin, the neurofibromatosis type 1 Ras-GAP, is required for appropriate P0 expression and myelination. *Ann N Y Acad Sci* 1999;883:203-14.
24. Van Mierlo C, Spileers W, Legius E, et al. Role of visual evoked potentials in the assessment and management of optic pathway gliomas in children. *Doc Ophthalmol* 2013;127:177-90.
25. North K, Cochineas C, Tang E, et al. Optic gliomas in neurofibromatosis type 1: role of visual evoked potentials. *Pediatr Neurol* 1994;10:117-23.
26. Avery RA, Ferner RE, Listernick R, et al. Visual acuity in children with low grade gliomas of the visual pathway: implications for patient care and clinical research. *J Neurooncol* 2012;110:1-7.
27. Listernick R, Louis DN, Packer RJ, et al. Optic pathway gliomas in children with neurofibromatosis 1: consensus statement from the NF1 Optic Pathway Glioma Task Force. *Ann Neurol* 1997;41:143-9.
28. Dunn DW, PURVIN V. Optic pathway gliomas in neurofibromatosis. *Dev Med Child Neurol* 1990;32:820-4.
29. Jabbari B, Maitland CG, Morris LM, et al. The value of visual evoked potential as a screening test in neurofibromatosis. *Arch Neurol* 1985;42:1072-4.
30. Rossi L, Pastorino G, Scotti G, et al. Early diagnosis of optic glioma in children with neurofibromatosis type 1. *Childs Nerv Syst* 1994;10:426-9.
31. Kelly JP, Leary S, Khanna P, et al. Longitudinal measures of visual function, tumor volume, and prediction of visual outcomes after treatment of optic pathway gliomas. *Ophthalmology* 2012;119:1231-7.
32. Ammendola A, Ciccone G, Ammendola E. Utility of multimodal evoked potentials study in neurofibromatosis type 1 of childhood. *Pediatr Neurol* 2006;34:276-80.
33. Vagge A, Camicione P, Pellegrini M, et al. Role of visual evoked potentials and optical coherence tomography in the screening for optic pathway gliomas in patients with neurofibromatosis type I. *Eur J Ophthalmol* 2021;31:689-703.
34. Listernick R, Ferner RE, Liu GT, et al. Optic pathway gliomas in neurofibromatosis 1: controversies and recommendations. *Ann Neurol* 2007;61:189-98.